

18th Meeting of the
International Association of Dental Traumatology

Istanbul, Turkey

June 19-21, 2014



International Association of Dental Traumatology

4425 Cass Street, Suite A

San Diego, CA 92109

Tel: 1 (858) 272-1018 Fax: 1 (858) 272-7687

Email: iadt@iadt-dentaltrauma.org

Web Site: www.iadt-dentaltrauma.org

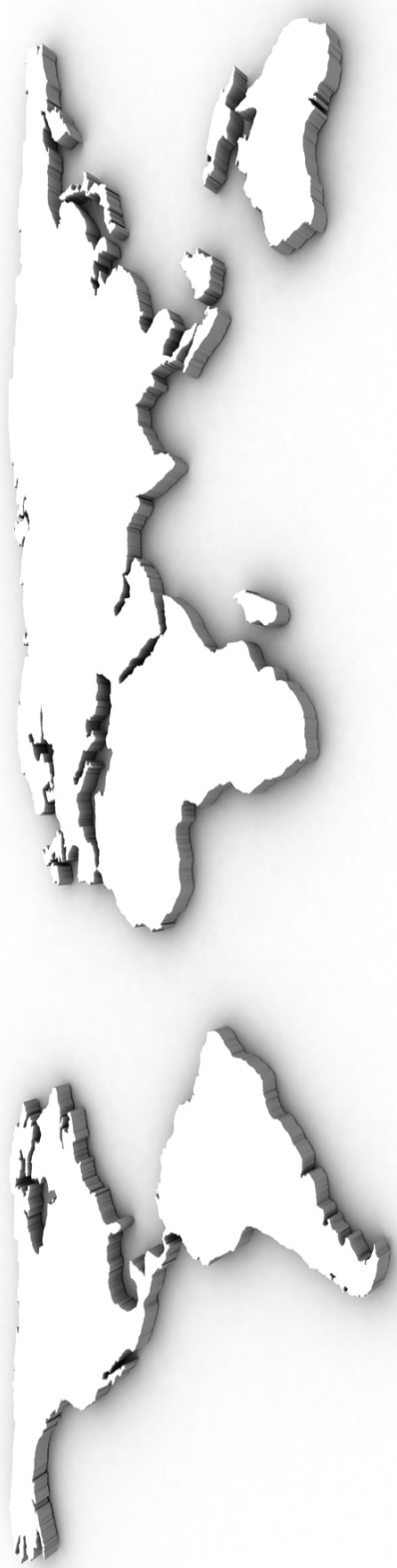

Table of Contents

	Page
Supporting Organizations	3
Welcome Letter	4
Sponsors / Exhibitors	5
Officers / Directors / Committees	6
Military Museum Map	7
Conference Overview	8
Social Events, Elective Tours and Activities	9-12
Program Moderators	13
Program Schedule	14-15
Research Lecture Presentations	16-19
Invited Speakers	20-28
Abstracts	29-160
Ednodontics & Periodontal Aspects	
Case Posters	29-65
Research Posters.....	66-74
Epidemiology Social Aspects Education Diagnostics	
Case Posters	75-76
Research Posters.....	77-82
Esthetics Prosthetics Restorative	
Case Posters	83-95
Oral & Maxillofacial Surgery / Transplant / Implant	
Case Posters	96-104
Research Posters.....	105-107
Pediatrics & Orthodontics	
Case Posters	108-154
Research Posters	155-159
Prevention & Sports Dentistry	
Case Posters	160
Research Lecture Presentation Abstracts	161-205
Session 1- Award Nominees.....	161-163
Session 2- Award Nominees.....	164-167
Session 3	168-170
Session 4	171-174
Session 5	175-178
Session 6	179-181
Session 7	182-185
Session 8	186-190
Session 9	191-194
Session 10	195-197
Session 11.....	198-200
Session 12.....	201-205

Conference Supporting Organizations

Dentist Chamber of Ankara (ADO)	Turkish Orthodontic Society
Turkish Dental Association	Turkish Endodontic Society
Turkish Pedodontics Society	Oral and Maxillofacial Surgery Society
Turkish Pedodontics Society Ankara Branch	Society of Restorative Dentistry
Turkish Pedodontics Society Izmir Branch	

Istanbul Local Organizing Committee

Pediatric Dentistry

Prof. Dr. Nil Altay (Hacettepe University)
Prof. Dr. Alev Alacam (Gazi University)
Prof. Dr. Koray Gencay (Istanbul University)
Prof. Dr. Figen Seymen (Istanbul University)
Prof. Dr. Ece Eden (Ege University)
Prof. Dr. Zafer C. Cehreli (Hacettepe University)
Assoc. Prof. Dr. Yucel Yilmaz (Ataturk Univeristy)
Assoc. Prof. Dr. Cem Gungor (Hacettepe University)

Maxillofacial Radiology

Prof. Dr. Kaan Orhan (Ankara University)
Assoc. Prof. Dr. Serdar Uysal (Hacettepe University)

Endodontics

Prof. Dr. Kemal Caliskan (Ege University)
Prof. Dr. Bahar Ozcelik (Ankara University)

Oral Surgery

Prof. Dr. Sina Uckan (Baskent University)
Prof. Dr. Reha Kisnisci (Ankara University)

Orthodontics

Assoc. Prof. Mehmet Ozgen (Private Practice)

Periodontology

Prof. Dr. Rahime Nohutcu (Hacettepe University)

Restorative Dentistry

Prof. Dr. Arlin Kiremitci (Hacettepe University)

Prosthodontics

Assoc. Prof. Dr. Atilla Ertan (Hacettepe University)

*The IADT wishes to thank our Organizations for their continued support and contributions to the art and science of Dental Traumatology around the world.
We encourage our delegates to visit their respective web site for meeting announcements and news.*

2014 Scientific Program Chair Welcome Letter

The only predictable thing with dental accidents is that they will happen. Indeed, roughly one-half of the world's population will suffer dental trauma of some kind during their lifetime. The many possible combinations of injuries make diagnosis and treatment complex and difficult. Successful healing outcomes are intimately linked to the emergency treatment, to correctly evaluating clinical factors, and to making the right treatment decisions.

IADT is a professional organization whose mission is to promote optimal prevention and treatment service in the field of traumatic dental injuries through the interaction with dental and medical colleagues, the public and interested parties in education, sports, industry and appropriate governmental agencies.

The treatment of dental trauma is multidisciplinary and involves almost all specialists and general dentists, either in the emergency phase or later as patients in their daily practices. IADT World Congresses are unique forums where the whole multi-disciplinary fields of dentistry meet to discuss the management of dental injuries. Clinicians, researchers, educators, sports dentists and others will attend this important meeting. This is a golden opportunity for interaction and learning experience.

Welcome to Istanbul June 2014.

Sincerely,



Program Co-Chair
Dr. Lars Andersson, DDS, PhD, DrOdont
Professor and Chair, Dept of Surgical Sciences
Faculty of Dentistry, HSC
Kuwait University
Safat Kuwait



Program Co-Chair
Prof. Dr. Ayse Nil Altay, DDS, PhD
Pediatric Dentist
Turkey

**Save The Date:
19th Meeting of the
International Association of Dental Traumatology
Brisbane, Australia
August 11th-14th, 2016**

Sponsors

WILEY

WILEY

111 River Street
Hoboken, NJ 07030-5774 USA
Tel: 1 201 748 6000
Fax: 1 201 748 6088
Email: info@wiley.com
Website: www.wiley.com



Paşa Dental

Millet Cad. Karagül İş Merkezi
No:84-102
34270 Fındıkzade / İSTANBUL
Tel: +90 212 531 29 71
Fax: +90 212 531 00 33
Email: info@pasadental.com.tr
Website: www.pasadental.com.tr



Silonite

15 High Street
Glen Iris, VIC, 3146
Tel: 1300 680 952
Email: info@silonite.com.au
Website: www.silonite.com.au

Exhibitors



Ivoclar Vivadent Inc.

175 Pineview Drive
Amherst, NY 14228 USA
Tel: 1 800 533 6825
Fax: 1 716 691 2285
Website: www.ivoclarvivadent.com



J. Morita Europe GmbH

Justus-von-Liebig-Str. 27a
63128 Dietzenbach Germany
Tel: +49. 6074. 836 0
Fax: +49. 6074. 836 299
Email: info@morita.de
Website: www.morita.com/europe



Paşa Dental

Millet Cad. Karagül İş Merkezi
No:84-102
34270 Fındıkzade / İSTANBUL
Tel: +90 212 531 29 71
Fax: +90 212 531 00 33
Email: info@pasadental.com.tr
Website: www.pasadental.com.tr



Silonite

15 High Street
Glen Iris, VIC, 3146
Tel: 1300 680 952
Email: info@silonite.com.au
Website: www.silonite.com.au



VOCO GmbH

Anton-Flettner-Straße 1-3
27472 Cuxhaven
Telefon: +49 47 21 7 19-0
Telefax: +49 47 21 7 19-1 09
E-Mail: info@voco.de
Website: www.voco.de

The IADT Program Committee appreciates the contributions from our Sponsors and Exhibitors and encourages all delegates to visit their booth locations for the latest in products and services. Without their generous contributions, this meeting would not be possible.

IADT 2014 Officers / Directors / Committees

President:

Lars Andersson, Kuwait

Secretary / Treasurer:

Lamar Hicks, USA

2014 Directors:

Ayse Nil Altay, Turkey
Frederic Barnett, USA
Nestor Cohenca, USA
Peter Day, UK
Eva Lauridsen, Denmark
Olle Malmgren, Sweden
Juan Eduardo Onetto, Chile

Information Committee:

Juan Onetto, Chile (Chair)
Eva Lauridse, Denmark
Olle Malmgren, Sweden
Denise Seivers, Chile
Sergio Uribe, Chile
Eben Yancey, USA (ad hoc)

Membership & Recruitment Committee:

Leif Bakland, USA (Chair)
Elisabetta Cotti, Italy
Ece Eden, Turkey
Yi Gong, China
Depak Sharma, India
Renato Lenzi, Brazil
Mitsuhiro Tsukiboshi, Japan
Steve Harlamb, Australia

Conference Organizing Committee:

Lars Andersson, Kuwait (Chair)
Ayse Nil Altay, Turkey
Ece Eden, Turkey
Peter Day, UK
Renato Lenzi, Brazil
Olle Malmgren, Sweden
Eben Yancey, USA (ad hoc)

Officers Nominating Committee:

Mitsuhiro Tsukiboshi, Japan (Chair)

Fellowship Committee:

Alex Moule, Kuwait (Chair)

President Elect:

Alex J. Moule, Kuwait

Past President:

Mitsuhiro Tsukiboshi, Japan

Research Committee:

Peter Day, UK (Chair)

Education Committee:

Nestor Cohenca, USA (Chair)

Honors & Awards Committee:

Alex Moule, Kuwait (Chair)
Jens Andreasen, Denmark
Lars Andersson, Kuwait
Marie Therese Flores, Chile
Barbro Malmgren, Sweden
Mitsuhiro Tsukiboshi, Japan

Sponsorship Committee:

Nestor Cohenca, USA (Chair)
Mitsuhiro Tsukiboshi, Japan
Eben Yancey, USA (ad hoc)

Finance Committee:

Lamar Hicks, USA (Chair)

Constitution & By-Laws Committee:

Lamar Hicks, USA (Chair)

Glossary Committee:

Lamar Hicks, USA (Chair)
Peter Day, UK
Marie Therese Flores, Chile

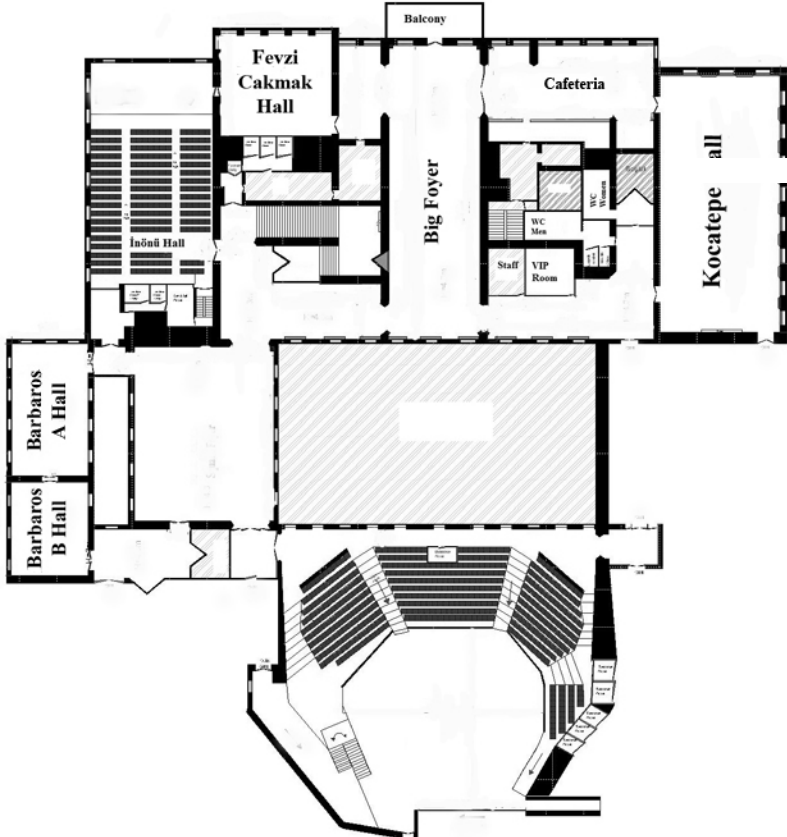
Ad-Hoc Committees:

Alex Moule, Kuwait (Chair)

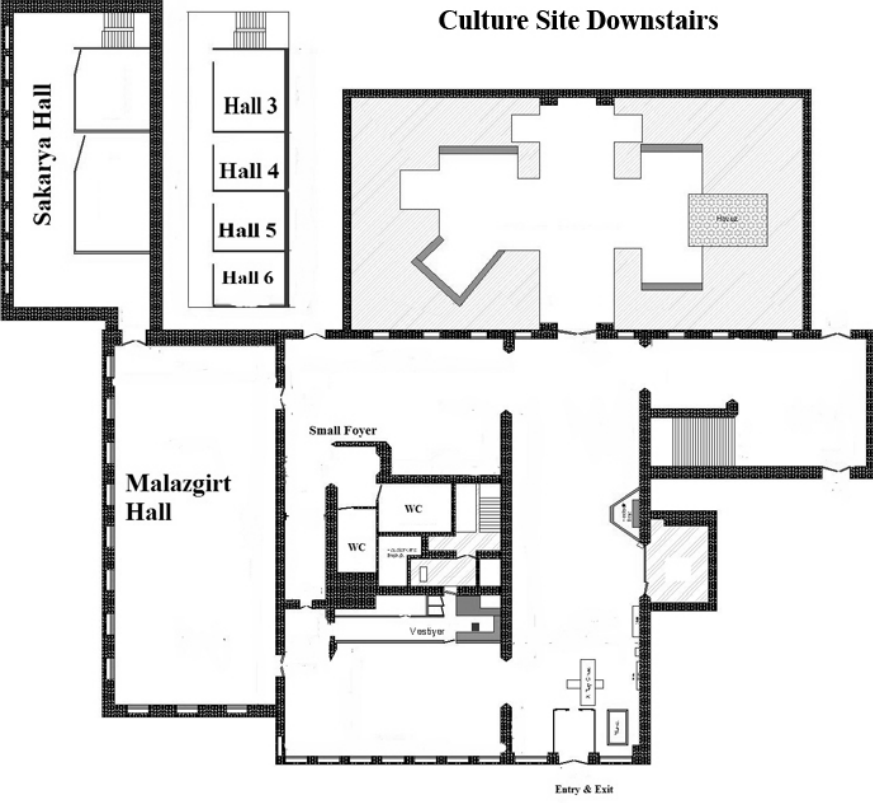
Strategic Planning Committee:

Lars Andersson, Kuwait (Chair)
Yango Pohl, Germany
Lamar Hicks, USA

Culture Site Upstairs



Culture Site Downstairs



Conference Overview

Thursday, June 19th

09:00 -- 17:00 IADT Board Meeting (*Invitation only -- Board Members*)

Thursday, June 19th

09:00 -- 17:00	Registration	
10:00 -- 13:00	Elective Workshops 1 & 2 (<i>Concurrent workshops</i>)	1: Malazgirt A / 2: Malazgirt B
13:00 -- 14:00	<i>Free time for Lunch</i>	
14:00 -- 17:00	Elective Workshops 1 (cont.) & 7 (<i>Concurrent workshops</i>)	1: Malazgirt A / 7: Malazgirt B
14:00 -- 18:00	* Oral Presentation (<i>Concurrent Selected Abstracts</i>)	Victory Hall / Malazgirt Hall
18:00 -- 19:00	* Poster Presentation Session	Victory Hall / Malazgirt Hall
19:00 -- 20:30	Welcome & Poster Reception	Poster & Exhibit Area

Friday, June 20th

09:00 -- 09:45	Opening Ceremony	Victory Hall
09:45 -- 13:15	Scientific Plenary Session (<i>Keynote Presentations</i>)	Victory Hall
13:15 -- 14:30	Conference Luncheon	
14:30 -- 18:00	Scientific Concurrent Sessions (<i>Keynote Presentations</i>)	Victory Hall / Kocatepe Hall
18:00	Session Adjourns	
20:00 -- 22:00	* Gala Dinner (<i>Elective</i>) on the Bosphorus	


Saturday, June 21st

09:00 -- 12:30	Scientific Plenary Session (<i>Keynote Presentations</i>)	Victory Hall
12:30 -- 13:30	Conference Luncheon	
13:30 -- 15:00	Scientific Plenary Session (<i>Keynote Presentations</i>)	Victory Hall
15:00 -- 16:00	Mehteran (Ottoman Military Band)	Conference Lobby
16:00 -- 16:45	Scientific Oral and Poster Presentation Awards	Victory Hall
16:45	Presentation of 19th IADT World Congress in Australia	Victory Hall
17:00	Closing Ceremony / Conference Adjourns	

* *Requires Banquet Ticket*

Conference Social Events

Thursday, June 19th



Welcome & Poster Reception

Pick-up your program books, conference credentials and support your colleagues by reviewing their posters. Poster Session is scheduled from 19:00 -- 20:30. Posters will remain up throughout the Welcome Reception for all to review. Entertainment, Light appetizers, beer and wine will be available for your pleasure.

Location: Poster & Exhibit Area, Military Museum & Cultural Center

Time: 19:00 -- 20:30

Fee: Conference delegates -- no charge, included in your conference registration. Accompanying guest must pay Guest Fee



Friday, June 20th

Opening Ceremony

Show will be open to all conference participants

Location: Victory Hall, Military Museum & Cultural Center

Time: 09:00

Gala Banquet and Reception on the Bosphorus

Elective: Requires a Banquet Ticket

Location: Gala dinner will be held on Limak Eurasia's "The Istanbul" boat. Europe on one side and Asia on the other... Do not miss this unforgettable night on the Bosphorus.

Includes: Transfer, Entertainment, Light Reception, Dinner and Wine. A cash bar will be available for your enjoyment

Dress: Formal optional, traditional dress of your country acceptable. The average temperature is 71°F, 22°C

Time: 20:00 -- 22:00

Fee: \$160 US per person



Saturday, June 21st

Mehteran (Ottoman Military Band)

Show will be open to all conference participants

Location: Military Museum & Cultural Center

Time: 15:00 -- 16:00

Scientific Oral and Poster Presentation Awards

Show will be open to all conference participants

Location: Victory Hall- Military Museum & Cultural Center

Time: 16:00 -- 16:45

Presentation of 19th World Congress -- Australia, 2016

Show will be open to all conference participants

Location: Victory Hall - Military Museum & Cultural Center

Time: 16:45



(Business Casual Attire Unless Noted)

Conference Elective Activities



Pre-Conference Tour Two-Day Trip to Cappadocia

Tuesday, June 17th

Istanbul to Cappadocia via Kayseri

Meet at your Istanbul hotel's lobby and transfer to the airport (congress hotels only) Arrival at Cappadocia. Plan on leaving early morning on June 17th and returning early evening on June 18th. Exact departure and return times will be based on flight arrangements.

We spend the day visiting Goreme Open Air Museum where you will find rock cut churches decorated with frescoes bearing biblical scenes. Then we continue to Zelve Open Air Museum, Uchisar and Avclar Valleys. We also see the unusual formations of fairy chimneys, columns of rock shaped by nature. Lunch during the tour at own expense. Dinner and overnight at in Cappadocia.

Wednesday, June 18th

Cappadocia to Istanbul via Kayseri

Breakfast at your hotel. We spend another day in Cappadocia. We visit Kaymakli Underground City. Cappadocia is famous for its several underground cities where Christians were hiding themselves from their enemies. Kaymakli with its several levels, storage and living areas, wineries, ventilation tunnels is a good example to these structures. We also see more of Cappadocia for the rest of the day. Transfer to the airport and return flight to Istanbul. Arrive in Istanbul and transfer to your hotel (congress hotels only).

This package includes: Roundtrip airfare, Transportation by air-conditioned vehicle, 1 night accommodation at a 4-star hotel, 1 breakfast and 1 dinner, English speaking guidance, Museum admission

Excludes: Personal expenses at the hotel, Drinks at meals, Lunches, Gratuities

Price:

- **\$595 US** per person in twin room
- **\$645 US** per person in single room

Notes: 6 participants minimum are required to operate this excursion

Full Day Excursions

Thursday, June 19th or Saturday, June 21st

(08:30 -- 17:30)

Highlights of Istanbul: Hippodrome, Blue Mosque, Hagia Sophia, Topkapi Palace and Grand Bazaar -- Full Day Excursion with Lunch

Transfer to the Hippodrome, famous for chariot races, this Roman stadium dates back to the time of the Emperor Constantine the Great. We will visit the Blue Mosque, probably the most impressive mosque in the world. Our tour continues with the visit of Hagia Sophia Museum which was originally built as a church then converted into a mosque after the conquest in the 15th C. One of the oldest ancient buildings on Earth, this is well worth a visit.

We have our lunch at a local restaurant and then continue the day with the tour of Topkapi Palace, the imperial residence of the Ottomans. See the courtyards, a superb porcelain collection, the famous world treasury, calligraphy, Sultan's costumes and the Holy relics of Prophet Muhammed. Also visit Archaeological Museum located within the grounds of Topkapi Palace (parts of the museum are being renovated at the moment and we will be able to visit the sections that are open during the time of our visit). Finish the day at the Grand Bazaar where thousands of small shops are located.

Price: \$85 US per person



Conference Elective Activities



Pre-Conference Tour

Friday, June 20th

(08:30 -- 17:30)

Hippodrome, Blue Mosque, Hagia Sophia, Topkapi Palace and Grand Bazaar -- Full Day Excursion with Lunch

Transfer to the Spice (Egyptian) Bazaar where you can find spice shops selling varieties of spices, nuts, fruit and herbal teas and surely Turkish Delight. We then walk across the road to the pier where we catch the ferry for a cruise on the Bosphorus between Europe and Asia.

You can admire magnificent views of the Bosphorus where numerous palaces, mansions are located as well as the Rumeli Fortress. This was built by Sultan Mehmet the Conqueror as part of the preparations of his campaign to capture Istanbul. We land on the European side about half way up the Bosphorus and drive to the restaurant for lunch.

We drive across the Bosphorus over the Bosphorus Bridge to Beylerbeyi Palace. Built around 1860s, this was the summer residence of the Imperial family. After the tour we drive up to Camlica Hill from where you can enjoy a magnificent view of Istanbul. Our return journey takes us over the Bosphorus Bridge.

Price: \$77 US per person

Half Day Excursions

Price: \$45 US per person

Thursday, June 19th or Saturday, June 21st

(08:30 -- 13:00)

Hippodrome, Blue Mosque, Hagia Sophia

Transfer to the Hippodrome. Famous for chariot races, this Roman stadium dates back to the time of the Emperor Constantine the Great. We then see the Blue Mosque, probably the most impressive mosque in the world.

Our tour continues with the visit of Hagia Sophia Museum which was originally built as a church then converted into a mosque after the conquest in the 15th C. One of the oldest ancient buildings on Earth, this is well worth a visit.

Friday, June 20th

(08:30 -- 13:00)

Spice Bazaar, Boat Trip on the Bosphorus

Transfer to the Spice (Egyptian) Bazaar where you can find spice shops selling varieties of spices, nuts, fruit and herbal teas and surely Turkish Delight. We then walk across the road to the pier where we catch the ferry for a cruise on the Bosphorus between Europe and Asia.

You can admire magnificent views of the Bosphorus where numerous palaces, mansions are located as well as the Rumeli Fortress. This was built by Sultan Mehmet the Conqueror as part of the preparations of his campaign to capture Istanbul. We land on the European side about half way up the Bosphorus.

Friday, June 20th

(13:00 -- 17:00)

Spice Bazaar, Boat Trip on the Bosphorus

Transfer to the old city across the Golden Horn. We continue our drive then along the city walls and arrive at the Church of St. Saviour in Chora (Kariye Museum), a unique example of the world famous Byzantine mosaics depicting lifecycles of Mary and Christ.

After that we drive to Eyup where we will visit the Sanctuary of Eyup Sultan, a Muslim warrior of early Islamic period. After the visit, stop at the famous Cafe Pierre Loti named after the French poet who spent many years in Istanbul. Enjoy a cup of Turkish Coffee and the view of the Golden Horn.



Conference Elective Activities

Post-Conference Tour

Two-Day Trip to Ephesus & Pergamon

Sunday, June 22nd

Istanbul to Kusadasi via Izmir and Pergamon

Meet at your Istanbul hotel's lobby and transfer to the airport for your flight to Izmir. (congress hotels only) Arrival at Izmir Airport. Plan on leaving early morning on June 22nd and returning early evening on June 23rd. Exact departure and return times will be based on flight arrangements.

We will drive to Bergama to visit the Acropolis and the Aesclepium of Pergamon. We will first visit the Acropolis set on top of a steep hill approximately 400 meters above sea level. Famous for its Trajan Temple, library and Zeus Altar, Pergamum Acropolis still reflects its former glory. Its library once was as important as its rival in Alexandria.

Following lunch, we continue to the Aesclepium of Pergamum. Linked to the Lower Roman City of Pergamum by a ceremonial road, Aesclepium served as an ancient medical Center dedicated to the God of Healing, Aesclepius and his daughter Hygenia. We drive to Kusadasi in the late afternoon via Izmir. Arrive at Kusadasi in the early evening. Dinner and overnight in Kusadasi.

Monday, June 23th

Kusadasi to Istanbul via Ephesus and Izmir

After breakfast at your Hotel, we will drive to the House of Virgin Mary located at the top of a mountain near Ephesus. We then continue with the tour of the ancient site of Ephesus, one of the most important cities of antiquity. We are going to visit the third settlement dating back to the Hellenistic and Roman times. Ephesus still is well preserved with its magnificent buildings such as Celsus Library, the Great Theatre, Hadrian's Temple, Trojan's Fountain, State and Commercial Agoras, Marble Road, Curetes Street. Lunch during the tour. In the afternoon, we will visit the Ephesus Museum and following that we drive to the airport for the return flight back to Istanbul. We arrive at Istanbul's Ataturk Airport in the evening and drive back to your Istanbul Hotel. (congress hotels only)

This package includes: Roundtrip airfare, Transportation by air-conditioned vehicle, 1 night accommodation at a 4-star hotel, 1 breakfast and 1 dinner, English speaking guidance, Museum admission

Excludes: Personal expenses at the hotel, Drinks at meals, Lunches, Gratuities

Price:

- **\$595 US** per person in twin room
- **\$645 US** per person in single room

Notes: 6 participants minimum are required to operate this excursion



Program Moderators

Thursday, September 10th

Graduate Student Treatment Planning Session

Dr. Martin Gross

Friday, September 11th

Focus Session I (*Morning*)

Dr. Kiyoshi Koyano

Dr. Terry Walton

Concurrent Session A (*Afternoon*)

Dr. Alan Payne

Dr. Keeichi Sasaki

Concurrent Session B (*Afternoon*)

Dr. Harold Preiskel

Dr. Francine Albert

Saturday, September 12th

Concurrent Session A (*Morning*)

Dr. Bernard Smith

Dr. Steven Eckert

Saturday, September 12th (*continued*)

Concurrent Session B (*Morning*)

Dr. George Zarb

Dr. Ting Jiang

Concurrent Session C – Maxillofacial
(*Morning*)

Dr. Arun Sharma

Dr. Terry Kelly

Concurrent Session A (*Afternoon*)

Dr. Cecilia Dong

Dr. Jung-Sung Shim

Concurrent Session B (*Afternoon*)

Dr. Michael MacEntee

Dr. Ann Wennerberg

Sunday, September 13th

Focus Session II (*Morning*)

Dr. Tom Taylor

Dr. Sang-Wan Shin



Conference Program Schedule

Thursday, June 19th

- 09:00 - 17:00 IADT Board Meeting (*Invitation only- Board Members*)
- 09:00 - 10:00 Registration
- 10:00 - 13:00 Elective Workshops (*Concurrent workshops*)
Workshop 1 (Part I):
Interpretation of Cone-Beam CT Imaging for DentoMaxillofacial Trauma Patients
 Presentation in Turkish and English.
 Room: Malazgirt A
- Workshop 2:**
Direct Esthetic Restoration of Fractured Anterior Teeth
 Presentation in Turkish
 Room: Malazgirt B
- 13:00 - 14:00 Free time for Lunch
- 14:00 - 17:00 Elective Workshops (*Concurrent workshops*)
Workshop 1 (Part II):
Interpretation of Cone-Beam CT Imaging for DentoMaxillofacial Trauma Patients
 Presentation in Turkish
 Room: Malazgirt A
- Workshop 7:**
Peri-Implantitis- The Disease of the Future!
 Presentation in Turkish
 Room: Malazgirt B
- 14:00 - 19:00 Research Lecture Presentations (*Concurrent Sessions*)
 Presentations presented in English
 Room: Victory Hall / Malazgirt Hall
- 18:00 - 19:00 Poster Presentation
- 19:00 - 20:30 Welcome & Exhibit Reception

Friday, June 20th

(All presentations will be presented in English on Friday and Saturday)

- 09:00 - 09:45 Opening Ceremony
 Room: Victory Hall
- 09:45 - 01:15 Scientific Plenary Session (*Keynote Presentations*)
 Room: Victory Hall
- 09:45 **Lars Andersson** (Kuwait)- *The place of accident is where the prognosis is decided*
- 10:15 **Leif Bakland** (USA)- *Biological basis for dental trauma management*
- 11:00 Coffee Break
- 11:30 **Michel Goldberg** (France)- *Pulp regeneration and updates*
- 12:15 **Asgeir Sigurdsson** (USA)- *Endodontic management of traumatized teeth*
- 13:00 - 14:30 Conference Luncheon
- 14:30 - 17:15 Scientific Concurrent Sessions (*Keynote Presentations*)
 Room: Victory Hall Room: Kocatepe Hall
- 14:30 **Peter Day** (UK)- *Evidence based dental traumatology* **Barbro Malmgren** (Sweden)- *Managing the alveolar crest after ankylosis-alveolar bone ridge preservation*
- 15:15 **Mona Al Sane** (Kuwait)- *Dental trauma management: How best to inform the public?* **Christine Berthold** (Canada)- *Splinting of traumatized teeth- when, why and how?*
- 16:00 Coffee Break
- 16:30 **Maria Theresa Flores** (Chile)- *What is new in the management of traumatic injuries to primary teeth?* **Olle Malmgren** (Sweden)- *Orthodontics and traumatized teeth- when and how?*
- 17:15 **Jens Andreasen & Eva Lauridsen** (Denmark)- *Using the Dental Trauma Guide* **Sebnem Turkun** (Turkey)- *Esthetic Considerations after Dental Trauma*
- 18:00 Session Adjourns
- 20:00 - 22:00 *Gala Dinner (*Elective*)

Conference Program Schedule

Saturday, June 21st

- 09:00 - 12:30 Scientific Plenary Session (*Keynote Presentations*)
Room: Victory Hall
- 09:00 **Eva Lauridsen** (Denmark)- *Managing combined dento-alveolar injuries*
- 09:45 **Korkud Demirel** (Turkey)- *Periodontal plastic surgery in the treatment of gingival traumas*
- 10:30 Coffee Break
- 11:00 **Mitsuhiro Tsukiboshi** (Japan)- *Autotransplantation in the management of traumatized dentition*
- 11:45 **Nesto Cohenca** (USA)- *Sports dentistry and prevention of dental trauma*
- 12:30 - 13:30 Conference Luncheon
- 13:30 - 15:00 Scientific Plenary Session (*Keynote Presentations*)
Room: Victory Hall
- 13:30 **Jan Gottlow** (Sweden)- *Rehabilitating the anterior region with implants after trauma*
- 14:15 **Jens O. Andreasen** (Denmark)- *Can traumatized dental tissue regenerate after severe trauma?*
- 15:00 - 16:00 Mehteran (Ottoman Military Band)
- 16:00 - 16:45 Scientific Oral and Poster Presentation Awards
- 16:45 Presentation of 19th IADT World Congress in Australia, 2016
- 17:00 Closing Ceremony- Conference Adjourns

Research Lecture Presentations

Thursday, June 19th

	<u>Session 1</u> Award Nominees Room: Victory Hall	<u>Session 5</u> Room: Malazgirt A	<u>Session 9</u> Room: Malazgirt B
14:00	Sondros Albadri, United Kingdom- <i>Clinical and Radiographic Outcomes of Root End Closure</i>	Merve Meşe, Turkey- <i>Effect of Various-Irrigation-Protocols on Debridement and Apical-Extrusion in Revascularization Procedures</i>	Uzay Koç Vural, Turkey- <i>Clinical Evaluation of Composite Restorations of Fractured Anterior Teeth</i>
14:10	Flaviana Bombarda de Andrade, Brazil- <i>Dentinal Tubular Disinfection of Tri-Antibiotic and Calcium Hydroxide Pastes</i>	Juan Onetto, Chile- <i>Effect of Various-Irrigation-Protocols on Debridement and Apical-Extrusion in Revascularization Procedures</i>	Saqib Siddiqui, Pakistan- <i>Comparison of Tooth Shade Matching: Visual vs. Digital Camera Method</i>
14:20	Ani Belcheva, Bulgaria- <i>Tooth Splinting and Maintenance of Vitality in Traumatized Permanent Teeth</i>	Masoud Saatchi, Iran- <i>Effect of Various IKI Concentrations on the MTA Antimicrobial Properties</i>	Esra Yanar, Turkey - <i>Comparison of Restored Premolars with Uncomplicated and Complicated Cusp Fractures</i>
14:30	Mostafa ExEldeen, Belgium- <i>Three-dimensional (3D) Analysis of Regenerative Endodontic Treatment Outcome</i>	Denise Sievers, Chile- <i>Personalized and Predictive Prosthodontics for Elderly Patients</i>	Bilal Yasa, Turkey- <i>Effect of Novel Restoratives with Retentive-slots on Fracture-Resistance of Endodontically-Treated-Teeth</i>
14:40	Didem Atabek, Chile- <i>The Role of Time-Elapsed on Prognosis of Crown-Related Fractures</i>	Giglia Sirandoni, Turkey- <i>Decision-making in Diagnosis, Treatment Planing and Follow-up Using CBCT</i>	Huseyin Akcay, Turkey- <i>Effect of Blood-Contamination on Bond-Strength of Root-End-Placed MTA/Biodentine after Root-End-Resection</i>
14:50	Marie Therese Flores, Chile- <i>Reliability of a Dental Trauma Record to Identify Child Abuse/Neglect</i>	Wahid Terro, Lebanon- <i>Management of Acute Dento-Alveolar Injuries</i>	Mohammed Alshehri, Saudi Arabia- <i>The Effects of Myrrh on Suture Material Strength</i>

(Continued)

Research Lecture Presentations

Thursday, June 19th

	<u>Session 2</u> Award Nominees Room: Victory Hall	<u>Session 6</u> Room: Malazgirt A	<u>Session 10</u> Room: Malazgirt B
15:00	Joan Emien Enabulele, Nigeria- <i>Prevalence of Traumatic Dental Injury and Complications from Late Presentation</i>	Ayca Tuba Ulusoy, Turkey- <i>Antimicrobial Effect of Taurolidine and N-Acetylcysteine on Enterococcus Faecalis Phenotypes</i>	Christoph Vasak, Austria- <i>Evaluation of the Accuracy of Template Guided Implant Placement</i>
15:10	Maria Eugenia Ortiz, Chile- <i>Characterization of Traumatic Dental Injuries caused by Interpersonal Physical Violence</i>	Seyed Amir Mousavi, Iran- <i>Regenerative Endodontic (Revascularization): Review of Literature</i>	Kate Counihan, United Kingdom- <i>Yorkshire Dentists' Experience of Avulsed</i>
15:20	Lian Wu, Chine- <i>Treatment Outcome of Mid-Root Fractures in Primary Teeth</i>	Mahshid Sheikh Nezami, Iran- <i>Therapeutic Suggestions for Complicated Horizontal Root Fractures</i>	Pinar Demir, Turkey- <i>A Retrospective Study of Traumatic Dental Injuries in Malatya, Turkey</i>
15:30	Barbro Malmgren, Sweden- <i>Effect of topical treatment with Doxycycline on Replanted Permanent Incisors</i>	Ozlem Marti Akgun, Turkey- <i>Traumatic Dental Injuries Among Children in Gulhane Medical Academy, Turkey</i>	Begüm Gök, Turkey- <i>The Application Period According to Type of Primary Dentition Trauma</i>
15:40	Anna Oldin- <i>Traumatic Dental Injuries Among Children: Who, When and Where?</i>	Serpil Djemal- <i>Avulsion Injuries Presenting at Kings College Hospital Dental Institute</i>	Taskin Gurbuz- <i>Traumatic Dental Injuries to the Teeth in Children with Epilepsy</i>
15:50	Iman Parisay- <i>A New Storage Medium for an Avulsed Tooth</i>	Rawan Elkarmi- <i>Prevalence of Traumatic Dental Injuries Among Preschool Children in Jordan</i>	Gideon Holan- <i>Contribution of Radiographs to Prevalence of Trauma to Primary Incisors</i>
16:00 -16:30	Break		

(Continued)

Research Lecture Presentations

Thursday, June 19th

	<u>Session 3</u> Room: Victory Hall	<u>Session 7</u> Room: Malazgirt A	<u>Session 12</u> Room: Malazgirt B
16:30	Aylin Akbay Oba, Turkey- <i>Apical Microleakage of Different Materials in Coronal Root Fragments</i>	Nilüfer Ersan, Turkey - <i>Is Panoramic Radiography Sufficient for Diagnosis of Mandibular Corpus Fractures?</i>	Yeon Joo Lee, Korea- <i>Prevalence of Pathologic Root Resorption in the Maxillary Primary Incisors</i>
16:40	Hacer Aksel, Turkey - <i>Evaluation of Irrigant Extrusion in Simulated Immature Permanent Teeth</i>	Rogério Geraldino, Brazil- <i>Adherence to the IADT Trauma Management Guidelines by Pedodontists</i>	Aysegül Saritekin, Turkey- <i>One Year Follow up Time is Enough for Crown Fractures</i>
16:50	Sevinç Aktemur Türker, Turkey- <i>Effect of Qmix on Removing Calcium Hydroxide From Root Canals</i>	Jamileh Ghoddusi, Iran- <i>Prevalence of Dental Trauma Among Primary School Children in Iran</i>	Fatih Sengül, Turkey- <i>Restrospective Comparasion of Dento Alveolar Traumas in a Pedodontic Clinic</i>
17:00	Şefika Nur Akyüz Ekim, Turkey- <i>Effect of Different Irrigant Activation Protocols on Push-out Bond Strength</i>	Albina Herbel, Argentina- <i>"In VIVO" Comparison Among Periapical, Panoramic X-Rays and Cone-Beam</i>	Huseyin Simsek, Turkey- <i>Soft Tissue Traumas Accompanied with Dento-alveolar Trauma</i>
17:10	Qasem Alomari, Kuwait- <i>Effect of Preparation for Post on the Remaining Dentine Thickness</i>	Blanca Hermosilla, Chile- <i>Injury Certification And Dentoalveolar Trauma: A Challenge</i>	Georg Strbac, Austria- <i>Prevalence of Maxillary Incisors root Resorption Caused by Impacted Canines</i>
17:20	Hengameh Bakhtiar, Iran- <i>Revascularization of Permanent immature Necrotic Teeth</i>	Rodica Luca, Romania- <i>Dental injuries in Primary Teeth - Epidemiological Study</i>	Sadia Tabassum, Pakistan- <i>Determining IOTN in Patients Reporting to AFID, Rwp, Pakistan</i>

(Continued)

Research Lecture Presentations

Thursday, June 19th

	<u>Session 4</u> Room: Victory Hall	<u>Session 8</u> Room: Malazgirt A	<u>Session 10</u> Room: Malazgirt B
17:30	Sule Bayrak, Turkey- <i>Evaluation of Mineral Trioxide Aggregate and Bioaggregate as Apical Barrier</i>		Ayce Unverdi Eldeniz, Turkey- <i>Reinforcement of Immature-Teeth with a Novel Silicate-based-sealer and Post System</i>
17:40	Burak Carikioglu, Turkey- <i>Comparison of Coronal Fracture Resistance Restored with Intracanal Reinforcement Material</i>	Ousama Rhouma, Libyan Arab Jamahiriya- <i>International Dental Traumatology Guidelines: The Knowledge and Application</i>	Ceylan çağıl Yetiş, Turkey- <i>Importance of the Type and Time of Primary Teeth Luxations</i>
17:50	Bruno Cavalini Cavenago, Brazil- <i>Evaluation of Dentin Disinfection by Using MTA with Different extracts</i>	Carolina Rodriguez, Chile- <i>Pulp Necrosis in Permanent Teeth with Enamel-Dentin Crown Fracture</i>	Özgür Doğan, Turkey- <i>Wearability-Variable Physiological Effects of Mouthguards On The Performance of Basketball-Players</i>
18:00		Tomislav Skrinjaric, Croatia- <i>Childhood Aggression as a Risk Factor for Injury Repetition</i>	Kristina Gorseta, Croatia- <i>Prevalence and Prevention of Dental Injuries in Young Taekwondo Athletes</i>
18:10	Kurt Ebeleseder, Austria- <i>Injuries to the Gingiva Resulting from Dento-alveolar Trauma</i>	Cihan Alp Sönmez, Turkey- <i>Late Intervention Causes more Attention</i>	Hüseyin Karayılmaz, Turkey- <i>The Incidence of Dental Trauma in Turkish Muay Thai Players</i>
18:20	Ayhan Eymirli, Turkey - <i>Effect of Vehicle and Removal Technique on Calcium Hydroxide Removal</i>	Carlos Zaror, Chile- <i>Factors Associated to Survival Rates in Replanted Permanent Incisors</i>	José Miguel Montero Parrilla, Cuba- <i>Temporomandibular Disorders in Bxing Athletes</i>
18:30	Mehmet Burak Güneşer, Turkey- <i>Vertical-fracture Resistance of Roots Obturated with Novel Calcium-silicate-based Sealers</i>	Samira Adnan, Pakistan- <i>Comparison of Various Storage Media for Avulsed Teeth; Systematic Review</i>	Shady Moussa, Egypt- <i>Tooth Mousse and other(CPP-ACP)Complex Effects On children's Cariogenic Microflora</i>
18:40	Güldağ Herdem, Turkey - <i>Revascularization Treatment in Various Trauma Type</i>	Ionel Dan-Cristian, Romania- <i>Uncomplicated Crown Fracture - Restorations Finite Element Analysis</i>	Emre Ozel, Turkey- <i>Knowledge of Coaches About Oro-Facial Injuries and Mouthguard Usage</i>
18:50	Mehmet Emin Kaval, Turkey- <i>Intentional Replantation of Adhesively Reattached Vertically Fractured Maxillary Single-rooted Teeth</i>	Özgür Kanık, Turkey- <i>Microhardness of Resin-Coated Encapsulated Glass Ionomer Cements</i>	Elif Bahar Tuna-Ince, Turkey- <i>Evaluation of Dental Trauma and Mouthguard Usage in Contact Sports</i>

*Views expressed by the presenters at the IADT Meeting are solely their own and do not necessarily reflect the positions or policies of the IADT
The IADT reserves the right to cancel or modify its program as circumstances might dictate.*



Dr. Mona Al-Sane

Assistant Professor, Faculty of Dentistry
Developmental and Preventive Sciences
Kuwait University, Health Sciences Center
Kuwait

Presentation: *Dental Trauma Management: How Best to Inform the Public?*

Dr. Al-Sane earned her bachelor of dental surgery degree from Leeds Dental Institute, UK. She then became a specialist pediatric dentist in 2004, after completing a 3 year pediatric dentistry residency training at the University of Illinois at Chicago (UIC). Dr. Al-Sane also, received a Master's in Oral Sciences degree while completing her specialty training at UIC. Dr. Al-Sane is currently an assistant professor at the department of Developmental and Preventive sciences, Kuwait University. Her main research interests are in the areas of cariology, dental traumatology and oral health awareness




Lars Andersson DDS, PhD DrOdont

Professor Oral & Maxillofacial Surgery
Chairman Department of Surgical Sciences
Health Sciences Center
Kuwait University, Kuwait

Presentation: *The Place of Accident is where the Prognosis is Decided*

Dr Andersson underwent undergraduate and research training at Karolinska Institute in Stockholm, Sweden and became specialist in oral and maxillofacial surgery in 1981. He defended his doctoral dissertation thesis 1988 on experimental and clinical studies on ankylosis and associated root resorption after replantation of teeth and was appointed Docent at Karolinska Institute, Stockholm, Sweden in 1990. In the 90s he chaired a national specialist training program in oral and maxillofacial surgery in Sweden, and belonged to the first generation of implant surgeons; he also ran an international implant training program. Since 2002 he has been professor in oral and maxillofacial surgery at Kuwait University. His main areas of clinical and research interest are trauma, orthognatic and implant surgery and he has published more than hundred articles in international scientific journals. Dr Andersson is editor and chapter author of textbooks in the fields of trauma and oral and maxillofacial surgery. He is currently editor-in-chief of the international scientific journal, Dental Traumatology and president of the International Association of Dental Traumatology.



Dr. Jens Ove Andreasen DDS, Odont. Dr.h.c.
University Hospital
Copenhagen, Denmark

Presentations: (1) *Using the Dental Trauma Guide*
(2) *Can Traumatized Dental Tissue Regenerate After Severe Trauma?*

Dr. Andreasen received his dental degree from the Royal Dental College, Copenhagen, in 1959. He did his postgraduate training in Oral and Maxillofacial Surgery at the University Hospital in Copenhagen, where he now is an associate Professor.

Dr. Andreasen has authored 350 publications and 11 textbooks, covering topics such as dental traumatology, tooth replantation and autotransplantation, tooth eruption and tooth impaction. In relation to traumatology the Textbook and Color Atlas of Dental Traumatology is now in its 4th edition and include 42 contributors. In addition he is the initiator of the web based Dental Trauma Guide, which is now in use in 180 countries. It contains information of a series of prospective long term studies of all types of traumatic dental injuries carried out at the trauma center and Department of Oral and Maxillo-Facial Surgery as well as information from 50 animal experiments reproducing treatment scenarios of various dental traumas affecting primary as well as permanent teeth. Andreasen has received four honorary doctorate degrees and has been an invited lecturer in 48 countries.



Leif K. Bakland, DDS
Endodontics at the School of Dentistry
Loma Linda University, California USA

Presentation: *Biological Basis for Dental Trauma Management*

Dr. Leif K. Bakland is the Ronald E. Buell Professor of Endodontics at the School of Dentistry, Loma Linda University, in California. He completed an endodontic residency at Harvard School of Dental Medicine/Forsyth Dental Center in Boston, Massachusetts and has been involved in teaching, research, publications, and professional organizations for over 40 years.

His research and publication interests include both endodontics and dental traumatology. He has collaborated with Dr. Jens Andreasen in Copenhagen on many research projects, including a World Health Organization Fellowship in 1994 to investigate treatment of intrusive luxations. He has lectured worldwide on endodontics and dental trauma. Dr. Bakland has been active in service to organized dentistry by holding many leadership positions in many organizations, including the International Association of Dental Traumatology in which he served as Secretary/Treasurer and as Executive Director for more than 15 years. He is a co-editor of *Traumatic Dental Injuries* and *Ingle's Endodontics* and has written chapters in many textbooks on the subject of dental trauma. He is an associate editor of *Dental Traumatology*.



Dr. Christine Berthold, PD Dr. med. dent.

University of British Columbia
Faculty of Dentistry
Division of Endodontics
2199 Wesbrook Mall
Vancouver, BC V6T 1Z3
Canada

Friedrich Alexander University Erlangen
Dental Clinic 1 - Operative Dentistry and Periodontology
Glueckstr. 11
91054 Erlangen
Germany

Presentation: *Splinting of Traumatized Teeth – When, Why and How?*

Christine Berthold received her dental degree from the Faculty of Dentistry of the University of Halle-Wittenberg, Germany in 1997. She has taught and practiced at the Martin-Luther-University Halle from 1997 to 2002 and at the Friedrich-Alexander-University Erlangen from 2002 to 2012 with the focus in Dental Traumatology, Endodontics and Restorative Dentistry.

Her scientific career started with her doctoral thesis „Investigation on Splinting Therapy after Dento-alveolar Trauma“, followed by continuous research in the field of dental traumatology, in Germany, as well as during repeated research fellowships at the University of Texas, Houston. From 2008 to 2010, she received the “Annual Research Scholarship for Outstanding Female Researchers in Bavaria”. She has published in peer-reviewed journals, has frequently presented research findings at international meetings and has given various courses and invited presentations in the field of Dental Traumatology and Endodontics. In 2012, she finished her Habilitation (PhD) at the University of Erlangen, Germany with the title “Conservative Dentistry after Dento-alveolar Trauma”.

She is a member of the International Association of Dental Traumatology, International Association of Dental Research, American Association of Endodontics, Canadian Academy of Endodontics, German Society of Operative Dentistry). She serves as an editor for the journal “Endodontie” and is a member of the review board of the journals “Quintessence International” and “Dental Traumatology” and Clinical Oral Investigations”.

In 2012, she moved to Canada and is recently in the postgraduate Endodontic program at the University of British Columbia, Vancouver.



Dr. Nestor Cohenca, DDS

Director of Endodontics and Traumatology
Center for Pediatric Dentistry and Seattle Children's Hospital
Seattle, Washington USA

Presentation: *Sports Dentistry and Prevention of Dental Trauma*

Nestor is a Director of the IADT, chairman of the IADT Education and Sponsorship committees and an Associate Editor of the Dental Traumatology. He was one of the pioneers on the use of CBCT in endodontics and traumatology and is considered an expert in this field. He completed the endodontic program at the Hebrew University in Jerusalem cum laude and received the Best Graduate Student Award in 1994. He served 11 years on the faculty. Nestor is a Diplomate of and was an examiner for the Israel Board of Endodontics. From 2003 to 2005 he was a clinical assistant professor and coordinator of Trauma and Sport Dentistry at University of Southern California. Thereafter, he joined the University of Washington where he completed his endodontic certificate in 2008 and is currently Professor of Endodontics and Adjunct Professor of Pediatric Dentistry. He is the Director of Endodontics and Traumatology at the Center for Pediatric Dentistry and Seattle Children's Hospital. In 2010, Nestor became a Diplomate of the American Board of Endodontics and received an honorary membership to Omicron Kappa Upsilon Dental Honor Society. He is active in research and teaching, lectures both national and internationally, and has published over 50 peer-reviewed articles.



Peter Day, DDS PhD

University of Leeds
Bradford Salaried Dental Service
Leeds, UK

Presentation: *Evidence Based Dental Traumatology*

Peter qualified from Bristol in 1997. He spent two years in general practice and hospital dentistry in Newcastle and a further year in Bolton as a senior house officer in oral and maxillofacial surgery. He started his specialist and academic training in Pediatric Dentistry in 2000 and has been in Leeds ever since. In 2009 he spent a six month sabbatical working at the Royal Children's Hospital, Melbourne. He returned to England in January 2010 to take up a joint academic appointment with University of Leeds and Bradford salaried dental services.

His PhD was in the field of dental trauma and was completed in 2009. It included chapters investigating the design, development and assessment of a computer database for dental trauma (CDDT); a multi-centre randomized controlled trial of two root canal medicaments for the management of avulsed and replanted teeth and a Cochrane review of the avulsion literature.

He was an author of the latest IADT guidelines on Tooth Avulsion. In dental traumatology, he has contributed to various UK and European guidelines, Cochrane reviews, national e-learning teaching tutorials and 15 peer-reviewed publications. He was elected as an IADT Director in 2012 and is currently chairman of the Research Committee.



Dr. Korkud Demirel, Prof, Dr.
Dental Faculty
Department of Periodontics
Istanbul, Turkey

Presentation: *Periodontal Plastic Surgery in the Treatment of Gingival Traumas*

Dr. Demirel graduated from Istanbul University Faculty of Dentistry in 1985 and completed his PhD in 1992. He was invited as visiting assistant professor in SUNY at Stony Brook, Department of Periodontics in 1989-1990. Awarded as full professor in 2002, and working part time at the department of periodontology at the University of Istanbul, and maintaining his private practice.

His fields of interest are periodontal plastic surgery, guided bone tissue regeneration, and smoking and periodontal diseases.

He is the immediate past president of Turkish Society of Periodontology, past president of European Federation of Periodontology.

He lectures extensively on plastic periodontal and implant surgery, implant treatment in post periodontitis patients and smoking. He has tailored courses on "Soft tissue management" and delivers nationwide and internationally.




Marie Therese Flores, DDS
Professor of Pediatric Dentistry
Director of the Clinic of Pediatric Dentistry and Dental Trauma
Universidad de Valparaiso
Valperaiso, Chile

Presentation: *What is New in the Management of Traumatic Injuries to Primary Teeth?*

Marie Therese Flores is Professor of Pediatric Dentistry and Director of the Clinic of Pediatric Dentistry and Dental Trauma at the Graduate Dental School of the Universidad de Valparaiso, Chile. She served as President of the IADT from 2003 to 2006. She is co-author of the Guidelines for the Management of Traumatic Dental Injuries, published by the IADT in 2001, 2007 and 2012; co-author of the Andreasen's Traumatic Dental Injuries -A Manual- 1st, 2nd and 3rd edition, and has also contributed in three chapters of the Textbook of Traumatic Injuries to the Teeth, 4th ed. She is Associate Editor of the Journal Dental Traumatology. She is an active clinician at the University Clinic, a referral Centre for children and adolescents affected by traumatic dental injuries. Since 2011, she is Program Director of a 300-hour blended online Diploma in Dental Traumatology.

She has developed educational campaigns to raise the awareness on prevention and immediate care of dental trauma. She is co-author of the "Save your Tooth" poster, which is available in eight languages at: www.iadt-dentaltrauma.org. She has lectured extensively, both nationally and internationally on dental trauma. In 2012, she received the IADT recognition for "Outstanding Leadership".



Dr. Michel Goldberg

INSERM U747 (team 5) & Biomédicale des Saints Pères, Université Paris Descartes
Paris, France

Presentation: *Pulp Regeneration and Updates*

Dental surgeon- 1961, Medical Faculty of Paris. Doctor in Dental Sciences - University René Descartes 1973. Doctorat d'Etat ès Sciences Naturelles, University Pierre et Marie Curie 1983. Professor in Oral Biology: University René Descartes. Professeur de catégorie exceptionnelle. Now Professor Emeritus.

Nominated expert in the Working Group on Fluoride (AFSSAPS) 2008. Nominated external expert of the Working Group on the safety of Mercury, SCENIHR, European Commission Bruxelles. Member of the pool of Scientific Advisors on Risk Assessment – European Commission nomination 19 Feb 2009

IADR (International Association for Dental Research):
Continental European Division (CED)/IADR Member since 1973, Member of the CED/IADR Board 1983-2015. Treasurer of the CED-division (2010-2015). President of the CED/IADR (1985-1987), President-elect IADR-CED (1996-1997)- President CED/IADR (1997-1999)- Past-president (1999-2000). President of the Mineralized Tissue Group (elect in 1998-past-president 2001).
President of the Pulp Biology Group IADR 2004, Past-President 2006).

Publications: Author or co-author of 208 scientific papers per-reviewed in dental and non-dental journals, and more than 100 papers published in French journals. Author, co-editor, or author of invited chapters of 19 books. Associated Editor 'Clinical oral Investigation'.



Jan Gottlow is DDS, PhD (Dr Odont)

Certified Periodontist
Associate Professor at Department of Periodontology University of Gothenburg, Sweden

Presentation: *Rehabilitating the Anterior Region with Implants After Trauma*

He has had positions as Associate Professor at Department of Periodontology, University of Gothenburg, Sweden, and at Northwestern University, Chicago, Illinois. During 1989-1998 he worked as Scientific Director at Guidor AB and as Director of Sunstar Inc. Gothenburg Research Center, Sweden. During 1999-2003 he held a position as Chief Scientist Clinical Research at Nobel Biocare, Gothenburg, Sweden. During 2004-2010 he was Associate Professor at the Brånemark Clinic, Public Dental Health Service and Faculty of Odontology, Gothenburg, Sweden. Currently he is Researcher at Dept. of Biomaterials, Institute for Clinical Sciences, University of Gothenburg, and also works in Private Practice. He is a member of the Editorial Board of Clinical Implant Dentistry and Related Research. He has published extensively and is a well-known international lecturer.



Eva Lauridsen, DDS, PhD

Assistant Professor
Department of Pediatric Dentistry and Clinical Genetics School of
Dentistry, University of Copenhagen
Copenhagen, Denmark

Presentations: (1) *Managing Combined Dento-alveolar Injuries*
(2) *Using the Dental Trauma Guide*

Eva graduated from School of Dentistry, University of Copenhagen in 1998. She is currently employed as Assistant Professor at Department of Pediatric Dentistry and Clinical Genetics, School of Dentistry, University of Copenhagen and at the Resource Center for Rare Oral Diseases, Copenhagen University Hospital (Rigshospitalet). For the last five years Eva has been part of the Dental Trauma Guide research group and she has obtained her PhD degree in the field of dental traumatology.



Barbro Malmgren, DDS PhD

Department of Dental Medicine
Pediatric Dentistry
Karolinska Institutet
Stockholm, Sweden

Presentation: *Managing the Alveolar Crest after Ankylosis-alveolar Bone Ridge Preservation*

Barbro graduated 1960 from the Royal School of Dentistry at Karolinska Institutet in Stockholm, Sweden. She became a specialist in Pediatric Dentistry, certified by the Swedish Board of Health and Welfare 1982. During the period from 1983 to 1999 she served as Senior Consultant with responsibility for post-graduate training in Pediatric Dentistry at Eastman Institutet. In 2004 she was promoted Medical Doctor, PhD by Karolinska Institutet, and has a current position as supervisor for PhD-students.

Dr. Malmgren has published numerous scientific articles and written chapters for several textbooks. She has been invited speaker as well in the Scandinavian countries and as in China, Israel, Australia, Brazil, Singapore, the United States, Chile and United Arab Emirates.

She is one of the founders of the International Association of Dental Traumatology (IADT), has been a member of the Board Directors of the organization for several years. She has served as associate editor for the Journal of Dental Traumatology, and has currently a position in the editorial board.



Olle Malmgren, LDS, ODONT DR (PhD)
Orthodontic Clinic Huddinge
Huddinge, Sweden

Presentation: *Orthodontics and Traumatized Teeth- When and How?*

Olle Malmgren was a graduate of the Royal School of Dentistry, Karolinska Institutet, in 1960 and became a specialist in Orthodontics at Karolinska Institutet 1968, certified by the National Board of Health of Welfare; Karolinska Institutet subsequently awarded him Odont Dr (PhD) in 1980 and Docent (Associate Professor) in 1982. He served as an orthodontist at Eastman Institutet in Stockholm, Sweden for 30 years, and was Head of the Institute from 1989 to 2002. He also served as Head of the Orthodontic Department for many years. He has been supervisor for PhD-students resulting in several theses. After retirement from Eastman Institutet in 2002, Dr. Malmgren became Head of an orthodontic clinic in Uppsala, Sweden until 2006 and still holds a position as Consultant for post-graduate training in orthodontics at that clinic until 2012. He has written many scientific articles and participated in writing chapters for several textbooks. Dr. Malmgren has been an invited speaker in many countries and holds a position in the editorial board for the Journal of Dental Traumatology and a member of the Board Directors in the International Association of Dental Traumatology.



Asgeir Sigurdsson, DDS, M.S.
Chairman of the Department of Endodontics
New York University College of Dentistry
New York, NY USA

Presentation: *Endodontic Management of Traumatized Teeth*

Born and raised in Reykjavik, Iceland. Graduated with a dental degree from University of Iceland, Faculty of Dentistry in 1988. After one year in private practice in Iceland, moved to Chapel Hill, NC USA. Graduated from University of North Carolina (UNC) at Chapel Hill, with certificate in endodontics and Master of Science degree in 1992 with emphasis on neurobiology and pain perception.

Full time faculty member at UNC School of Dentistry from 1992 until 2004, first as an assistant professor and then promoted to associate professor with tenure in 2000. Appointed as the Graduate Program Director of Endodontics (specialty training) in 1997 and severed in that position until 2004. From 2004 to 2012 he was in a private endodontic practice in Reykjavik and UK. In fall of 2012 became the Chairman of the Department of Endodontics, New York University College of Dentistry. Additionally holds the following academic positions: From 2004 an adjunct associate professor at UNC, Honorary Clinical Teacher in Endodontology, UCL Eastman Dental Institute, London UK in 2006 and Hong Kong University in 2011

Dr. Sigurdsson is a past President of the International Association for Dental Traumatology.



Mitsuhiro Tsukiboshi, DDS, PhD
Aichi, Japan

Presentation: *Autotransplantation in the Management of Traumatized Dentition*

Dr. Tsukiboshi is a graduate of Osaka University School of Dentistry in 1976. He earned a PhD in dental materials from Kyoto University in 1980 and has been engaged in private practice since 1981. Dr. Tsukiboshi's interest in dental traumatology and autotransplantation has led to extensive clinical involvement, course presentations and publications. Dr. Tsukiboshi has lectured extensively on dental trauma and autotransplantation; he has authored many articles and two textbooks, one on dental trauma in 1998 and one on autotransplantation in 2000. The books have been published in several languages, including English. Dr. Tsukiboshi is a visiting lecturer Loma Linda University since 1998, the President of the International Association of Dental Traumatology in 2009 and 2010, and a adjunctive assistant professor of Western University since 2012.



Dr. Lezize Sebnem Türkün
Professor Doctor in the Department of Restorative Dentistry and Endodontics
Ege University
Izmir, Turkey

Presentation: *Esthetic Considerations after Dental Trauma*

1986-1991: Dental School of Ege University (Izmir / Turkey) 1998: PhD in the Department of Restorative Dentistry and Endodontics of Ege University (Izmir/Turkey)
2004- 2009: Associate Professor in the Department of Restorative Dentistry and Endodontics of Ege University (Izmir/Turkey) 2009-present: Professor Doctor in the Department of Restorative Dentistry and Endodontics of Ege University (Izmir/Turkey)

1991- 2004 : Teaching and research assistant in the Department of Restorative Dentistry and Endodontics of Ege University (Izmir/Turkey)
2004- 2009: Associate Professor in the Department of Restorative Dentistry and Endodontics of Ege University (Izmir/Turkey) 2009-present: Professor Doctor in the Department of Restorative Dentistry and Endodontics of Ege University (Izmir/Turkey) 2005- present : Member of the editorial board of Inter. J Brazilian Dent Clinica 2007-present: Translation editor of the Journal Quintessence Turkey 2009- present: Member of the editorial board of European Journal of Esthetic Dentistry

PRINCIPLE SUBJECTS OF INTEREST

1. Esthetic restorative procedures and treatments
2. Long-term clinical success of resin based esthetic materials in anterior and posterior restorations.
3. New developments in dentin bonding systems.
4. Antibacterial restorative materials and adhesive systems.
5. Finishing and polishing of tooth colored restorative materials.
6. New developments in glass ionomer cements.

*Views expressed by the presenters at the IADT Meeting are solely their own and do not necessarily reflect the positions or policies of the IADT
The IADT reserves the right to cancel or modify its program as circumstances might dictate*

Case Posters- Endodontics & Periodontal Aspects
TREATMENT OF A MULTIDISCIPLINARY CASE OF DENTO-ALVEOLAR TRAUMA: CASE REPORT

Abad, Ernani*, Schwartz, Zuiz: Machado, Andreia: Riberio, Antonio Estacio De Sa
Endodontics
Petropolis, Brazil

Purpose: Research has shown that automobile accidents, extreme sports and fights are the most common causes of dental trauma. In this work, we reported a case of multidisciplinary treatment of oro facial trauma, caused by automobile accident, which needed special care of dentistry, periodontics, endodontics and radiology specialists for treatment.

Methods & Materials: A 23- year-old, male patient had suffered a car accident and his situation was aggravated by the fact that his seat belt had not been fastened . He was taken to a public hospital by the EMT team of firefighters, and there he received first aid procedures. Sixty days after the accident, D.S. sought the "Trauma Project" for treatment. Clinical examination and anamneses were conducted and radiographic examination was requested, including a panoramic and periapical radiography to thoroughly evaluate dental possible damages to bone structures caused by the impact of the crash. The analysis of clinical and radiographic examinations showed the following trauma: coronal-upper central incisors fractures root with pulpal exposure on the palate; coronary fracture of upper lateral incisors without pulpal exposure, however, responding negatively to the tests of pulpal sensitivity; coronary fracture in lower left lateral incisor; root fracture at apical level in lower central incisors; lateral dislocation, towards the upper right canine vestibular. . The first procedure of the treatment was surgical repositioning of the upper right canine followed by placement of a semi-rigid contention using a nylon wire 0.9 and light-cured resin. Such fixation was removed after 15 days of insertion and a clinical enlargement of the crown was made in the palatine region to enable complete isolation of the tooth . After this surgical intervention, the indicated endodontic treatment was conducted in incisors which exhibited spontaneous pain due to pulpal exposure generated by the crown-root fracture. Endodontic treatment of those elements was done in a single session.

Results: In the case of lower maxillary elements, all of them suffered endodontic intervention. As for the lower central incisors, having suffered fractures at the apical third of the root, they were filled until the limit of the fracture considering the fracture fragments vital and non contaminated apice.

Conclusion: The restorative procedures of all damaged anterior elements, were conducted by the dentistry clinic, pins and ceramic cores were used and crowns reconstruction was done with the use of light activated microfilm resins with shades in the specification A varying the cromas correlated color scale VITA.

MANAGEMENT OF COMPLICATIONS AFTER TRAUMATIC INJURIES TO IMMATURE PERMANENT INCISORS

Abukabbos, Halima*
University of Florida
Pediatric Dentistry
Gainesville, FL, United States

Keywords: Intrusion, Extrusion, Apexification

Purpose: The purpose of this case report is to illustrate the emergency, short and long-term management of young permanent maxillary incisors involved with complex luxation-like injuries.

Methods & Materials: Emergency management , orthodontic forced eruption and pulp therapy approaches used with both calcium hydroxide and MTA are described in details. The case was followed-up clinically and radiographically for 5 years.

Results: Clinical and radiographical successful outcomes was noted after 5 years with the evidence of hard tissue formation and good healing process apically.

Conclusion: The management of traumatic injuries to the teeth and soft tissues represent a challenge for dental practitioner requiring knowledge and expertise necessary for adequate diagnosis and treatment.

DENS INVAGINATUS WITH 4 YEARS PERSISTENT INFECTION: CLINICAL APPROACH

**Ahbab, Golgis*, Van Gorp, Gertrude, Declerck, Dominique
KU Leuven**

**Oral Health Sciences, KU Leuven and Paediatric Dentistry and Special Dental Care, University
Hospitals Leuven
Leuven, Flemish Brabant, Belgium**

Purpose: Dens invaginatus (DI) is a developmental anomaly resulting in an invagination of the enamel organ into the dental papilla prior to calcification of dental tissues. Most affected teeth are maxillary lateral incisors. The aetiology remains unclear; there is some evidence for a genetic predisposition. The aim of this case report is to highlight possible complications associated with teeth affected by DI when improperly treated and to illustrate this with a case where apexification resulted in resolution of infection.

Methods & Materials: A 14-year old healthy female presented with a sinus tract at the level of the upper left lateral incisor. She complained of pain and discomfort. Her dentist initiated an endodontic treatment (4 years earlier) because of periodontal abscessation. Because of the open apex; calcium-hydroxide paste was placed in the root canal and replaced several times attempting to perform an apexification. Because of persisting complaints, the patient consulted another dentist who prescribed antibiotics (amoxicillin) and referred the patient for specialized care. At initial examination, radiographic images taken by the former dentist were examined and a Cone-Beam CT (3D Accuitomo, J Morita) was scheduled. These confirmed the diagnosis of DI type II. An extensive infection was visible, resulting from inadequate disinfection and preparation due to lack of knowledge about this developmental anomaly. The portal of entrance of microorganisms to the periodontal ligament and surrounding bone was localized based on the Cone-Beam CT image. An apexification procedure was performed. In a first step, disinfection was obtained by removing calcified tissue using ultrasonic preparation (ET2018, Satelec) and irrigation (NaOCl 2.5%) followed by placement of calcium-hydroxide paste (Ultracal XS, Ultradent) and zinc oxide eugenol cement. Two months afterwards, the portal of entrance was accessed with ultrasonic instruments (K15F43715, Satelec). Mineral Trioxide aggregate (ProRoot MTA, Dentsply) was introduced in the canal, covered with Intermediate Restorative Material (IRM, Dentsply) and a fiber post (Snow post, abrasive technology) was positioned. The tooth was restored using a composite filling.

Results: Clinical and radiological follow up (2 years) showed resolution of infection and complete periapical bone healing.

Conclusion: Teeth with DI are at increased risk of caries development, pulp pathosis and periodontal inflammation. The nature of the problem entails a high level of complexity of necessary endodontic treatment. Knowledge of this developmental anomaly is necessary when dealing with this situation. The case report shows that even in situations with persisting infection, a correct endodontic approach can lead to saving of the tooth.

TITANIUM-PREPARED PLATELET-RICH-FIBRIN (T-PRF): A NOVEL APPROACH FOR TREATMENT OF IMMATURE-TEETH

**Akman, Melek*, Melek Akman, Hale Ari Aydinbelge
Selcuk University Faculty of Dentistry
Department of Endodontics
Konya, Turkey**

Purpose: Regeneration of pulp-dentin complex in an infected necrotic tooth with an open apex is possible if the canal is effectively disinfected. The purpose of this case reports is to introducing new titanium-prepared platelet-rich fibrin (T-PRF) in treatment of immature teeth with necrotic pulp and open apex. Titanium-prepared, platelet-rich fibrin (T-PRF) is a new platelet concentrate, the method of preparation of which is based on the hypothesis that titanium tubes may be more effective at activating platelets than the glass tubes.

Methods & Materials: A 18 years old girl who accidentally broke his immature maxillary central incisor tooth, developed pulpal necrosis with apical periodontitis. After preparing an access cavity, its necrotic pulp was removed. The canal was irrigated with 5.25% NaOCl solution, 0.2% chlorhexidine solution and dried with paper points. A triple antibiotic paste with distilled water was placed inside the canal and left for 21 days. 20 ml of whole blood was drawn from the patient's and centrifuged for 12 minutes to obtain the T-PRF. After the removal of the triple antibiotic paste, the T-PRF was placed into the canal till the level of cemento-enamel junction and 3mm of grey MTA was placed directly over the T-PRF clot. The setting of MTA was confirmed 3 days later and the tooth was double sealed with GIC and Composite restoration.

Results: After 6 months the clinical examination revealed negative responses to percussion and palpation tests. Radiographic examination revealed continued thickening of the dentinal walls, root lengthening, regression of the periapical lesion and apical closure.

Conclusion: On the basis of the results obtained in our case report we conclude that T-PRF is potentially an biomaterial for pulp-dentin complex regeneration.

MANAGEMENT OF LATERAL LUXATION INJURIES AT DIFFERENT LEVELS OF SEVERITY

Aksel, Hacer*, Askerbeyli, Sevinc ; Serper, Ahmet
Hacettepe University, Faculty of Dentistry
Endodontics
Ankara, Turkey

Purpose: Traumatic dental injuries occur frequently in children and adolescents and mostly affect maxillary central incisors. Luxations are the most common types of dental injuries affecting periodontal tissues and the prevalence varies from 15% to 61%. Management of lateral luxation depends on several factors, with the result that various clinical modalities have been suggested. Proper diagnosis, treatment planning and follow up are important for improving a favourable outcome. The diagnosis depends on clinical and radiographic findings. Laterally luxated teeth often have their crowns displaced palatally resulting in considerable injury to the periodontal ligament and alveolar bone. The purpose of this case report is to describe the treatments of different levels of luxation severity in the maxillary incisors of three patients.

Methods & Materials: 17-year-old female, 16 year-old male and 35-year-old male patient came to our department in different time periods. Clinical examination revealed that the maxillary central incisor of the female patient had lateral luxation and concurrent crown fracture. The second patient had maxillary lip bruises and palatally dislocated maxillary left central incisor while the third patient had nasal and maxillary lip bruises as well as laceration of the maxillary labial mucosa and buccal gingiva at the maxillary left central and lateral incisors, which had a lateral luxation. The roots of the maxillary incisors of all patient displaced buccally and the crowns displaced palatally. Treatment involved suture of the soft tissues lacerations, and repositioning and splinting of the injured teeth under local anesthesia. A 3-month-follow-up radiograph showed that maxillary central incisor of the first patient showed apical lesion and the endodontic treatment was performed. Since the second and third patient had a severe pain in the maxillary left central incisors, the root canal treatment were also performed.

Results: After a 1.5-year follow-up, clinical and radiographic evaluation revealed that maxillary incisors presented satisfactory aesthetic and functional demands.

Conclusion: After lateral luxation, immediate reposition and stabilization of teeth in their anatomically correct positions are essential to optimize healing of the periodontal ligament and neurovascular supply, while maintaining aesthetic and functional integrity. The splinting period indicated for periodontal ligament therapy is 2-4 weeks depending on the severity of luxation injury. Pulp necrosis is an important consequence of luxation injuries and its development depends on the type of injury and the stage of root maturation. This case report can guide the clinician to treat this type of dental injury successfully.

INTENTIONAL REPLANTATION AS LAST RESORT: EVALUATION UP TO 17 YEARS

Alpay, Hatice*, Demiralp, Burak, Tepe, I. Durul, Nohutcu, M. Rahime
Hacettepe University
Department of Periodontology
Ankara, Turkey

Keywords: replantation, periodontitis

Purpose: This study evaluated the clinical and radiographic results of the intentional replantation of periodontally involved hopeless teeth after conditioning of root surfaces with tetracycline –HCl. Twenty six periodontally involved hopeless teeth were evaluated. The mean evaluation period was 7,5 years, up to 17 years.

Methods & Materials: During the replantation procedure, the affected teeth were gently extracted, then the granulation tissues, calculus, remaining periodontal ligament and necrotic cementum on the root surfaces were removed. Tetracycline–HCl at a concentration of 100 mg/ml, was applied for 5 min to the root surfaces. The teeth were then replaced into the socket and splinted. Patients were clinically and radiographically evaluated at baseline (time of surgery) and according to their last recall visit.

Results: Two teeth (one upper central and one lower lateral) were survived for 17 years without any complication. Four replanted periodontally involved hopeless teeth in two patients in the lower anterior region, (two in each), were survived for 7 years with bone gain after replantation, replaced by implants. Minimum survival time for these 26 teeth was 3 years. Two teeth had internal resorption. Six teeth were extracted for prosthetic reasons. Others were unfortunately could not be followed after 3 years.

Conclusion: It may be suggested that intentional replantation can be an alternative approach to extraction and can be thought as a last resort where advanced periodontal destruction is present and no other treatments could be considered.

MANAGEMENT OF AVULSED TOOTH AFTER PROLONGED DRY STORAGE

Altun, Ceyhan*, Akgun, Ozlem Marti; Arat Maden, Eda; Basak, Feridun
Gülhane Medical Academy
Department of Pediatric Dentistry
Ankara, Turkey

Purpose: The purpose of this case report is to describe the management of a 14-year old child with an avulsed maxillary permanent incisor that had been air-dried for 2 days.

Methods & Materials: A 14-year-old female patient admitted to the Pediatric Dentistry Department with a history of dental trauma to the maxillary anterior teeth owing to fall. On intraoral examination her right permanent maxillary incisor was avulsed and a blood clot was found in the alveolar socket. Left permanent maxillary incisor had crown fracture. No other oral injury was detected clinically. The avulsed tooth had been left dry in an uncovered plastic container after the injury. Examination of the avulsed tooth revealed that the crown had small fracture and that the root had closed apex, but the root surface was covered with dried remnants of periodontal tissue. It was estimated that the avulsed tooth had been stored completely dry in a paper napkin for 2 days. The necrotic periodontal tissue removed from the root of the avulsed tooth and the tooth was kept in saline for hydration. After careful cleaning of the tooth with gauze soaked in saline, the root of the tooth was treated outside. Followed by pulp removal, the root filled with gutta-perca points and sealer. The tooth was then reimplanted to its socket and splinted to adjacent teeth for 6 weeks. After replantation, postoperative antibiotics and analgesics were prescribed.

Results: The patient was followed for 18 months. During a follow-up examination at 18 months periapical lesion was detected around the root of the left permanent incisor and the endodontic treatment of this tooth was applied at the same appointment. The patient is followed-up for 6 and 12 months postoperatively.

Conclusion: In cases of avulsed permanent tooth with prolonged dry storage-after giving the necessary information to patients and their families- replantation should be performed although the high risk of replacement resorption and tooth loss.

ENDODONTIC TREATMENT OF WIDE OPEN APEX USING MTA: CASE REPORT

Ariker, Idil*, Canbazoglu, Çigdem
Hacettepe University
Endodontics
Ankara, Turkey

Purpose: The aim of this case report is to present endodontic treatment of a maxillary central incisor tooth with wide open apex and necrotic pulpusing with MTA apical plug.

Methods & Materials: A 20-year old male patient with extraoral swelling was referred to our clinic. Patient was non contributory informed us that he had trauma history years ago. Intraoral examination showed that there was an absces at vestibul area and radyographic examination revealed that maxillary right incisor had an unadequate root-canal filling and ineffective composite restorations , open apex and an apical lesion. According retreatment protocol access cavity was opened and drenaige was provided through root canal. Working length was determined with radiographically and root canal was instrumented under NaOCl and CHX irrigation. After 1 week patient was asemptomatic and swelling was healed completely. Root canal was irrigated copious NaOCl and CHX , MTA used as apical plug and a wet cotton pellet was placed in cavity. After 2 days patient called and remaining root canal space obturated with gutta percha.

Results: After 6 months tooth was still asytmomatic, functional and apical lesion healed.

Conclusion: Our result corroborate with previous studies, which showed the healing of such cases.

TREATMENT APPROACHES IN DIFFERENT TYPES OF TRAUMATIC DENTAL INJURIES

Askerbeyli, Sevinc*, Aksel, Hacer; Serper, Ahmet
Hacettepe University Faculty of Dentistry
Department of Endodontics
Ankara, Turkey

Purpose: Traumatic dental injuries (TDIs) are one of the serious public health problems. Dental trauma often has a severe impact on the social and psychological well being of a patient. It is important to immediately restore the function and the aesthetics of the traumatized anterior tooth. The purpose of these case series is to present management of different types of dental traumatic injuries including crown root fracture, extrusion and avulsion.

Methods & Materials: In case-I 35-year-old female patient with a non-contributory medical history was referred for the management of crown-root fracture on tooth #23 due to the physical assault happened 3-months earlier. Clinical examination revealed that the tooth had tenderness to percussion and sensitivity to cold stimulus. Mobility and replacement were not observed. After the completion of root canal treatment, the crown was restored with composite resin. In case-II 21-year-old male patient came to our department with a complaint of axial displacement and retrusion of the tooth #11. Clinical and radiographic examination revealed that the tooth was excessively mobile. The tooth was gently repositioned with axial pressure and was stabilized using resin splint for 2 weeks. In case-III a 16-year-old female patient was referred to our clinic at 2 days after the injury for the treatment of an avulsed tooth #21. The local dentist had already replanted the tooth at 30 minutes after the injury. Normal position of the replanted tooth was clinically and radiographically verified and the resin splint was extended to tooth #22. Antibiotics was administered. Since the patient had severe pain 5 days after replantation, root canal treatment was performed and the replantation splint was removed 2 weeks later.

Results: After average 1-year follow-up radiographs of all patients showed complete healing of periapical tissues, functional tooth and satisfactory esthetic results.

Conclusion: Facial trauma resulting in fractured, displaced, or lost teeth can have significant undesired functional, aesthetic, and psychological effects on patient. Dental injuries could have improved outcomes if the public were aware of first-aid measures and the need to seek immediate treatment. Pulp necrosis is an important consequence of most of the dental injuries and its development depends on the type of injury and the stage of root maturation. Correct diagnose and immediate treatment are essential requirements for a successful treatment of injured permanent teeth.

MANAGEMENT OF INFLAMMATORY ROOT RESORPTION USING BIODENTINE AS ROOT FILLING

Atasever, Gulsum*, Ballikaya, Elif, Unverdi, Gizem, Cehreli, Zafer C.
Hacettepe University
Pediatric Dentistry Dept.
Cankaya, Ankara, Turkey

Keywords: Biodentine, tricalcium silicate cement, inflammatory root resorption

Purpose: Traumatic injuries may lead to inflammatory root resorption. This report presents the endodontic management of trauma-induced inflammatory root resorption involving root canal obturation with Biodentine, a tricalcium silicate cement.

Methods & Materials: Nine late-referred trauma cases with inflammatory root resorption are presented. In all teeth, endodontic access was gained, and calcium hydroxide dressing was placed into the root canal for 3-4 weeks. In the second appointment, the calcium hydroxide dressing was removed, and the tricalcium silicate cement (Biodentine) was packed into the entire root canal. The access cavities were restored by acid-etch resin composite.

Results: Clinically, all teeth have been in function for more than 12 months. Radiographic evidence of periradicular healing and regeneration was observed to varying degrees. None of the teeth exhibited coronal discoloration.

Conclusion: Based on short-term clinical and radiographic observation, Biodentine performed successfully as a root filling material in cases of trauma-induced inflammatory root resorption.

TREATMENT OF TRAUMATIZED YOUNG PERMANENT TEETH WITH LARGE PERIAPICAL LESION

Bal, Cenkhan*
Etimesgut Asker Hastanesi
Ankara, Turkey

Keywords: large periapical lesion,young permanent teeth,trauma

Purpose: The most common pathologic conditions that involve teeth are the periapical lesions, usually composed of solid soft tissue (granulomas) or semisolid, liquefied cystic area (cyst). They are the result of a localized inflammatory reaction to infection within the root canal system reducing mineral density of the affected periapical bone, resulting in resorption identified as radiolucencies in radiographs. It is essential to correctly diagnose these lesions as the choice of treatment is dependent on it. Root canal therapy is accepted as the most effective conservative method for treating periapical lesions. Periapical granuloma may heal without surgical treatment if given the opportunity; however, sometimes it may require surgical removal. In this report there are 3 cases. Whole the cases are traumatized young permanent teeth with large periapical lesions which are treated by only root canal therapy and follow-up at least one year with radiography.

Methods & Materials: Case 1: A 11-year-old female patient reported with trauma two years ago at upper left lateral incisor area. According to intraoral clinical examination discolouration and luxation was observed at tooth 22. Periapical radiograph showed large periapical radiolucency around tooth 22 periapical region. Root canal treatment had done to tooth 22 and follow-up had done with periapical radiography. Case 2: A 13-year-old male patient who had visited our clinic for ortodontic treatment. Clinical examination of soft tissues showed signs of fistulae at teeth 11 and 12 area. Periapical radiographs had shown large periapical lesions around apicies of 11 and 12. Root canal treatment had done to teeth 11 and 12 and follow-up had done with periapical radiography. Case 3: A 12-year-old female patient who had sometimes had mild pain but no swelling in the mandibular anterior region. The patient stated that she had slide accident at park area 4 years ago and had not visited a dentist since had no pain or swelling after that time. Periapical radiography had shown large radiolucent lesion around apicies of the mandibular incisors. Root canal treatment had done to teeth 31,32,41 and 42 and follow-up had done with periapical radiography.

Results: We observed bone healing at periapical lesion area without any surgical treatment.

Conclusion: Whole the three cases showed good bone healing at periapical lesion area according to radiography follow-up without any additional surgical treatments.

MANAGEMENT OF THE FRACTURED PRIMARY MOLARS: A 36-MONTH FOLLOW UP

Baldag, Ilknur Azime*, Çinar, Çagdas, Odabas, Mesut Enes.
Gazi University Faculty of Dentistry
Pediatric Dentistry
Ankara, Turkey

Keywords: posterior trauma,primary molars,dental injuries

Purpose: Crown and crown-root fractures in primary molars are rare. These fractures usually occur as a result of trauma to the chin. Treatment of the fractured teeth depends on the severity and position of the fracture line as well as the length of time that has passed between accident and treatment. The aim of the present report was to discuss the diagnosis, treatment and a 36 month follow-up of a case of complicated crown-root and uncomplicated crown fractures in second primary molars of a 5-year old boy.

Methods & Materials: A 5-year-old boy was brought by his mother to the Pediatric Dentistry Clinic of Gazi University because he has complaining of pain in his mandibular posterior teeth region. History revealed that he had fallen two months before while playing. Extra-oral examination demonstrated a healing laceration on the chin. Radiographic examination showed the presence of complicated crown-root fracture of the right mandibular second primary molar and uncomplicated crown fracture of the left mandibular second primary molar. After special removal of the fractured cusp, pulpectomy treatment applied both primary molars.

Results: Patient was reviewed after 3, 6, 12, 24 and 36 months both radiographically and clinically.

Conclusion: Though it was found that the obturation material was resorbed completely at 24 month visit, the patient was asymptomatic.

PLATELET RICH PLASMA IN TREATMENT OF TRAUMATIZED IMMATURE PERMANENT TOOTH

Basak, Feridun*, Yildirim, Ceren; Akgun, Ozlem Marti; Guven Polat, Günseli
Gülhane Medical Academy
Department of Pediatric Dentistry
Ankara, Turkey

Purpose: The purpose of this case report is to present the treatment of traumatized immature permanent tooth which was treated with a regenerative approach by using platelet rich plasma (PRP).

Methods & Materials: A 9-year-old female patient was referred to the Pediatric Dentistry Department with a history of dento-alveolar trauma to the maxillary right anterior teeth due to falling 2 h before. Clinical examination revealed subluxation of both maxillary central incisor teeth. Periapical radiograph showed that the teeth had open apices. The teeth were splinted with semi-rigid splint. Ten days later the splint was removed. During a follow-up examination at 6 months the patient had pain in her right maxillary central incisor tooth. Negative responses to both an electric pulp test and a vitality test were recorded for this tooth. It was decided that the PRP procedure was appropriate in this case. The procedure was explained to the parents and informed consent was obtained. Under local anesthesia and rubber dam isolation, an access cavity was prepared and the root canal was irrigated copiously but gently with 2.5% NaOCl. Instrumentation was not performed and the canal was dried with paper points, and then filled with a paste of ciprofloxacin, metronidazole, and tetracycline. The access cavity was closed with glass ionomer cement. The antibacterial paste was changed every 2 weeks until the tooth was asymptomatic. Two months later the canal appeared clean and dry, and PRP was prepared as described above and placed in the root canal. MTA was carefully placed over the PRP. The access cavity was sealed with wet cotton pellet and glass ionomer cement. Finally, the dental restoration was completed with a bonded resin restoration. At the 2-month recall, the tooth was asymptomatic, with no signs of the sinus tract. The radiograph showed resolution of the radiolucency.

Results: The patient is followed-up for 6, 12 and 18 months postoperatively. Eighteen months after treatment the root of the tooth completely formed.

Conclusion: PRP is a very effective preparation for use in regenerative endodontic therapies. Additionally, positive results can be obtained in a very short time.

PARTIAL AND TOTAL PULPOTOMY IN TREATING TRAUMA FOR VITALITY PRESERVATION

Belcheva, Ani*, Tarpomanov Yordan
Medical University, Faculty of Dental Medicine, Plovdiv, Bulgaria
Pediatric Dentistry
Plovdiv, Bulgaria

Purpose: Dental traumas in children cause both physical and psychological discomfort. They are concomitant with pain, failure in function and esthetics. Preservation of teeth's vitality is essential for the successful healing of traumatized teeth. The aim of the study is to present four clinical cases of children with trauma treated with partial and total pulpotomy for pulp vitality preservation.

Methods & Materials: Cases design: The first case was a 7 years old girl with complicated trauma to the first permanent teeth. The exposed pulp was treated according the protocol for partial pulpotomy and covered with MTA. The teeth were reconstructed with fragment reattachment. The second case represented 13 years old boy with fractured 11 and 21 teeth and exposed pulps. A total pulpotomy was performed using MTA. The original fragment of the tooth was reattached to tooth 21 and composite resin build-up to tooth 11. The third case was an 11 years old boy with complicated crown fracture of 21. Treatment included partial pulpotomy with MTA and restoration. The fourth case was an 8 years old boy with uncomplicated fractured of 31 and fracture and pulp exposure of 32. Total pulpotomy and reconstructed with composite resin restorations was established. All the cases were followed-up regularly for 2 years.

Results: One of the teeth was reconstructed on the 18-th month because the boy suffered a new trauma. Tooth vitality of all the cases was preserve for the examined period.

Conclusion: Partial and total pulpotomy are successful methods for pulp vitality preservation in both mature and immature teeth.

FOLLOW-UP OF HORIZONTAL ROOT FRACTURE TREATMENTS: EIGHT CASES

Borbay Akgül, Sevil*, Kahraman, Kamil; Gezgin, Onur; Bag, Irem; Botsali, Murat Selim & Tosun, Gül & Yildirim, Sibel

Selçuk University, Faculty of Dentistry

Department of Pedodontics

Konya, Turkey

Purpose: Root fractures in permanent teeth are uncommon injuries among dental traumas, being only 0.5-7% of the cases. The treatment and prognosis of root fractures depend on many variables. The most important ones are the time between trauma and treatment, degree of dislocation, location of the fracture line, fixation period, stage of root development, and quality of treatment. The principle of treating horizontal root fractures of permanent teeth is repositioning and fixation of fractured segment. Diagnosis of tooth fractures based on radiographic findings and the fracture healing process are affected by factors before and after injury. The aim of this case report is to present 7 different patients who had horizontal root fractures of permanent teeth treated by repositioning and fixation with good healing.

Methods & Materials: This case report presents the treatment of horizontal root fracture located at the middle third, apical third and cervical third of maxillary central incisors of total eight teeth. Three of root fractures are in middle third and, the other three of root fractures are in apical third and one of root fracture is in cervical third. The age of these patients ranged from 7 to 11 and the sample consisted of 7 traumatized children who had a total of 8 root fractured teeth. Teeth were repositioned and stabilized with a stainless steel wire splint. Splints were retained about 4-12 weeks. The vitality of these teeth is lost and these teeth treated with root canal treatment. One of these teeth with open apex has maintained its vitality and root development continued. After splints were removed, patients were scheduled for follow-up visits at every 3-month intervals.

Results: After long-term clinical and radiographical follow-ups, the patients reported absence of any painful symptoms and the tooth had normal mobility. Cases were followed for 8 months-2.5 years and good healing was observed.

Conclusion: The treatment of root fracture may be a painstaking job for both dentists and patients. Therefore, an evidence-based clinical approach should be followed for the successful treatment of root fractures. The clinician should have a thorough knowledge of aetiological cause of fracture, classic signs and symptoms of fracture, availability and applicability of diagnostic methods, differential diagnosis, and factors determining the prognosis, so as to arrive at an appropriate diagnosis and design a suitable treatment protocol.

TREATMENT OF A HORIZONTAL ROOT FRACTURE: STORY OF 2 YEARS

Çanakçı, Burhan Can*, Dinçer, Asiye Nur. Er, Özgür

Erciyes University, Faculty of Dentistry

Department of Endodontics

Kayseri, Turkey

Purpose: Dentoalveolar traumas occur more frequently in young patients and most affected teeth are maxillary incisors. Horizontal root fractures in permanent dentition have been reported to occur in 0.2–7% of all traumatic dental injuries. The following case report describes the treatment of a maxillary central incisor with horizontal root fractures including a root canal treatment (RCT) and surgical approach.

Methods & Materials: A 14-year-old boy was referred to our clinic with the complaint of fractured tooth 9 days after the accident. Intra-oral examination was required and enamel – dentin fracture was determined in maxillary right central and lateral incisor. In radiological examination, horizontal root fracture was determined in the middle third of central incisor. Teeth showed response to electrical pulp testing (EPT) and were sensible to percussion test. Occlusal reduction and semi-rigid splinting was performed for two weeks. Teeth showed continued response to EPT when splint was removed. After 2 weeks from removal of splint, patient referred with spontaneous pain from central incisor tooth. Tooth was devital and highly tender to percussion. RCT was performed and CaOH₂ was placed into root canal. After 4 weeks, a periodontal abscess and a sinus tract was determined at the buccal mucosa from the root fracture level. 10 mm periodontal pocket was determined from the palatal side of the tooth. An antibiotic (Metranizadol) was prescribed by a periodontologist for the periodontal infection. After 5 weeks periodontal abscess, sinus tract and periodontal pocket was healed and teeth were asymptomatic. Root canal of central incisor was filled with gutta percha and AH-plus with cold lateral compaction technique. After 3 weeks there was a periodontal abscess and sinus tract at the buccal mucosa from the fracture level again. Apical portion of the root was removed surgically. And the teeth were splinted semi-rigidly for 6 weeks. After removal of splint the tooth was asymptomatic and mobility of 11 was in physiologic limits.

Results: After 14 months of follow-up from surgical treatment, by the results of clinical examination including the evaluation of mobility, the presence or absence of tenderness and pain to palpation of the soft tissues, percussion of the teeth and pulp testing, and radiographic examination no problems were detected.

Conclusion: This case illustrates that a tooth with horizontal root fracture can be managed with nonsurgical endodontic treatment or surgical endodontic treatment.

CLINICAL MANAGEMENT OF COMBINED DENTAL TRAUMATIC INJURY: A CASE REPORT

Canbazoglu, Çigdem*, Özçelik, Bahar
Hacettepe University
Endodontic Department
Ankara, Turkey

Purpose: Lateral luxation is one of the most prevalent dental injuries among the general population, resulting in up to 27% of all dental wounds. All physical activities have an associated risk of orofacial injuries due to falls, collisions, and contact with hard surfaces. The aim of this study is management of a lateral luxative central incisor tooth caused by a snow accident.

Methods & Materials: A 22-year-old female patient was referred to Department of Endodontics with a history of dental trauma and continues pain of the traumatised teeth. Intra-oral examination revealed that the left central incisor was fractured in incisal edge of the crown, involving enamel and dentin without pulp exposure, right lateral incisor had complicated crown fracture in the cervical segment, there was a significant damage to the crown of the tooth. The right central incisor was replaced to palatally. Radiographic examination showed that there was no root fracture and right central incisor's periodontal ligament space was enlarged and electric pulp testing (EPT) revealed that the #11 and #21 was vital. In the left central incisor, the tooth was restored aesthetically and taken under control after 3, 6 and 12 months both radiographically and clinically. The amount of visible coronal part of right lateral incisor was poor. Crown was restored with composite, the pulp was removed and then Ca(OH)₂ paste was placed as medicament for 2 weeks. The right central incisor was replaced into its original anatomic position immediately, then restored with composite resin and splinted. After 2 weeks, root canal treatment of right lateral incisor was performed and the splint was removed. After completing the endodontic procedure, restorative and aesthetic treatment was performed. The tooth was restored with a post-core system and composite resin.

Results: Patient was reviewed after 3, 6 and 12 months both radiographically and clinically. The patient is asymptomatic until now (after 15 months). The patient is still under review.

Conclusion: The need for a multidisciplinary approach in the treatment of dental traumas has been recognized. After trauma the pulp may be necrotic or root resorption may occur so tooth must be under control.

UNTREATED TRANSVERSE ROOT FRACTURED, ONE RADIOGRAPHIC FINDING.

Cardenas, Javier*, Claveria, Magdalena
Puerto Montt, Puerto Montt, Chile

Purpose: The objective is to report a case of an untreated transverse root fracture which happened 37 years ago, with healing occurring within the interposition of the connective tissue. Highlight the importance of dental check and the dentist has the necessary knowledge.

Methods & Materials: In 2010 a female aged 49 was referred for endodontics treatment of a tooth 1.2. A periapical radiograph observed loose continuity on the radicular surface of the tooth 2.1. Asked about a dental trauma, the patient said: "When I was 12 years old I suffered an impact to the tooth playing sport, but never consulted a dentist". The tooth was asymptomatic, radiographic examination showed a transverse in middle of radicular portion, a rounding of the periphery of the fractured surfaces and no obvious periradicular pathosis. This tooth has been 37 years without complications.

Results: The tooth is asymptomatic with decoloration, minimal coronal mobility, but there were no complications for patient. It had been controlled without complications.

Conclusion: It is very important to make a good examination, it is common that patients do not consult a dentist after dental trauma because they do not know the implications. The dentist must have knowledge about root fractures and the importance of control over time. Often it is not necessary to do some kind of treatment, but just keep it under control. Healing over time occurs.

CONSERVATIVE MANAGEMENT OF INVASIVE CERVICAL RESORPTION AFTER LUXATION INJURY

Cehreli, Zafer*, Unverdi, Erbas Gizem
Hacettepe University
Pediatric Dentistry
Ankara, Ankara, Turkey

Keywords: root resorption, luxation

Purpose: This case report presents the management of two maxillary permanent central incisors after severe luxation injury and the minimally-invasive treatment approach of cervical resorption in an affected tooth.

Methods & Materials: A 16 year-old patient was referred to the clinic one day after a traffic accident. Clinical and radiographic examination revealed complicated crown fracture of the left maxillary central incisor and extrusive luxation of the right maxillary central incisor with palatal displacement. The left incisor was treated with partial pulpotomy using calcium hydroxide, and temporarily restored with glass ionomer cement. Following repositioning of right central incisor, teeth were secured with a semi-rigid splint for four weeks. During the splinting period, intracanal calcium hydroxide was placed in the extruded tooth for two weeks, followed by root canal obturation with gutta-percha and sealer. Both teeth were restored with acid-etch composite resin after splint removal. Complete periradicular healing was observed after 3 months.

Results: Following an uneventful recall period of three years, the right central incisor presented with radiographic evidence of invasive cervical resorption. Based on clinical and radiographic evaluation of lesion borders, a non-surgical treatment approach was planned. A rubber dam was secured subgingivally with the aid of ligatures, retraction cord and teflon. Following excavation of the lesion, the cavity was restored with acid-etch resin composite.

Conclusion: Invasive cervical resorption is a relatively uncommon form of external root resorption that may develop after severe luxation injuries. In selected cases, strict isolation procedures may facilitate management of the lesion by non-surgical, minimally-invasive restorative techniques.

IS THE PARTIAL PULPOTOMY REALLY SUCCESSFUL IN COMPLICATED CROWN FRACTURE?

Ceyhan, Derya*, Kirzioglu, Zuhul
Faculty of Dentistry, Suleyman Demirel University
Department of Pediatric Dentistry
Isparta, Turkey

Keywords: partial pulpotomy, complicated crown fracture, young permanent teeth

Purpose: A crown fracture involving enamel, dentine and pulp is defined as complicated crown fracture and it presents a challenge in treatment, especially in children. The most of these injuries occur in recently erupted or in young permanent teeth with immature roots, and therefore the treatment in complicated crown fracture is oriented towards maintaining the pulpal function and vitality. The partial pulpotomy, also known as Cvek pulpotomy, have been described as a valuable treatment choice for the complicated crown fracture in young permanent teeth when the size of pulpal exposure was large or the time between the accident and the emergency treatment was long. After all, limited information concerning the long term effects of the partial pulpotomy is available in the accessible databases. This paper presents a 8-year and a 7-year follow-up of partial pulpotomy treatment of two patients with complicated crown fracture.

Methods & Materials: A healthy 10-year-old girl and 10-year-old boy attended to our clinic 1 day and 2 days after falling, respectively. The female patient in whom vital right permanent maxillary central incisor tooth with complicated crown fracture and the male patient in whom vital left permanent maxillary central incisor tooth with complicated crown fracture were treated by partial pulpotomy with calcium hydroxide in order to achieve apexogenesis. The teeth were sealed with zinc-oxide eugenol cement and glass-ionomer cement before restoring with composite resin. On the other hand, the male patient's other permanent maxillary central incisor tooth with crown fracture was devital and it was treated by root canal treatment and restored with composite resin. The girl and boy were reviewed clinically and radiographically for 8 and 7 years, respectively.

Results: The teeth treated by partial pulpotomy were clinically symptomless, normal coloured, and had positive response to electric pulp testing, and showed dentine bridge and continued root development on radiographs. However, restricted pulpal obliteration was observed on both of the teeth.

Conclusion: The long-term observations of the complicated crown fractured teeth treated by partial pulpotomy show that this technique can be a successful permanent treatment. At the same time, the degree of the pulpal obliteration should be considered and the required approach should be performed at the right time. This can be achieved by long term follow up of the traumatized teeth.

ACUTE TREATMENT OF AN EXTRUSIVE LUXATION INJURY: A CASE REPORT

Çiçek, Ersan*, Koçak, Mustafa Murat
Bülent Ecevit University, Faculty of Dentistry
Endodontics
Zonguldak, Turkey

Keywords: Extrusive luxation, alveolar process, trauma

Purpose: Extrusive luxations (of both, upper and lower incisors) represent a frequent event in dental traumatology. Pulp necrosis is a common sequel to extrusive luxation in mature teeth. This case report presents a severe fracture of the left maxillary anterior alveolar process with substantial bone dislodgement associated with extrusive and luxation teeth .

Methods & Materials: A 35-year-old female with severe dentoalveolar trauma to the left maxillary anterior region as a result of a home accident/fall was provided emergency treatment consisting of reduction of the dislodged labial cortical bone repositioning of the left central and lateral incisors. After repositioning a stabilization splint was applied from #13 to #23. After 2 weeks, the splint was removed. In vitality test, the traumatized teeth presented with pulpal necrosis and were treated endodontically. After 12 months of follow up, the fracture of the alveolar process was completely healed and the displaced teeth presented no signs of ankylosis or root resorption.

Results: After 12 months of follow up, the fracture of the alveolar process was completely healed and the displaced teeth presented no signs of ankylosis or root resorption.

Conclusion: First –aid care contributed remarkably to this case allowing the re-establishment of esthetics, function and patient’s self-esteem. In spite of trauma extension the treatment outcomes were favorable.

MANAGEMENT OF A DENTAL TRAUMA WITH AVULSION AND EXTRUSIVE LUXATION

Çolakoglu, Münip*, Yazicioglu, Oktay. Karagöz-Küçükay, Isil.
Istanbul University, Faculty of Dentistry
Department of Endodontics
Istanbul, Turkey

Keywords: extrusive luxation, avulsion, fiber-reinforced composite

Purpose: To present the management of a dental trauma with avulsion and extrusive luxation in permanent teeth caused by an epileptic-seizure.

Methods & Materials: A 15-year-old female referred to endodontic clinic of Faculty of Dentistry, Istanbul University, 5 hours after having fallen in the street during an epileptic-seizure. The patient presented with abrasions on the nose, chin and skin surfaces of the lips. Her lower lip was swallowed and contused, severe laceration splitting the lower lip was sutured in the hospital emergency-department. Maxillary left central incisor (tooth 21) was avulsed and could not be found. Clinical examination showed extrusion of maxillary right central incisor (tooth 11) and an enamel fracture on the mesial-corner of maxillary right lateral incisor (tooth 12). Radiographic examination confirmed loss of tooth 21, and an increased periodontal ligament space apically for tooth 11. Except for tooth 11, none of the anterior teeth showed mobility or tenderness to percussion or responded negatively to sensibility tests. Tooth 11 was inserted into its socket using gentle finger pressure, and a passive-splint extending to maxillary right canine (tooth 13) was applied for 3 weeks. Enamel fracture of tooth 12 was restored with glass-ionomer cement. After 3 weeks, splint was removed and healing of the contused socket area was observed. Tooth 11 responded to mobility, percussion and sensibility tests within normal limits. Since a single implant or a conventional fixed-bridge are unsuitable in this age, the missing tooth 21 was replaced with fiber-reinforced composite extending from tooth 12 to tooth 23.

Results: The patient is pleased with her esthetic appearance, and clinical and radiographic follow-up over 12-months showed satisfactory results.

Conclusion: Epilepsy patients, related to falls during epileptic-seizures, present special risks with regard to facio-dental injuries. Severe dental injuries may cause permanent loss of teeth. Replacement of missing teeth is challenging in children and adolescents. Fiber-reinforced composites may be successfully used to provisionally restore esthetics of incisors in growing individuals. The patient is scheduled for further follow-up.

MULTIPLE APPROACH IN DENTAL TRAUMA – A CASE REPORT

Cortes Antonieta, Machado, Andreia; Abad, Ernani; Schwartz, Luiz; Favieri, Amauri
Estacio De Sa
Endodontics
Rio De Janeiro, Brazil

Purpose: The objective of this work was to emphasize the plurality of interventions and technical care, with scientific bases for the completion of cases of dental trauma.

Methods & Materials: Eighteen-year-old patient, ESB, suffered a car accident in September 2013. In this accident, elements 21 and 22 suffered fractures class IV, with pulpal exposure in both elements. As the dental elements presented vitality, an endodontic treatment in single session was chosen. For the mechanical chemical preparation the crown down technique was used and for the filling, the lateral condensation technique was done with Endodontic Sealer 26 epoxy cement - Dentsply Brazil. In this same occasion (consultation) the need to perform a gingival crown lengthening of the element 22 was diagnosed, due to a fracture on the vestibular enamel, with subgingival extension and to tailor the gingival aesthetics when compared with the corresponding tooth (element 12). An internal bevel incision was performed, restricted to face 22 element, and vestibular incision intrasulcular extending to neighbouring elements. A full thickness flap was shifted, surpassing the mucogingival line. The distance from the end of the fracture to the bone crest was noted and it was found the need for a small osteotomy to adequate biological space. Following the gingival crown lengthening a fiber glass post was proven and cemented on the element 22, type Whitepost DC (number 1), with absolute isolation and total seal of fluids with the use of light-cured insulation Top Dam. Restorations were made with light-cured resin (resin Opalis-colors EA1 and DA2), in trans-surgical. The total time spent between the beginning of the Endodontic procedures and restorative finalization was five hours. There was no need for a second appointment except for the removal of sutures and polishing of restorations.

Results: The case presented showed that when it is necessary to achieve aesthetic excellence and biological function, the commitment of specialists in the disciplines of endodontics, periodontics and restorative dentistry is demanded in a single appointment.

Conclusion: Multidisciplinary treatment is necessary in the majority of dental trauma cases received in our institution.

CONSERVATIVE MANAGEMENT OF AN UNUSUAL CASE OF CERVICAL ROOT FRACTURE

Cuitiño, David*, Bravo, Fabiola
PATAGONIA DENTAL CLINIC
Punta Arenas, Magallanes, Chile

Purpose: This case report describes successful long-term conservative management of cervical root fracture in maxillary left central incisor which suffered a second cervical root fracture with displacement 3.5 years later.

Methods & Materials: A 27-year-old man fall and hit his mouth against a table. He was referred to our clinic 5 months after the trauma. None treatment had been done. Due to slight mobility a semirigid splint was performed for 4 months. The incisor remained asymptomatic throughout the 3.5 years of a review period, with the cervical root fracture having mostly healed with the formation of a calcified tissue between the fragments. Then, as consequence of a fight, the patient asked for evaluation 48 hrs. later, a new cervical root fracture, with displacement and transient crown discoloration, was diagnosed in 21. Once crown was reduced the same protocol was performed.

Results: 1.5 years after the second trauma (5 years of follow up), the pulpar and periodontal healing was uneventful.

Conclusion: It is concluded within the limitations of this case report, that conservative approach in teeth suffering cervical root fractures in different periods of time, even with displacement, can be a successful treatment modality.

MANAGEMENT OF CERVICAL EXTERNAL ROOT RESORPTION WITH MINERAL TRIOXIDE AGGREGATE

Dik, Çigdem*, Uzunoglu, Emel; Uyanik, Özgür ; Nagas, Emre
Hacettepe University Faculty of Dentistry
Dept of Endodontics
Ankara, Turkey

Keywords: Root resorption, Mineral trioxide aggregate

Purpose: Cervical external root resorption is entirely uncommon entities and the etiology is poorly understood. Moreover, cervical external root resorption has been considered a difficult clinical situation, and its diagnosis and treatment of the defect challenging.

Methods & Materials: The present report describes a case of external cervical resorption lesion. Both 17-year-old male and 28- year-old female were referred to the Endodontics Department for evaluation of tooth #12. Radiographic examination revealed irregular radiolucency over the coronal third. On the basis of clinical and radiographic findings, a diagnosis of cervical external root resorption was made for both of cases. The treatments included surgical intervention and restoration of the defect by using Mineral trioxide aggregate (MTA) without root canal treatment.

Results: A 6-month re-evaluation of the cases confirmed a stable, uneventful clinical recovery.

Conclusion: MTA can be used securely in the management of cervical external root resorption.

MANAGEMENT OF EXTRUSIVE AND LATERAL LUXATIONS: TWO CASE REPORTS

Dinc, Volkan*, Çiçek, Emre* Keçeci, Diljin* Uyanik, Gözde*
Suleyman Demirel University
Endodontics Periodontology
Isparta, Turkey

Purpose: The purpose of these case reports are to present multidisciplinary approach to the trauma including extrusive and lateral luxations in two patients.

Methods & Materials: In the first case, 19-year-old woman attended to our clinic due to impact to anterior upper jaw caused by slipping in bathroom. In clinical examination; soft tissue injury with pain, redness, swelling with bleeding and lateral-extrusive luxation of upper central tooth were observed. In the second case, 47-year-old woman who had chronic periodontitis attended to our clinic with a history of trauma to upper jaw. In clinical examination; pain and leaky bleeding were observed related to the upper left central tooth. It's probe deep was 7 mm in mesiobuccal and distobuccal sides. Radiographically, a horizontal fracture in the apical third of the root and an initial root resorption was observed. The tooth was mobile in grade III and displaced partially out of the alveolar socket. In both of the cases; after repositioning the teeth, semi-rigid splint was applied, root canal preparation and one week calcium hydroxide medication were performed. Root canals were obturated using gutta-percha and Sealapex. In second case, the tooth was still mobile in grade II so that permanent splint was applied, also subgingival curattage was performed in distobuccal and mesiobuccal periodontal pockets.

Results: Follow up controls were done six months later. In the first case there was no resorption or pain, however the tooth was still mobile in grade I. In the second case, there was no pain. A marginal bone regeneration was observed radiographically.

Conclusion: In trauma cases with lateral and/or extrusive luxations, multidisciplinary approach with endodontic and periodontal management can be necessary and successful, however long term follow-ups will be more reliable in terms of bone loss and/or resorption.

TREATMENT OF A SUBGINGIVALLY FRACTURED TOOTH WITH IMMEDIATE SURGICAL EXTRUSION

Dinçer, Asiye Nur*, Çanakçı, Burhan Can. Akpek, Firdevs. Er, Özgür
Erciyes University, Faculty of Dentistry
Department of Endodontics
Kayseri, Turkey

Purpose: This report presents a case of intrusive luxation of maxillary lateral incisor with crown-root fractures. The intruded teeth were repositioned with surgical extrusion and endodontically treated.

Methods & Materials: A 35-year-old woman was referred to our clinic with the complaint of fractured tooth, 16 hours after the accident. By the results of clinical and radiographic examinations, it was determined that maxillary right lateral incisor tooth was fractured from enamel-cement junction obliquely deeper to the palatal side, remaining root structure was luxated buccally and distally, and tooth was markedly intruded. Lateral incisor was sensitive to the percussion. After local anesthesia, luxation and extrusion was performed by the operators but lateral tooth could not be located in right position, because of this, a mucoperiosteal flap from maxillary left incisor tooth to maxillary right canine tooth was reflected. Lateral tooth was located in right position and splinted semi-rigidly. Root canal treatment was performed and CaOH₂ was placed into root canal. After 3 weeks, splints were removed and root canal of lateral tooth was filled with gutta percha and AH-plus with cold lateral compaction technique and a fiber post was placed into root canal and composite core was built. The patient was directed for prosthodontic treatment.

Results: After 6 months of follow-up, by the results of clinical examination including the evaluation of mobility, the presence or absence of tenderness and pain to palpation of the soft tissues, percussion of the teeth and pulp testing, and radiographic examination, no problems were detected.

Conclusion: Intruded teeth with crown-root fractures can be treated by surgical extrusion successfully, but more follow-up time required for final success evaluation.

RETROGRADE ANTIBIOTIC INFILTRATION OF IMMATURE PERMANENT TEETH BEFORE REPLANTATION

Ebeleseder, Kurt*
University Dental Clinic
Department of Conservative Dentistry
Graz, Austria

Purpose: Replanted immature permanent teeth have a low rate of revascularization (30%). Soaking the teeth in Tetracycline solution before replantation has been found to increase the rate of revascularization. Filling the root canal with triple antibiotic paste has been shown to make revascularization possible even after endodontic infection. The result of soaking an avulsed tooth is a passive exchange of fluids by diffusion in the apical region. Active infiltration may increase the fluid exchange and thus the dose of antibiotics in the necrotic pulp, resulting in an increased revascularization rate.

Methods & Materials: Nine immature avulsed permanent teeth in seven patients were infiltrated actively (= with pressure) through the apical foramen with an antibiotic solution (Baneocin® by Sandoz GmbH, Kundl, Austria, containing Bacitracin and Neomycine) before replantation. The tip of the infiltration needle (size: 0,40mm = 27G) was placed as coronally as possible.

Results: In all nine teeth, during infiltration fiber-like blood clots and other blood remnants became visible which had been washed out of the vessels and thus were replaced actively by the antibiotic solution. During 3 – 19 months of observation and irrespective of ankylosis all nine teeth showed absence of infection-related root resorption, and some of them narrowing of the root canal or ingrowth of alveolar bone.

Conclusion: Retrograde antibiotic infiltration of the necrotic pulp may help preventing pulp infection and thus promote ingrowth of new tissue into the pulp space of immature replanted permanent teeth.

FREQUENT TRAUMATIC INJURIES EFFECT THE PROGNOSIS

Ergin, Ecem*, Vardar Gürlek, Ceren ; Eden, Ece
Ege University Faculty of Dentistry
Pedodontics
Izmir, Turkey

Keywords: Horizontal root fracture, MTA, frequent trauma

Purpose: Traumatic injuries occur frequently in anterior teeth and it is one of the emergency dental problems. The root fractures are relatively uncommon. Root fractures constitute 0.5 to 7% of injuries in the permanent dentition. Fracture occurs most often in the middle-third of the root and rarely at the apical-third. The purpose of this case report is to present the effect of frequent injuries on the prognosis of a tooth with horizontal root fracture.

Methods & Materials: 12-year-old male patient applied to our clinic with dental trauma on his maxillary incisors. He applied to the clinic within 2 days. Intraoral examination revealed that right upper central incisor tooth was showing luxation and left upper central incisor had a complicated crown fracture. Periapical radiography was taken for root and bone assessment and middle third root fracture was diagnosed at right upper central incisor tooth with a closed apex. Under local anesthesia the coronal segment of the tooth was repositioned and fixated with a wire-composite splint. Root canal treatment was planned for both root fragments since it was possible to pass through the fracture line. Upper left central incisor was extirpated as well and calcium hydroxide dressing was applied for both central incisors. Ten days later, he came our clinic again with a secondary trauma where the splint has been broken. Radiologic evaluation revealed that the root fragments were separated. The splint has been renovated and repositioned as possible. But again after ten days, because of a new trauma situation, prognosis has worsened. Splint was reapplied but it was not possible to apply a root canal treatment for both root fragments anymore. Therefore, fracture line was clogged with MTA and the coronal segment was filled with Gutta Perca cones. Root canal treatment was applied for upper left central incisor and restored with fiber post and a composite resin.

Results: The tooth was followed up to 1 year where the treated teeth were functionally and esthetically acceptable, suggesting that the treatment was successful.

Conclusion: Patient attitude is important for determining post-traumatic treatment protocols and implementation. Repetitive traumatic injuries and poor oral hygiene affects the prognosis adversely.

REPOSITION OF AVULSION AND LUXATION AFTER 72 HOURS

Gatón Hernández, Patricia*, Ruiz_De_Castañeda Esther**, Bezerra Da Silva Raquel***,
Nelson-Filho P***, Bezerra Da Silva LA***
University of Barcelona* Catalonia Academy of Medical Science** University of Sao Paulo***
Barcelona, Barcelona, Spain

Keywords: avulsion, late replantation, growing patient

Purpose: There is lack of information of the population on how to manage dental trauma. Even emergency personnel and physicians in many situations have a knowledge less than desirable. Most of the time the avulsed tooth is left dry, instead of immediate replantation or maintaining the tooth in adequate media. These are some reasons that turn these cases into very complex ones, ending many times in tooth lost. The purpose of this work is to present that once the tooth is still available, not lost, even long time after the accident, late replantation is an option to consider.

Methods & Materials: CASE REPORT Male patient, 11 years old, skateboard accident. After visiting 3 different dental clinics with no dental treatment done, he came to our clinic 72h afterwards. Patient's medical history without relevant information, tetanus immunization was current. Extraoral examination showed swelling and laceration of the lower lip. Intraoral examination: #1.1 avulsion (72h extraoral time, stored dry), #2.1 latero-palatal luxation (occlusal interference, grade 1 mobility). Rx from the lip, #1.1 tooth and socket, tooth #2.1 and lower incisors were done.

Results: Treatment: Cleaning the area, local anaesthesia. #2.1 Forceps reposition, into its original location. Reposition of displaced bone with finger pressure. #1.1 Removing clot from socket and irrigation with saline. Removal soft tissue from #1.1 root carefully with gauze, afterwards immersion in 2 % sodium fluoride solution for 20 min. Replantation carefully with slight digital pressure. Sutured gingival tissues. Radiographic verification. Flexible splinting (TTS) for 4 weeks. Systemic antibiotics and antiinflammatories and soft diet. Endodontic treatment 7 days after with calcium hydroxide. In a late replantation, to limit or prevent as much as possible the root resorption and promote repair, root surface should receive treatment and endodontic therapy. The root surface is treated by mechanical removal of necrotic rests present. The root surface is covered with fluoride, because it forms fluorapatite strengthening the tooth. For the root canal dressing, the best option until now is calcium hydroxide because of its antimicrobial and anti-resorptive properties.

Conclusion: The decision to reposition the lateral luxated and avulsed permanent central incisors 3 days after the injury was based on the fact that he is a growing patient and the aesthetic is very difficult without the bone, although we know pulpal and periodontal ligament complications are common in teeth with completed root formation. In our opinion, in young-growing patients maintaining the teeth is vital, to have the maximum bone, following the evolution very close and treating the often complications.

REVASCULARIZATION OF IMMATURE TEETH WITH EXTERNAL RESORPTION: A CASE SERIES

Gülcan, Banu*, Ulusoy, Ayça Tuba; Zencirli, Ilkay; Gülcan, Banu
University of Ondokuz Mayıs, Faculty of Dentistry
Department of Pediatric Dentistry
Samsun, Turkey

Purpose: Traumatic dental injuries may result in endodontic complications such as enflamatuar root resorption and cessation of root development. Revascularization of the dentin-pulp complex is a new approach that involves disinfecting the root canal and allowing for continued root development with thickening the lateral dentinal walls by deposition of new hard tissue. The purpose of this case series was to present the revascularization of immature permanent incisors that had evidence of enflamatuar root resorption.

Methods & Materials: Immature two permanent central incisors with enflamatuar external resorption of 11 and 12 years old patients were treated by a revascularization protocol that used 2.5 % Na OCl irrigation, medication with calcium hydroxide placed in the root canal, induction of apical bleeding, and coronal sealing with white mineral trioxide aggregate.

Results: In radiographic and clinical six months follow-up both cases were asymptomatic and functional, and roots continued to develop.

Conclusion: Revascularization may be a promising treatment in immature necrotic teeth that has evidence of external root resorption.

MANAGEMENT OF A COMPLEX DENTOALVEOLAR TRAUMA: A CASE REPORT

Guner, Sirin*, Guler, Nurhan, Sandalli, Nuket
Yeditepe University Faculty of Dentistry
Department of Pediatric Dentistry, Department of Oral and Maxillofacial Surgery
Istanbul, Turkey

Keywords: alveolar fracture, avulsion, regenerative endodontic treatment

Purpose: Dentoalveolar trauma is a common and complex injury that affects multiple oral tissues and has significant negative functional, esthetic, psychological effects on children .The aim of this report is to present the management of a pediatric patient with a complex dentoalveolar traumatic injury to the maxillary anterior region.

Methods & Materials: An 8-year-old girl with severe dentoalveolar trauma to the maxillary anterior region presented to Yeditepe University Department of Pediatric Dentistry less than 40 minutes after a traumatic injury. The intraoral examination and radiographic findings revealed an avulsed maxillary left central incisor, lacerated upper gingiva around the incisors, fracture of the maxillary anterior alveolar process with substantial displacement of alveolar segment involving left primary canine. Emergency treatment consists of replantation of avulsed tooth, repositioning of the displaced alveolar segment followed by placement of wire and composite resin splint and stabilization and fixation of fractured alveolar segment with custom made acrylic splint. The traumatized teeth were treated endodontically due to the pulpal necrosis. Regenerative endodontic treatment procedure was carried out to replanted immature central incisor using NaOCl as irrigant, a bi-antibiotic paste consisting of metronidazole and ciprofloxacin, followed by blood clot induction from periapical tissues and mineral trioxide aggregate as coronal root canal seal. Clinical and radiographic controls were made with regular intervals.

Results: After 12 months of follow up, the fracture of the alveolar process was completely healed and the replanted tooth presented continued root development with no signs of ankylosis or periapical pathology.

Conclusion: Early emergency management and follow-up can prevent further complications and enhance treatment success of traumatic dental injuries. Regenerative endodontic procedure, that enables continued root development, can be considered as a treatment approach in avulsed and replanted immature permanent teeth with symptoms of pulpal necrosis.

CLINICAL OUTCOME OF MTA APICAL-PLUG-TECHNIQUE FOR MANAGEMENT OF IMMATURE TEETH

Gur, Cansu*, Helvacioğlu-Yigit, Dilek*, Aydemir, Seda*, Kocak-Buyukdere, Ayse**
*Kocaeli University, Faculty of Dentistry ** Kocaeli University, Faculty of Dentistry
*Endodontics **Prosthodontics
Kocaeli, Turkey

Purpose: The aim of this report was to evaluate the clinical outcome after treatment of immature permanent teeth by using MTA as an apical plug technique in 8 cases.

Methods & Materials: This retrospective study considered 8 case reports (mean 16 years, range 15-21 years) including 10 teeth. Patients referred to the Department of Endodontics, Faculty of Dentistry, Kocaeli University, with a chief complaint of pain and/or acute abscess, with a history of trauma. Endodontic treatments were performed in multi appointments until the symptoms of the patients were dissolved. K-files (#40 to #80) and Gates-Glidden burs were used to prepare the canals. Copious irrigation using 2.5% NaOCl and 17% EDTA was performed. Apical third of the canals were sealed using MTA apical-plug. The rest of the root canals were obturated using lateral compaction of gutta-percha and AHPlus sealer. The teeth were restored with either fiber post and/or composite filling. Short-term clinical outcomes (1-3 years) are reported.

Results: Up to the 2-years follow-up the teeth were asymptomatic and the results of the radiographic examinations showed periapical healing in all cases.

Conclusion: This case series highlight the use of MTA plug technique in the teeth with open apices can be a proper treatment modality.

NON-SURGICAL ENDODONTIC TREATMENT OF TRAUMATIZED TEETH WITH ROOT CANAL CALCIFICATION

Iglesias, Júlia Eick*, De Borba, Maristela Gutierrez; Ghisi, Alexandre; Scarparo, Roberta
Kochenborger; Vier-Pelisser, Fabiana Vieira; Morgental, Renata Dornelles; Rahde, Nicole De Mello;
De Figueiredo, José Antônio Poli
Pontificia Universidade Católica Do Rio Grande Do Sul
Dentistry Faculty - Clinical Department
Porto Alegre, Rio Grande Do Sul, Brazil

Purpose: Dental trauma promotes many side effects, some of them seen months and sometimes years after the event. The present case reports the history of trauma in an eleven-year-old boy, occurred three years ago. At that time he bumped his mouth against the bicycle handlebars and the elements 7, 8, 9 and 10 suffered extrusion. During this period the only treatment provided was a splinting that remained for two months followed the accident. Since then, these teeth were no longer followed up and an orthodontic treatment was started but was not finished. He came for endodontic treatment because of an unusual image in a routine radiographic exam of teeth 8 and 9. The Cone Beam Computed Tomography showed a wide root canal with thin dentin walls in the cervical and medium thirds of tooth 8. Its apical third was calcified and a periapical lesion was evidenced. Tooth 9 presented periapical lesion and root canal calcification except for the apical third. Both teeth were not restored, showed no edema, discoloration or mobility and were not responsive for sensitive or percussion tests.

Methods & Materials: An attempt was made to treat the canal of these teeth in order to keep the elements for a longer time, preventing bone loss for future implants. In tooth 8, after the rubber dam placement, endodontic access was carried out, followed by root canal preparation up to #30 k-file, using irrigation with EDTA and 2% sodium hypochlorite. Due to the size of the lesion, a switch of calcium hydroxide was made for 3 months. After that, the obturation was performed with a conventional gutta-percha cone in association with Obtura system. In tooth 9, in order to facilitate canal localization, EDTA gel and modified stainless steel instruments were employed. Once the working length was achieved, the instrumentation was performed up to a #55 file. Intracanal dressing with calcium hydroxide was kept for 2 weeks and the tooth was obturated by means of gutta-percha lateral condensation. After that, both teeth were restored with composite resin.

Results: With the use of EDTA and manual instruments the access of the calcified root canals was possible, avoiding a surgical treatment. In the six-month follow-up the periapical radiograph showed a reduction of the lesion and up to the present moment the patient remains asymptomatic.

Conclusion: Despite canals calcification, it was possible to perform a non-surgical root canal treatment. Key words: dental trauma, root canal calcification, CBCT

DECORONATION AS A TREATMENT OPTION FOR CROWN- AND ROOT-FRACTURED INCISOR.

Ileri Keceli, Tulin*, Cehreli, Zafer C.
Hacettepe University
Department of Pediatric Dentistry
Ankara, Turkey

Keywords: decoronation, dental trauma

Purpose: This case report presents the surgical and prosthetic treatment approach of a traumatized incisor with a crown-root fracture and a separate root fracture.

Methods & Materials: An 11-year-old girl was referred to the pediatric dentistry clinic with the complaint of tooth fracture one day after a fall accident. Clinical and radiographic examination of the maxillary left central incisor revealed a crown-root fracture and a separate root fracture in the middle third of the root. A major portion of the crown was lost during trauma, with only the cingulum and exposed pulp visible on oral examination. Conservative treatment of the fractured coronal fragment was not possible, and its extraction would lead to resorption of the alveolar bone. Thus, decoronation was employed to reduce the palatal hard tissues to the cervical level. Following soft tissue healing, a removable appliance involving a plastic tooth crown was fabricated to restore esthetics and function.

Results: The patient has been attending regular controls for two years. Radiographic controls demonstrated uneventful retention of the decoronated fragment within the alveolar bone.

Conclusion: Based on two-year follow-up, the decoronation procedure provided an effective solution for preserving the alveolar ridge.

USE OF MTA IN THE TREATMENT OF DIFFERENT ENDODONTIC PROBLEMS

Isik, Merve*, Aksel, Hacer; Eymirli, Ayhan; Yilmaz, Zeliha
Hacettepe University, Faculty of Dentistry
Endodontics
Ankara, Turkey

Purpose: The aim of this case report is to demonstrate the treatment of different endodontic problems (iatrogenic root perforations, apical barrier formation and internal root resorption) by using Mineral Trioxide Aggregate (MTA).

Methods & Materials: Case 1 (Iatrogenic root perforation): A 40 year-old-female patient with a noncontributory medical history was referred to department of Endodontics. She complained of spontaneous pain in related to tooth #35. Clinical examination showed no sensitivity to percussion and palpation tests. After endodontic access cavity was achieved, a perforation was observed through the floor of the pulp chamber into the mesial side of the root canal wall. Root canal treatment was completed and MTA Angelus (Curitiba, Paraná, Brazil) was used to repair the perforation. Case 2 (Apical barrier formation): A 17 year-old-male patient, with a noncontributory medical history was referred for treatment of pain in the upper incisors to Endodontic Department. He reported that he had experienced a traumatic injury due to fall accident at the age of 8. Avulsion of tooth #21 had been occurred in the accident. He failed to take any dental treatment until the teeth began to pain severely. Clinical examination revealed crown fracture with variable degrees in the teeth #11 and #22. Periapical radiograph of the teeth showed incomplete root development with wide-open apices and periapical lesions. After the calcium hydroxide dressing (CaOH₂), MTA Angelus (Curitiba, Paraná, Brazil) was placed. Then root canals were filled with AH plus and thermoplasticized gutta-percha technique. The patient was referred to the prosthetic restoration of the teeth. Case 3 (Internal root resorption): A 39 year-old-male patient, with a noncontributory medical history came to Endodontic department with the complaint of intraoral swelling in related to tooth #11. Clinical and radiographical examination revealed that tooth #11 was sensitive to percussion and had a periapical lesion and internal cervical resorption with an irregular border that contained radio-opaque tissue. After intracanal medication with CaOH₂, the apical part of the resorption was obturated with gutta-percha. MTA Angelus (Curitiba, Paraná, Brazil) was used to obturate resorption and the crown was restored with the composite resin restoration.

Results: The follow-up at 6-18 months showed healing of periapical radiolucency and the patients satisfied with aesthetic and function of the teeth.

Conclusion: This case report suggests that MTA is a convenient sealing material and successively induce healing.

INTERNAL ROOT RESORPTION: CASE REPORT

Jemâa, Mayada*, Abdelmoumen, Ehsen; Zouiten, Sonia; Boughzala, Abdellatif; Khatteche, Bassem
Military Hospital
Department of Dental Medecine
Tunis, Tunisia

Purpose: To report the treatment and follow-up of a maxillary lateral incisor with internal resorption managed by endodontic treatment and white mineral trioxide aggregate (MTA) repair through surgery.

Methods & Materials: Internal root resorption is rare in permanent teeth, and is characterized by an oval-shaped enlargement of the root canal space. There are different theories concerning the origin of the pulpal granulation tissue involved in internal resorption. The most logical explanation is that pulp tissue becomes inflamed due to an infected coronal pulp space. In our work, we are going to present a case of extensive internal root resorption affecting tooth 22 in a 45-year-old female patient, with a history of trauma in that region. An important loss of tooth structure and a perforation with lateral periodontal communication were complicating factors. The treatment was based on endodontic treatment and reconstructing the tooth through surgery with white MTA.

Results: Follow-up clinical examinations and radiographs over 7 months demonstrated the maintenance of a functional and asymptomatic tooth.

Conclusion: The case presented here was successful both clinically and radiographically. There was healing of the radiolucency in the alveolar bone and absence of pathologic features. The treatment of this case required a collaboration between endodontist and parodontologist.

LASER USAGE IN THE TREATMENT OF A MAXILLARY LATERAL LUXATION

Kaki, Gültür Devrim*, Kara, Emine and Alparslan, Nazli Zeynep
Van Yuzuncu Yil University
Department of Endodontics, Department of Restorative Dentistry, Department of Periodontology
Van, Turkey

Keywords: lateral luxation, laser

Purpose: Researches on dental injuries in adults are rare but it is known that one third of dental trauma involves adults. The regeneration capacity of adults is lower than the children, therefore the therapy of severe injuries can fail. Laser is one of effective methods for disinfection of periodontal pockets and root canals. On the other hand, the usage of laser therapy for biostimulation on soft tissue wounds stimulates healing of lesions and relieves post-traumatic discomfort and pain. The purpose of this case study is evaluating the results of the laser applications for the therapy of a severe injury of an adult without any periodontal surgery.

Methods & Materials: A 32 year old, male patient referred to our clinic, two weeks after the trauma. His complaints were pain and mobility in his maxillary central incisor after a traumatic sport injury. On radiographic examination, only the tooth no.11 was affected and clinically a severe lateral luxation had been observed. After reposition of the tooth with digital pressure gently into its original location, a Ribbond fiber splint was applied. After splinting, root canal treatment was performed by using diode laser (Ezlase 940nm) for canal disinfection. Bone loss on the vestibular and mesial surfaces of the tooth was severe. Periodontal curettage was made and then the Er,Cr:YSGG laser (Waterlase MD) was used to perform root surface disinfection in the pocket. Biostimulation with diode laser was performed at the first, third and seventh days of the treatment. The pocket was disinfected with Er,Cr:YSGG laser in all appointments for 8 weeks. After 8 weeks, bone regeneration was seen on the parallel periapical radiographs and the splint was removed. The tooth was supported with digital pressure during this procedure. A removable orthodontic screen was made to prevent pushing of the tongue.

Results: At follow up examination, the tooth was found asymptomatic and it showed radiographic bone regeneration. In addition, mobility of the tooth was significantly decreased and soft tissue showed significant healing.

Conclusion: The laser application in the adult injury can be effective on the healing, elimination of endodontic and periodontal microorganism and it is a minimal invasive technique for treatment of periodontal problems.

MULTIDISCIPLINARY APPROACH OF A COMPLICATED CROWN-ROOT FRACTURE WITH 180° ROTATION

Kara, Nazan*, Ersin, Nazan
Ege University Faculty of Dentistry
Department of Pedodontics
Izmir, Turkey

Keywords: dental trauma, crown-root fracture, 180° rotation replantation

Purpose: The purpose of this case was to present a complicated crown-root fracture where a multidisciplinary approach was successfully performed.

Methods & Materials: A 12-year-old female patient who suffered a complicated crown-root fracture on maxillary right central incisor and enamel-dentin-pulp fracture on maxillary left central incisor referred to our clinic. The patient's left incisor was treated by endodontic treatment and restored with a resin composite. Her right incisor was treated using 180° rotation replantation technique. The repositioned incisor was stabilised by sutures and splinted with flexible resin wire splint for two weeks. The root canal was extirpated and dressed with calcium hydroxide immediately. Two weeks later, the root canal treatment was finished conventionally and restored with a resin composite.

Results: Clinical and radiographic follow-up of the maxillary central incisors during recalls and after 18 months showed no signs of root resorption, marginal bone loss or periapical pathology and good aesthetics and functions were maintained.

Conclusion: It can be concluded that intentional replantation with 180° rotation of complicated crown-root fractured teeth allows successful and conservative approach, as presented in this case.

MULTIDISCIPLINARY MANAGEMENT OF COMBINED-LESION IN LATERAL INCISOR WITH UNUSUAL ROOT

Karsiyaka Hendek, Meltem*, Akyuz Ekim, Sefika Nur; Erdemir, Ali; Olgun Erdemir, Ebru
University of Kirikkale
Department of Periodontology
Kirikkale, Turkey

Keywords: Endodontic-periodontal lesion, periodontal regenerative therapy, root canal treatment

Purpose: The aim of this case report was to present clinical and radiological findings of regenerative periodontal treatment combined with apical resection performed following endodontic treatment of endodontic-periodontal lesion in maxillary lateral incisor with unusual root canal.

Methods & Materials: A 42-year-old, systemically healthy, non smoker male patient was referred to our department for consultation with the diagnosis of endodontic-periodontal lesion in right maxillary lateral incisor. In his periodontal examination, a fistula with supuration, gingival recession, inadequate attached, unhealthy gingiva and no mobility were observed. In his endodontic examination, a huge radiolucency around the tooth, incomplete root canal treatment, unusual root and missed root canal were determined with periapical radiography and computed tomography. The patient was not satisfied with aesthetically. Firstly, root canal retreatment was planned for the tooth. Following access cavity preparation, previous root-filling material was removed, the missed root canal was determined and standard endodontic treatment was performed. The root canals were obturated using gutta percha, AH plus root canal sealer and access cavity was restored with composite material. After 4 weeks, regenerative periodontal therapy was applied. Following flap elevation, granulation tissues in region of the tooth were removed and root planing was applied. The root-end cavity preparation was performed and filled with MTA root-end filling material. Following infra bone defect was filled with bovine xenogenic graft material, collagen and platelet-rich fibrin membrane were placed over the graft. Due to inadequate attached gingiva, laterally sliding flap was performed and sutured with 5-0 polypropylene suture. Clinically and radiographically, 9 months follow-up of the case demonstrated significant improvement in the width of keratinized/attached mucosa, healthy gingiva and significant bone fill was detected around the root apex. Finally, connective tissue graft was planned for remained gingival recession.

Results: Significant clinical and radiologic improvements were achieved after combined operation. A satisfactory result has been achieved after the overall treatment and the patient was very happy with his new appearance.

Conclusion: Interdisciplinary approach is required for effective treatment of both tooth and surrounding tissues in endodontic-periodontal lesions. Following successful endodontic treatment, regenerative surgery of supportive periodontal tissues is an effective treatment method in regaining of the tooth and gingival health.

ENDODONTIC MANAGEMENT OF TRAUMATIZED INCISORS WITH LATERAL-LUXATION: A CASE REPORT

Kasikçi Bilgi, Ilknur*, Çaliskan, Mehmet Kemal
Ege University Faculty of Dentistry
Department of Endodontics
Izmir, Turkey

Purpose: The aim of this case report was to evaluate endodontic management, clinical and radiographical success of traumatized central and lateral incisors.

Methods & Materials: A 16-years old male patient referred to our clinic twelve hours after trauma. Maxillary left and right central incisors were diagnosed with lateral luxation after clinical and radiographical examination. Clinical examination showed that maxillary left central incisor had severe luxation while maxillary right central incisor had moderate luxation. Involving teeth were replaced and splinted using composite resin and wire. After performing biomechanical root canal preparation, calcium hydroxide paste was applied as an intracanal medicament for four weeks period. At the end of four weeks, splint and calcium hydroxide paste was removed, and root canal therapies were completed. Root canal treatment for nonvital maxillary left lateral incisor was also performed. The coronal fragment of maxillary right central incisor was reattached with composite resin.

Results: After twelve months clinical and radiographical examination showed that involving teeth were asymptomatic and healing of the periradicular tissues was observed.

Conclusion: After repositioning and splinting, root canal therapy was found to be successful in teeth with lateral luxation.

ENDODONTIC-MANAGEMENT OF IMMATURE TEETH WITH SPONTANEOUS APICAL-CLOSURE AND PERIAPICAL LESIONS

Kaval, Mehmet Emin*, Çaliskan, M.Kemal; Kaval Mehmet Emin
School of Dentistry, Ege University, Izmir, Turkey
Endodontology
Izmir, Turkey

Keywords: immature teeth, periapical healing, spontaneous apical closure

Purpose: To report endodontic management of spontaneous apical closure of infected untreated immature teeth with periapical lesions following previous trauma and to suggest possible mechanisms for the occurrence of non-induced hard tissue barrier.

Methods & Materials: Four patients were referred to the endodontic clinic for treatment of four maxillary anterior incisors that presented with acute or chronic apical periodontitis. The patients' dental histories indicated that the teeth had been subjected to trauma approximately 12 to 18 years previously. Radiographically, the involved teeth exhibited incomplete root formation with spontaneous apical closure associated with an apical radiolucency. After biomechanical preparation, a calcium hydroxide paste was applied and was changed one or two times within 3 months. The root canal of all cases except one case was filled by lateral compaction of gutta-percha and sealer.

Results: The follow-up was 16-50 months after completion of root canal treatment, where clinical and radiographic examinations revealed adequate clinical function, absence of clinical symptom and a significant healing of the periapical radiolucency.

Conclusion: Spontaneous apical closure may develop in immature pulpless teeth with periapical lesions. In such cases periapical lesions may heal with nonsurgical endodontic treatment approach despite the presence of the apical barrier.

MANDIBULAR PREMOLARS WITH THREE ROOT CANALS: 2 CASE REPORTS

Keles, Ahmet*, Çetin Canbazoglu, Çigdem
Hacettepe University Faculty of Dentistry
Department of Endodontics
Ankara, Turkey

Purpose: Successful endodontic treatment requires accurate diagnosis, understanding of root canal anatomy and morphology. Before initiating any endodontic therapy, probability of extra canals should be considered. The prevalence of three root canals in mandibular premolars was reported to be %0.4. The aim of this case report is to present the anatomic and morphological variations and treatment approaches of mandibular premolars.

Methods & Materials: CASE-1: A 15-year-old male patient contributing thalassemi major and diabetes mellitus type-1 was presented to our clinic with the chief complaint of sensitivity to cold foods in relation to lower left posterior teeth. Intraoral examination revealed distal caries on tooth 35. No swelling or sinus tract was present. Tooth was not sensitive to palpation and percussion. The periapical radiograph showed multiple root canals. Under local anesthesia and rubber dam was placed. The access cavity was prepared. After reaching the pulp chamber, all canal orifices were detected and working lengths of root canals were determined. Biomechanical preparation was accomplished with ProTaper files, root canals were irrigated using 2.5% sodium hypochlorite and of %17 EDTA as a final rinse. Then, the canals were dried with paper points and obturated with ProTaper gutta percha cones using AHPlus sealer. CASE-2: A 41-year-old female patient with non-contributing medical history was presented to our clinic with the chief complaint of spontaneous pain in relation to lower right posterior teeth. Radiographic and intraoral examination revealed that the tooth 44 have three root and three canals. No sinus tract or swelling was present and sensitive to percussion. Under the local anesthesia, the access cavity was prepared and rubber dam was placed. Working lengths were detected. Shaping and cleaning was accomplished with k-files and 2.5% sodium hypochlorite and %17 EDTA. The canals were dried with paper points and obturated with gutta percha cones using AHPlus sealer with lateral condensation technique.

Results: After treatment finished, patients were controlled at sixth months. Teeth are asymptomatic and functional. They are still under control.

Conclusion: Mandibular premolars show a wide variety of root canal anatomy and an accurate diagnosis of the morphology of the root canal system is necessary for successful root canal treatment. The clinician should be careful about to identify the presence of extra roots and canals and their morphology. Angled radiographs, proper access preparation and magnification devices are recommended. Examination of the pulp chamber floor may offer clues to the location of orifices and to the type of canal systems.

PULP SURVIVAL AFTER HORIZONTAL ROOT FRACTURE

Kim, Sin-Young*, Lee, Yoon, Kim, Yemi
Seoul St. Mary'S Dental Hospital, Catholic University of Korea
Conservative Dentistry
Seoul, Korea (South)

Purpose: Pulp necrosis is a common complication after horizontal root fracture, and its frequency is reported as 20-44%. Close clinical and radiographic follow-ups are necessary to disclose pulp necrosis. Extrusion of the coronal fragment, tenderness to percussion, and radiographic signs such as development of radiolucencies adjacent to the fracture line, can usually be detected within the first 2 months after injury.

Methods & Materials: A 51-year-old male presented to Department of Conservative dentistry for slip down injury. Left and right maxillary central incisors, and right lateral incisor (tooth 11,21,12) were diagnosed as horizontal root fracture. Fracture line was situated in the middle third of the root on tooth 11,21 and apical third on tooth 12. Uncomplicated crown fracture was also found on tooth 11. The amount of dislocation of the coronal fragment was less than 0.5mm on tooth 12, 1.5mm on tooth 11, and 3.7mm on tooth 21. Each coronal segment was repositioned and semi-rigid flexible splint was applied. During follow up period, tooth 12,11,21 showed negative response to electronic pulp tester (EPT) (DigitestTM; Parkell Inc., Farmingdale, NY, USA). After 1 month, sinus tract was observed on tooth 11 and radiographic radiolucency was detected on the root fractured area. Root canal treatment was performed on the coronal part of tooth 11 using mineral trioxide aggregate (ProRoot MTA, Dentsply Tulsa Dental, Tulsa, OK, USA). Tooth 12,21 showed negative response to EPT, but no radiographic radiolucency was observed except pulp canal obliteration. Five months later, tooth 21 showed positive response to EPT and tooth 12 also did after 14 months.

Results: At 6-year follow up, tooth 12,21 was asymptomatic with no sensitivity to percussion and responded positively to EPT. Radiographic examination demonstrated complete healing of the fractured area on tooth 11.

Conclusion: The following factors have a positive influence upon healing : immature root formation, lower age, and less displacement of the coronal fragment. However, in this case, pulpal healing was observed in the highly displaced of coronal fragment of tooth 21, and pulp necrosis was observed in tooth 11. The reason was thought to be related to the uncomplicated crown fracture of tooth 11, bacteria could gain access to dental pulp through the dentinal tubules. A negative sensibility response immediately after injury does not necessarily indicate pulp necrosis, as a slow return to normal vitality is often observed. The diagnosis of pulp necrosis should therefore always be based upon a combination of clinical and radiographic evaluation.

INTRARADICULAR SPLINTING WITH ENDODONTIC INSTRUMENT OF HORIZONTAL FRACTURE: CASE REPORT

Koçak, Mustafa Murat*, Çiçek, Ersan
Bülent Ecevit University, Faculty of Dentistry
Endodontics
Zonguldak, Turkey

Keywords: Intraradicular splint, Root fracture, Trauma

Purpose: This case report presents the endodontic management of a horizontally fractured incisor tooth involving healing with hard tissue using an intraradicular splinting technique.

Methods & Materials: A 14-year-old female patient referred to our clinic three days after a traffic accident. In intraoral diagnosis, the left maxillary lateral incisor was absent, the left and right maxillary incisors were mobile horizontally and vertically. In radiographic diagnosis, the right maxillary central incisor was fractured horizontally in apical third. A stabilization splint was applied from the right maxillary canine to the left maxillary canine tooth. After three weeks, the right and left central incisors were non-vital. A standardized root canal treatment was applied to left central incisor tooth. The coronal and apical root fragments of the right central incisor were endodontically treated and obturated at single visit with MTA, whilst the fragments were stabilized internally by insertion of a stainless-steel endodontic file into the canal.

Results: After the stabilization splint was removed and the patient was recalled for each 6 months during three-years follow-up. Three-years follow-up examination revealed a satisfactory clinical and radiographic findings with hard tissue repair of the fracture line.

Conclusion: This case report demonstrated that intraradicular splinting with hand files can be used to manage horizontally fractured tooth even in apical thirds.

THE REHABILITATION OF CROWN FRACTURES WITH ORIGINAL FRAGMENT: THREE CASES

Koruyucu, Mine*, Barlak Pelin, Tanyeri Tuğçe, Seymen Figen
Istanbul University, Faculty of Dentistry,
Department of Pedodontics
Istanbul, Turkey

Keywords: tooth reattachment, restoration, composite

Purpose: Anterior teeth fractures are frequently encountered in clinical dental practice. The reattachment of dental fragments, if possible, is a conservative and effective technique, presumably with sufficient strength, while maintaining original contour, incisal translucency, and reducing chair time and cost. This case presentation concerns the management of the complicated crown fractures.

Methods & Materials: First case is 12 year-old male patient who suffered a vertical crown fracture of permanent maxillary central incisor (#21) due to a traumatic fall. Large pulp exposure and partial infection were observed in the clinical examination. Endodontic treatment was performed and dental fragment was reattached. Second case is 9 year-old female patient who suffered from a vertical crown fracture of permanent mandibular central incisor (#31). The clinical examination revealed pulp exposure with no invasion of the biological space. Due to the extension of the fracture, partial pulpotomy was performed and the tooth was restored using the autogenous fragment. The third case is 9 year-old female patient who suffered from vertical crown fracture of permanent mandibular central incisor (#41). Partial pulpotomy was performed and the tooth was restored with original fragment.

Results: The treatment was the reattachment of the dental fragments with a composite resin and adhesive systems. The teeth were observed by clinically and radiologically regularly.

Conclusion: Clinical and radiologic follow-up of the central incisors after 24 months showed no signs of bone resorption or pathology. The patients have good aesthetics and function.

CONSERVATIVE MANAGEMENT OF SYMPHYSIS FRACTURE AND TOOTH IN FRACTURE LINE

Krishnan, Unni*, Moule, Alex

*New Mowasat Hospital, Kuwait

Faculty of Dentistry, Kuwait University

Salmiya, Salmiya, Kuwait

Keywords: Symphysis fracture, tooth in fracture line, cone beam computed tomography

Purpose: To demonstrate the importance of monitoring pulpal status of teeth retained in fracture line.

Methods & Materials: A 35 year old healthy Indian male suffered a fall which resulted in pain and swelling of his lower jaw. He reported immediately to a general dentist who confirmed the presence of mandibular symphysis fracture with panoramic radiograph. He was placed on non-steroidal anti-inflammatory agents and referred to an oral surgeon. The specialist advised to carry out open reduction of the fracture site. However the patient did not take further treatment. The patient reported to us one month after the trauma with primary complaint of mobile lower anterior tooth. On examination, he had 32mm interincisal mouth opening and the lower right central incisor (LR1) was grade 2 mobile. LR1 was unresponsive to cold and electric pulp sensitivity test. There was no mobility of the fractured segments of the mandible or step deformity. Cone beam computed tomography (CBCT) imaging showed radiolucency between the fractured segments of the mandible which was continuous with the root apex of LR1. CBCT also demonstrated Vertucci type 3 root canal morphology on LR1. The tooth was splinted to adjacent teeth using composite resin and pulpectomy was done on LR1. Calcium hydroxide was placed as intra canal medication. The patient was referred to an oral surgeon who advised open reduction and rigid fixation due to the radiographically evident non-union. The patient declined surgical treatment and hence non-surgical root canal treatment on LR1 was completed without any further treatment. The splint was removed after 6 weeks.

Results: After a follow up period of 8 months, CBCT images confirmed complete healing of fractured symphysis and resolution of periapical radiolucency around LR1. The tooth had no unnatural mobility and there was full range of movement of the mandible.

Conclusion: 1. When a decision is made to retain teeth in fracture line, pulpal status should be monitored so that the necrotic pulp does not delay healing of the already compound fracture. 2. When there is no mobility of the fractured segments, conservative management of the symphysis fracture may result in healing. 3. CBCT reveals three dimensional anatomy of the root canal system and thus aids predictable root canal treatment of teeth in fracture line.

MANAGEMENT OF HORIZONTAL ROOT FRACTURES USING INTRARADICULAR SPLINTS

Kurnaz, Safa*, Keçeci, Ayse Diljin

Suleyman Demirel University

Endodontics

Isparta, Turkey

Purpose: The aim of this study was to prevent traumatized teeth with horizontal root fractures from extraction by intraradicular splinting during root canal treatment.

Methods & Materials: A 42-year-old male applied to the Endodontic Department of Suleyman Demirel University's Faculty of Dentistry with traumatic history. Clinical examination of the patient revealed that maxillary central incisors were tilted slightly lingually in position, were mobile to grade III and nonvital. Radiographic examination of the teeth showed root fractures at upper and middle thirds of the roots. The teeth were sensitive to percussion and palpation. Access cavities were prepared under local anesthesia. The working length could be reached hardly due to displacement of the fragments. The root canals were instrumented to an apical size of ISO 60. Root canal medication was performed by using Ca(OH)₂, which was replaced at 3th week. Access cavities were filled with glass ionomer cement temporarily. At second month; after the removal of the medication, both root canals were irrigated with %2.5 NaOCl and saline. MTA was applied using lentulo to carry it into the fracture area. Obturation was performed using gutta-percha and Sealapex. In both of the root canals gutta percha was removed under the fracture lines, by leaving 5mm gutta percha at the apex. Hand files were placed and cemented into the root canals to keep the fragments in their positions. The access cavities were restored with glass ionomer cement and composite resin. The teeth were splinted buccally. The follow-up controls were performed at first and every 3 months.

Results: At last examination (18 months), there was still mobility. No periapical lesion, root resorption and/or pain were observed.

Conclusion: Horizontally root fractured teeth can be prevent from extraction. In addition to oral splints, intraradicular ones can be used for repositioning and healing of the tooth. Such cases need long term controls.

INTRUSIVE DISLOCATION: CASE REPORT

Machado, Andreia*, Abad, Ernani; Cortes, Antonieta; Schwartz, Luiz; Campos, Luis
Estacio De Sa
Endodontics
Rio De Janeiro, Brazil

Purpose: Report a case of severe traumatic intrusion of a permanent maxillary central incisor of a eight-year-old patient, showing the repositioning surgery performed and the clinical case.

Methods & Materials: ESM, eight-year-old female was referred to the Faculty of Dentistry, Estácio de Sá University (Rio de Janeiro, Brazil) reporting a fall after stumbling and accidentally hitting her mouth on the edge of a table. Medical history was taken, noting that the patient had no health abnormalities. Clinical and radiographic examination presented severe intrusion of the element 21, which showed the appearance of an extra tooth alveolus and an ectopic tooth in the palatal face. The treatment was started by the removal of the ectopic element and surgical repositioning of the element 21, which was intruded. A semi-rigid contention was applied to keep the tooth in its place. After 21 days, necrotic pulp of the tooth 21 was found, and therefore the endodontic treatment was performed. After the filling was concluded, the cavity access was restored with resin. The patient was instructed to return for clinical and radiographic control after 3 months.

Results: The treatment performed was effective and prognosis is highly favorable.

Conclusion: The clinical and radiographic control within short periods of time can contribute to develop an effective culture for future alternative treatment for this type of trauma.

APEXIFICATION POST TRAUMA: A "CLOSER" LOOK AT REPAIR

Meschi, Nastaran*, Lambrichts, Ivo; Hilkens, Petra; Bronckaers, Annelies; Van Gorp, Gertrude; De Munck, Jan; Huybrechts, Bart; Lambrechts, Paul
1)KU Leuven & Dentistry, University Hospitals Leuven 2)Hasselt University
1)Department of Oral Health Sciences 2)BIOMED
Leuven & Hasselt, Leuven & Hasselt, Belgium

Purpose: To investigate hard tissue harvested from the calcified bridge region of a periapical inflamed tooth, 10 years after apexification.

Methods & Materials: The right central upper incisor of an 8-year-old female patient underwent an apexification treatment with calcium hydroxide, one year after trauma. Prior to late orthodontic therapy, an endodontic retreatment was performed at the age of 18, due to unsatisfactory root canal filling. During the retreatment, periapical inflammation was observed and hard tissue entangled with gutta-percha (from the initial treatment) was collected. These samples underwent histological, TEM, SEM and EDX analysis.

Results: Newly formed, irregular shaped, atubular osteodentine (OD) was observed in the midst of connective tissue and OD producing cells. Blood vessels were also distinguished, surrounded by barium sulfate (originating from the gutta-percha) containing-macrophages.

Conclusion: The investigated hard tissue reveals a reparative process post apexification. The continuous remodeling of the OD in this case is due to the periapical inflammation. Apexification with calcium hydroxide induces a repair process which can maintain an inflammatory reaction, despite its antimicrobial property.

NEW TECHNIQUES FOR THE MANAGEMENT OF AVULSED TEETH

Mousavi, Seyed Amir*, Khademi, Abbasali
Isfahan University of Medical Sciences
Endodontics
Isfahan, Isfahan, Iran

Purpose: Introduction: Traumatic dental injuries occur in children with great frequency because of falls in schools, fighting or falls during riding a bike, making it necessary to visit a dentist. One of the most serious dental injuries is avulsion in which the tooth completely comes out of the dental socket. In the clinical view the socket is empty or it is filled by a clot. These injuries make the child and the parents extremely anxious because if avulsion is not managed immediately and properly it has dangerous side effect, like loss of the permanent tooth, esthetic problems, loss of self-confidence, malocclusion and malnutrition. The aim of this literature review was to collect the latest guidelines about avulsed teeth.

Methods & Materials: Review Report: Electronic search was carried out in Pubmed and Medline for controlled randomized clinical trials and review articles and American Association of Endodontists guidelines about diagnosis, treatment plan and follow-up of avulsed teeth. Articles were collected until the end of March 2013.

Results: Key words: Avulsion, Root canal therapy, Splints, Tooth socket

Conclusion: Conclusion: Since general dentists face this condition more than others they are in the first line of treatment such children and can pervert most of the side effects with proper treatment. Therefore, having the latest knowledge about diagnosis, treatment plan and follow-up of avulsed teeth is essential for all the general dentists and specialists.

DISTRIBUTION OF CRACKED TEETH AND TREATMENT NEED AMONG ADULT NIGERIANS

Oginni, Adeleke Oke*, Adeleke, Adeyinka Adedayo†
*Obafemi Awolowo University, Ile-Ife Ekiti State University Teaching Hospital, PMB 5355,
Ado-Ekiti Nigeria.
†Department of Restorative Dentistry Department of Dental Surgery
*Ile-Ife, Ado-Ekiti, *Osun State, Ekiti State, Nigeria

Keywords: Cracked teeth, Root canal filling, Crown

Purpose: The present study sets out to determine the pattern and distribution of cracked teeth, Presenting signs and symptoms and treatment need among adult Nigerians.

Methods & Materials: The study included all patients diagnosed with cracked tooth in the Oral Diagnosis Unit of Obafemi Awolowo University Teaching Hospitals complex Ile-Ife Nigeria. The crack was identified using transillumination, or a bite test with tooth sloth, or a roll of rubber dam or cotton wool roll. Information recorded include patients age, gender, tooth involved, is the involved tooth restored or not? If restored, with what material? Pulp sensibility test/cold test, tooth mobility, presence or absence of tooth wear facet, direction of crack, result of percussion test, bite test, and depth of periodontal pockets. Associations between category variables were compared using Fisher exact test. A p value < 0.05 was considered to be statistically significant.

Results: During the study period, 185 teeth in 160 patients (86 male, 74 females) were diagnosed as cracked teeth. The age of the patients ranged from 18 – 67 years, with a mean age \pm S.D of 38.2 ± 12.6 years. One hundred and thirty (70.3%) of cracked teeth were in intact teeth with no previous restorations while 55 (29.7%) were in teeth with previous restorations. Of the cracked teeth with previous restorations, 40(21.6%) and 15(8.1%) had class I and class II amalgam fillings respectively. Maxillary first molar 63(34.1%) was the most frequently cracked tooth, followed by the mandibular first molar 37(20.0%). The maxillary premolars 13(7.0%) had more cracks than the mandibular premolars 11(6.0%). Cracks were found most frequently in the age group 41 – 50 years 61(33.0%), followed by 51 – 60 years 45(24.3%) and 31 – 40 years 32(17.3%). Mesiodistal direction was the most common direction of cracks in maxillary and mandibular teeth, 138(74.6%). One hundred and sixty three (88.1%) of the cracked teeth showed responses to the bite test, 108 (58.4%) were sensitive to percussion test. Almost all the cracked teeth responded positively to sensibility test 176(95.1%). Only 5(2.7%) had severe occlusal wear facet, 23 (12.4%) had moderate, and 34(18.4%) had mild occlusal wear facet. Deep periodontal pockets = 6mm were recorded in 32 (17.3%) cracked teeth. The treatment need was majorly full veneer crown (87(47.0%)) followed by root canal treatment plus full veneer crown 68(36.8%).

Conclusion: In contrast to most reported studies, the majority of cracked teeth occurred in intact, unrestored teeth. There was also an increased occlusal wear component.

ENDODONTIC MANAGEMENT OF OBLIQUE ROOT FRACTURE: A CASE REPORT

Ozdemir, Ozgur Soysal*, Keskin, Cangul . Uzun, Ismail
19 Mayıs University
Endodontics
Samsun, Turkey

Purpose: To present a case of oblique root fracture in the middle third of a maxillary first premolar tooth and root canal treatment of necrotic coronal fragment.

Methods & Materials: Case report: 35-year-old male patient presented with the complaint of tooth loss and pain due to impact injury he had experienced 3 months ago. Patient reported that a stone hit right side of his face and he had an orbital bone crack and lost maxillary canine tooth. Reconstructive surgery department treated patient for bone cracks and referred him for dull pain in his upper right quadrant. Clinical examination revealed tooth #14 had composite-resin restoration done two years prior, the tooth showed no discoloration, mobility and tenderness to percussion and palpation tests. Thermal and electric pulp tests showed #14 was nonvital. Radiographic examination revealed an oblique root fracture in the middle third of root and healing with interproximal bone tissue separating fragments. Spacing between fragments and absence of periapical lesion around apical fragment led to the assumption that apical fragment was vital. Root canal treatment of coronal fragment was initiated. Following local anesthesia restoration was removed and endodontic access cavity was prepared. After rubber-dam isolation working lengths were determined by electronic apex locator and two multi-angled periapical radiographs. Root canals were prepared mechanically up to size #60 under copious irrigation with 5.25 % NaOCl. Final irrigation was achieved with 17% EDTA and 2% CHX. Root canals were dried with sterile paper points and obturated with AH Plus Jet and gutta-percha by cold lateral compaction. Tooth was restored with composite-resin.

Results: 6th month follow-up after completion of root canal treatment, clinical and radiographic examination revealed healthy periapical structures and the patient was asymptomatic.

Conclusion: Teeth with root fractures can be treated with orthograde root canal treatment of nonvital fragment and regular follow-up.

ROLE OF OCCLUSAL TRAUMA IN PERIAPICAL PATHOSES: TWO CASE REPORTS

Ozkan, Leman*, Kurkcu, Banu, Cetiner, Serap, Ozer, Levent
Near East University, Faculty of Dentistry
Department of Pediatric Dentistry
Nicosia, Cyprus

Purpose: To describe two cases of pulp and periapical inflammation that developed after occlusal trauma.

Methods & Materials: In addition to clinical diagnosis, the patients (11 and 12 year old boys) were examined using periapical radiography. There were no caries and large periapical lesions were seen in the mandibular anterior area in both cases. Occlusal trauma was found to be the main cause and hence occlusal adjustment was performed initially. Afterwards conservative root canal treatment was performed. All canals were instrumented with crown-down methodology (K-file #40). During the treatment procedure, 5.25% sodium hypochlorite solution was used for irrigation and triple antibiotic paste containing ciprofloxacin, ornidazole and doxycycline were used in one case and a combination of calcium oxide and ornidazole were used in the other case for the initial intracanal dressings.

Results: Periapical healing was observed after 4 months with the single antibiotic paste whereas with the triple antibiotic paste the healing was observed after 2 months. The cases were followed-up for 3 years.

Conclusion: The present cases illustrated that occlusal trauma may cause pulp necrosis and large periapical lesions without any clinical symptoms. Therefore appropriate examination and diagnosis is vital for the treatment/prevention of such cases.

MANAGEMENT OF DENTOALVEOLAR TRAUMA INVOLVING ROOT FRACTURE AND LATERAL LUXATION

Ozsin, Cansu*, Akcan, Ahmet Cenk , Cehreli, C. Zafer
Hacettepe University
Department of Pediatric Dentistry
Ankara, Turkey

Keywords: dental trauma, root fracture, root resorption

Purpose: This case report presents the combined endodontic, restorative and orthodontic treatment approach in a trauma case comprising root fracture, lateral luxation and intrusion injuries.

Methods & Materials: A 12-year-old girl was referred to the Pediatric Dentistry clinic for evaluation and treatment of traumatized anterior teeth one day after a traffic accident. Clinical and radiographic examination revealed lateral luxation of maxillary lateral and central incisors, accompanied by an oblique mid-root fracture of the right central incisor and uncomplicated crown fractures of the neighboring incisors. The central and lateral mandibular incisors had uncomplicated crown fractures, with the right central incisor being severely intruded. The coronal fragment of the root-fractured incisor was extracted due to extreme mobility and the root canal was rapidly obturated with MTA at the apical level. The fragment was reimplanted in correct position and splinted as with the neighboring teeth. A week later, root canal therapy of the luxated and intruded incisors were initiated with intracanal calcium hydroxide due to signs of external root resorption. 4 weeks later, those roots were obturated with biodentine. During the time, the coronal portion of the fractured root was obturated with MTA, and the splint was removed 4 weeks later.

Results: All affected teeth have remained uneventfully in function over a one-year follow-up period. Orthodontic treatment has been initiated for the intruded mandibular incisor.

Conclusion: Luxation injuries of closed-apex teeth may lead to rapid endodontic complications. In the present case, canal obturation of root-resorbed teeth with biodentine provided stable healing pattern over the follow-up period.

MANAGEMENT OF COMPLICATED CROWN FRACTURE TREATED WITH ER:YAG LASER PULPOTOMY

Peker, Sertac*, Cekmegeli, Ezgi; Kargul, Betul; Akyuz, Serap
Marmara University Faculty of Dentistry; Istanbul, Turkey
Pediatric Dentistry
Istanbul, Turkey

Purpose: Cvek or partial pulpotomy is the treatment of choice for injured permanent teeth with exposed vital pulp tissue. It is defined as the surgical removal of a small portion of the coronal pulp tissue followed by placing a biocompatible agent to promote healing and maintain vitality of the remaining pulp tissue. This case report describes the management and the effects of Er:YAG laser irradiation in Cvek pulpotomy of permanent incisor with complicated crown fracture.

Methods & Materials: A 9-year-old boy was referred to the Department of Pediatric Dentistry, Dental School of the Marmara University with a complaint of a fractured upper anterior tooth, presenting to the clinic 24 hours after the trauma. According to his medical history, the patient exhibited neither systemic disease nor relevant problems. Extraorally, there was no apparent trauma to the soft tissues. The patient experienced pain with percussion and a slight mobility was recorded. The tooth responded normally to the electric pulp testing. Radiographic examination showed nearly complete root development and no periapical injury. Hence, a laser pulpotomy using Er:YAG laser irradiation was planned. The superficial layer of the exposed pulp was irradiated a depth of 2mm using an Er:YAG laser at 2Hz and 120mJ/pulse for 10 sec without water and air. The surface of the remaining pulp was irrigated with isotonic saline. MTA (Pro-Root MTA, Dentsply Maillefer, Ballaigues Switzerland) was mixed according to manufacturer's instructions and placed over the exposed pulp, then a saline-soaked cotton pellet with temporary filling material were placed over the MTA for 45 minutes to allow it to set. After removing cotton pellet the exposed dentin and MTA were both sealed with glass-ionomer cement. Finally the tooth fragment was reattached with a flowable resin composite. Follow-ups were carried out at 7, 30 days, 3 months, and every 6 months. During 24 months follow-up period the tooth remained symptom free and no inflammation or resorption was observed.

Results: Clinical and radiological findings confirm that Cvek pulpotomy with Er:YAG laser using MTA is an effective treatment of traumatized permanent incisors with pulp exposure. According to 2 year follow up, pulpotomy using Er:YAG laser revealed good treatment outcome.

Conclusion: These results suggest that effects on pulp tissues during a pulpotomy procedure by Er:YAG laser irradiation are minimal, if appropriate parameters are selected, and this is a potential therapy for pulpotomy of human teeth. Er:YAG laser irradiation is an acceptable alternative in Cvek

FAVORABLE PROGNOSIS OF A DENTAL INTRUSION - CASE REPORT

Scaraficci, Ana Claudia*, Bramante, Clovis Monteiro; Bramante, Alexandre Silva; Andrade, Flaviana Bombarda
Bauru School of Dentistry - University of Sao Paulo
Department of Endodontics
Bauru, Sao Paulo, Brazil

Keywords: dental trauma, intrusion, calcium hydroxide

Purpose: Intrusive luxation is considered one of the most severe dental trauma, because it may result into pulp necrosis, root resorption, ankylosis and marginal alveolar bone loss. Such complications may be minimized by an endodontic treatment. This case report aimed the effectiveness of an endodontic treatment, in order to minimize the complications caused by intrusive luxation in a permanent tooth, with open apex.

Methods & Materials: A 10-year-old male patient attended the Endodontology clinic, 7 days after having a dental trauma on tooth 11. During the clinical examination, it could be observed that the tooth was totally intruded, with buccal deviation, cortical vestibular fracture and laceration of the mucous, but in a healing process. Radiographically it was not observed any root fracture. At the first instance, prophylaxis was realized and orientations were provided to the patient. Four months after follow-up and a continuous eruption, pulp necrosis and root resorption had been observed. Endodontic treatment was performed, irrigating the root canal with 1% sodium hypochlorite and a final irrigation with saline solution, and the root canal was filled with calcium hydroxide powder (CH) and saline solution paste. After six days, the canal was emptied and filled with a new CH paste with iodoform, using propylene glycol as vehicle. Two other subsequent changes were performed using the mentioned paste above.

Results: It was not observed any alteration in the radiographies during seven months, and it was not noticed enhancement of the resorption area. An orthodontic device placement was authorized, for providing spaces which had been missing, due to the movement of the surrounding teeth. The canal was definitively filled 6 months later. After this procedure, clinical and radiographic controls were conducted at 9 and 17 months and showed apex tooth closure and absence of resorption.

Conclusion: It was concluded that facing dental intrusion, a tooth eruption may occur again, and the treatment using CH paste may provide resorption control and root apex closure.

REPAIR OF PERFORATING INFLAMMATORY ROOT RESORPTION: A 6-YEARS FOLLOW-UP

Seberol, Erçin*
Ankara, Turkey

Keywords: Root Perforation, Mineral trioxide aggregate, Long Term Follow-up

Purpose: Tooth resorption can be commonly seen after a trauma or an irritation of the tooth pulp, dentin, cementum or periodontal ligament. If the pulp becomes necrotic and infected, bacterial by-products escape through the dentinal tubules and become the stimulus for ongoing phagocytosis, causing inflammation and further root and bone resorption.

After that, the resorptive process can destroy the root and adjacent alveolar bone. When inflammatory resorption is detected, calcium hydroxide (Ca(OH)₂) and mineral trioxide aggregate are oftenly used for the intra-canal dressing because of their high pH and antibacterial properties. Mineral trioxide aggregate is also a material with higher physical properties that can be used for the treatment of apical perforations. In this case report, treatment of apical perforation due to dental trauma and 6-years follow up of this patient are presented.

Methods & Materials: A 9-year-old girl who suffered from subluxation trauma to her upper central teeth has appealed to Ankara University Faculty of Dentistry, Department of Pedodontics after a one-year unsuccessful treatment. Clinically, upper central teeth had non-complicated crown fracture and abscess with fistula formation were seen at upper left central incisor. Radiologically it is detected that upper centrals were immature with open apex. At the left central tooth's apex, an external resorption with pulp perforation was seen. A root canal treatment with calcium hydroxide was planned and then sealing of the perforation side was made by mineral trioxide aggregate (MTA).

Results: Sealing of the apical perforation due to inflammatory root resorption with MTA showed successful clinical and radiological results. The patient was followed up for 6 years. Any negative circumstances like abscess or fistula formation, progressive root resorption or periapical radiolucency were not occurred through the follow-up period.

Conclusion: In the treatment of traumatized teeth intervention at the right time and the use of right techniques are essential. Traumatized teeth can recover from extraction by using appropriate treatment plan.

BIOAGGREGATE PARTIAL PULPOTOMIES IN COMPLICATED CROWN FRACTURES: A CASE SERIES

Sen Tunç, Emine*, Guler, Derya
University of Ondokuz Mayıs
Department of Pediatric Dentistry
Samsun, Turkey

Purpose: The treatment of pulpal injury during the period of root maturation provides a significant challenge for the clinician. The aim of this report to present the partial pulpotomy treatment of complicated permanent crown fractures of four cases by using Bioaggregate with 18-24 months follows up.

Methods & Materials: The four patients aged 8.5-10 years who have a history of dental trauma were referred to pediatric dental clinic within 1-4 hours after accident. Five injured incisor teeth of four patients were treated with partial pulpotomy with Bioaggregate in order to achieve apexogenesis. Then the teeth were restored with a double-seal of glass ionomer cement and composite resin. The patients are still under maintenance therapy and 18-24 months results were presented in this report.

Results: Follow-up examinations showed no crown discoloration and no pulpal and/or periapical pathology 18-24 months after treatment. Also, the root development continued in all of the cases and all pulps remained vital

Conclusion: Bioaggregate may be considered as an alternative partial pulpotomy material for young permanent teeth.

TREATMENT OF HORIZONTAL ROOT FRACTURE USING MTA: A CASE REPORT

Senyigit, Ebru*, Aydinbelge, Mustafa; Pedük, Kübra
Erciyes University
Pediatric Dentistry
Kayseri, Turkey

Keywords: trauma, root fracture, MTA

Purpose: Root fractures occur more frequently in fully erupted permanent teeth with closed apices. Generally the cervical and middle thirds of the roots are affected. The consequences can be complex because of combined damage to the pulp, dentine, cementum, bone, and periodontium. Management of horizontal root fractures and lateral luxation depends on several factors, with the result that various clinical modalities have been suggested.

Methods & Materials: This case report describes the management and 1,5-year follow-up of maxillary central incisor with horizontal root fracture treated with mineral trioxide aggregate (MTA). A 11 year-old girl referred to Erciyes University Pediatric Dentistry Department with traumatized maxillary right incisor tooth. The patient's parent had reported that the trauma occurred at school when she felt down. They were in our clinic 2 hours after event.

Results: In clinic and radiographic examination the traumatized tooth had a complicated crown fracture and horizontal root fracture. After pulp canal treatment with MTA, the tooth followed-up for 20 months. At the end of 15 months, patient came with a swelling in buccal sulcus. After radiographic and clinical examination, resection of apical fragment decided.

Conclusion: There were no pathological symptom after pulp canal treatment with MTA at control appointments in this case. But complaints of swelling and pain started at 15th month. These symptoms finished after resection of apical fragment. However conservative approach is first choice, in some cases apical resection is urgent. In this case, we have regular follow-up.

PULP REVASCULARIZATION OF IMMATURE TOOTH WITH APICAL PERIODONTITIS AFTER TRAUMA

Tarpomanov, Yordan*, Belcheva Ani
Medical University
Pediatric Dentistry
Plovdiv, Bulgaria

Purpose: Pulp necrosis of an immature tooth as a result of trauma or caries arrests further development of the root, leaving the tooth with thin root canal walls and blunderbuss apices. The absence of an apical constriction makes root canal treatment problematic because of the difficulty to obtain a seal with conventional obturation methods. One possible choice for these cases is apexification, but this technique doesn't promote the continued development of the root. Another possibility is to try to make revascularization of pulp canal space and as a result of that – continued root development.

Methods & Materials: A 13 years old girl came to Faculty of Dental Medicine, Plovdiv, Bulgaria with history of pain and swelling in right region of lower jaw. The preoperative X-ray showed that tooth 45 was with incomplete root development and apical periodontitis. During clinical examination we found that this tooth was absolutely intact, but rotated. Electric pulp test manifested nonvital tooth 45. Periodontal probing did not present any pathology. According to the history and clinical findings we proposed that trauma was the main reason for this status. At first appointment we made endodontic access, without using anesthesia to confirm absence of tooth vitality. We found pus-blood exudates in root canal, instead of vital tissue and the patient didn't feel any pain. We irrigated with 2,5%NaOCl, activated with ultrasonic device and placed double antibiotic paste (Ciprofloxacin and Metronidazole) into the root canal for three weeks. The next visit we induced blood clot with K-file number 20 and placed MTA direct over it. One day later we restore this tooth with composite resin. We recommend orthodontic treatment for the patient.

Results: We made X-rays one and two years later. The follow up showed completed root development, thickening of canal walls, apex closure and absence of apical periodontitis. Orthodontic treatment led to correct position of tooth 45.

Conclusion: Revascularization is one possible decision for cases with immature teeth with apical periodontitis after trauma or caries. A lot of advantages of this procedure and a lot of successful cases in the scientific literature make this treatment modality preferable to the traditional apexification treatment.

MULTIDISCIPLINARY MANAGEMENT OF A COMPLICATED CROWN FRACTURE AND AVULSION

Toz, Tugba*, Erkan, Erhan, Gurler, Gokhan
TC Istanbul Medipol University
Department of Restorative Dentistry Department of Endodontics Department of Oral and
Maxillofacial Surgery
Istanbul, Turkey

Keywords: crown fracture, avulsion, reimplanting

Purpose: Dento-alveolar traumas can affect the teeth, soft tissues around the oral region, jaw and temporomandibular joint and it can produce several injuries too. Patients often can lose function and aesthetic. At this moment patient's mental state is badly affected. Avulsion of the teeth is a complex trauma that can affect pulpo-periodontal tissues and alveolar bone. Avulsed tooth should be stored in suitable circumstances for example saline, milk or saliva and should be reimplanted within a few hours so a successful treatment can be achieved. Crown fractures involve enamel, dentin and pulp. This type of fractures are called "Complicated". Small perforation of the pulp can be treated with vital pulp therapy.

Larger perforation of the pulp should be treated with root canal therapy. Coroner restorations can be achieved by several ways. Restoration with fractured part is a part of this techniques. Broken fragment can be bonded to tooth with resin composites and bond agents. The aim of this case report was to present the multidisciplinary treatment of a avulsed teeth and complicated crown fracture.

Methods & Materials: A 21-year-old woman came to Istanbul Medipol University, Faculty of Dentistry, and Department of Restorative Dentistry with a history of traumatic injury to oral region. Clinical examination show that the patient has an avulsed tooth number 21 and a complicated crown fracture tooth number 31. Rest of the anterior teeth are asymptomatic and vital. Radiologic examination has no radiolucent lesion at tooth number 31 too. First of all avulsed tooth was stored in saline solution and alveolar socket of the tooth number 21 was cleaned by saline irrigation. After that reimplanting of the tooth number 21 was performed gently and resin composite splint was performed. Broken part of the crown tooth number 31 was kept by the patient carefully so coroner restoration of the tooth number 31 was achieved by broken part of the crown after the root canal treatment. Resin composite splint was removed after two weeks and root canal treatment was performed.

Results: After two months oral examinations showed that tooth number 11 has no vitality. Thereby root canal treatment was performed tooth number 11 too. After 6 months, oral and radiological examination showed that the patient's functions and masticating were excellent.

Conclusion: The case presentation highlights the importance of the multidisciplinary approach that is essential for the management and outcome of severe dental injuries.

MULTIDISCIPLINARY MANAGEMENT OF MULTIPLE TRAUMATIZED ANTERIOR TEETH: CASE REPORT WITH FOLLOW-UP

Tuloglu, Nuray*, Sari, Saziye; Dagsuyu, Ilhan Metin
University of Eskisehir Osmangazi
Department of Pediatric Dentistry
Eskisehir, Turkey

Purpose: This case report presents the multidisciplinary management of multiple dental traumas in an 11-year-old male who suffered a bicycle accident.

Methods & Materials: Clinical examinations revealed the avulsion of teeth 11 and 12, an uncomplicated crown fracture and lateral luxation of tooth 21, a complicated crown-root fracture tooth 41, and a lateral and intrusive luxation of tooth 31. The informed consent of the patient was obtained prior to the treatment. The tooth 21 was gently repositioned; the avulsed tooth 12 was replanted and a flexible splint was applied for 4 week. The fractured crown fragment of tooth 41 was extracted and endodontic treatment was performed. The tooth 31 was extracted surgically because of extremely displaced in labial direction. 7 days later, pulp was extirpated from 12 and 21; and calcium hydroxide paste was placed for 1-month. BioAggregate was then placed as underwent complete endodontic obturation on teeth 12, 21, and 41; and restored with composite resin after 4 days. Then the fixed orthodontic treatment was performed for organized of the space.

Results: After 18-month clinical and radiographic follow up, the teeth remained symptom-free, no external inflammatory root resorption and no replacement root resorption of tooth 12, 21, and 41 had observed.

Conclusion: In conclusion, BioAggregate can be considered a very effective option for the treatment of traumatized teeth.

REVASCULARIZATION OF NECROTIC IMMATURE PERMANENT CENTRAL INCISOR WITH APICAL PERIODONTITIS

Turk, Tugba*, Kasikci, Ilknur
Ege University, School of Dentistry
Department of Endodontology
Izmir, Turkey

Keywords: Revascularization, MTA, immature tooth

Purpose: Traumatic injuries to an immature permanent tooth may result in interruption of dentin deposition and root maturation. Pulp revascularization is a conservative endodontic treatment that has been introduced in recent years. Revascularization is a valuable treatment in immature necrotic teeth that allows the continuation of root development. The purpose of this study was to describe the successful revascularization treatment of a necrotic immature permanent central incisor with periapical lesion

Methods & Materials: After accessing the pulp chamber of tooth number 21, the root canal was gently debrided of necrotic tissue with a sharp spoon excavator and irrigated for only one third of its length and then medicated with triple antibiotic paste. After 15 days the tooth was asymptomatic. The tooth was accessed, antibiotic paste was removed, bleeding was stimulated to form an intracanal blood clot and mineral trioxide aggregate was placed coronally to the blood clot. Conventional endodontic treatment of tooth number 22 which had a periapical lesion was performed. Then the coronal sealing was made by resin composite. Radiographs were taken regularly to investigate the healing of the periapical lesion and development of the root.

Results: Both teeth were asymptomatic and functional clinically and radiographically during the follow-up period of 2 years. Even if there was a broken file at the periapical region of central incisor, the periapical lesion was completely eliminated, the open apex was closed, and the wall of the root was thickened.

Conclusion: Revascularization of immature necrotic teeth is seemed to be promising treatment alternative to conventional apexogenesis or apexification.

ENDODONTIC MANAGEMENT OF A LATE-REFERRAL CASE OF ROOT FRACTURE

Uyanik, Ozgur*, Nagas, Emre; Cehreli, Zafer C
Hacettepe University, Faculty of Dentistry
Ankara, Turkey

Purpose: These case report describes the management and 2-year follow-up of 2 maxillary central incisors with horizontal root fractures, one treated with mineral trioxide aggregate (MTA) as apical plug and the other treated with root canal treatment where MTA was used at the fracture line.

Methods & Materials: 21 years old female were referred to Endodontics Clinic of Hacettepe University after 10 days from a sports injury. After radiographic and clinical evaluation, 2 maxillary central incisors with horizontal root fractures were observed. One was extirpated due to symptoms of acute pulpitis. No splitting procedures was applied. As a treatment, first the teeth were fixed by a canine-canine splitting. Then, one, previously extirpated, treated by root canal treatment where the fracture line obturated with mineral trioxide aggregate (MTA) while the other treated by MTA as apical plug.

Results: The fixation was removed after 4 months and the teeth followed 24 months.

Conclusion: Root fractures are rare occurrences through all dental injuries. Management of horizontal root fractures depends on several factors, with the result that various clinical modalities have been suggested

ROOT FRACTURES WITH/WITHOUT MULTIPLE DENTOALVEOLAR TRAUMA: TWO LONG-TERM CASES.

Uzel, Ilhan*, Yücel Er, Ceren; Eronat, Nesrin
Ege University Faculty of Dentistry
Pedodontics
Izmir, Turkey

Keywords: Multiple dentoalveolar trauma, root fracture, spontan healing

Purpose: Traumatic dental injuries are relatively frequent accidents that usually involve teeth in the maxillary anterior arch. The occurrence increases during school years. The purpose of this article is to present the emergency and rehabilitation treatments of dentoalveolar trauma in the permanent dentition involving different extensions of enamel-dentin crown fracture, pulp exposure, and root fractures.

Methods & Materials: In this presentation a 9 year old female (case #1) and 11 year old male (case #2) patient referred to the pediatric dentistry clinic with dental trauma in the upper incisors are reported. Both of the accidents had happened in the school and occurred 3 hours and 15 hours ago respectively. The patients were striked in which both of the cases suffered from root fracture. In case #1; three teeth was affected from the dental injury in which two teeth had crown fractures; one with pulpal involvement and one without other than the tooth with root fracture. In case #2 root fracture was observed in one tooth. In both dental injuries fracture line was in the middle of the 1/3 rd of the root. In the initial visit immobilizing was performed with resin and wire splint in both of the cases. In case #1 Cvek amputation was performed as well to the tooth with complicated crown fracture and composite restoration to the tooth without pulpal involvement. In the recall visit -after three months- the fractured tooth with enamel-dentin crown fracture gave no response to the vitality tests and root canal treatment was performed.

Results: In both root fractured teeth long-term follow-ups was performed in case of complications (3.5 years for the case #1 and 1.5 years for the case #2). No complications in both cases were observed in the involved teeth and treatment outcomes in the teeth with root fractures showed successful spontaneous healing.

Conclusion: In the two case reports with root fractures and in the case report with more than one tooth involved, it is emphasized the importance of emergency treatment and efficient clinical decisions as well as long-term follow-up in the traumatic dental injuries.

MULTIDISCIPLINARY TREATMENT APPROACH OF A TRAUMATIZED PERMANENT ANTERIOR TEETH

Vardar Gürlek, Ceren*, Gürlek, Önder; Toman, Muhittin; Ertugrul, Fahinur.
Ege University Faculty of Dentistry
Pedodontics
Izmir, Turkey

Keywords: crown-root fracture, replantation, rotation

Purpose: A number of techniques, such as crown lengthening, orthodontic or surgical extrusion have been described for treatment of crown root fractures. However, these techniques might have limitations due to the extended time required for treatment and esthetic considerations. Intentional replantation with 180° rotation can be an alternative treatment option to overcome these problems. The aim of this case report was to present the management of a complicated crown-root fracture by intentional replantation with rotation, which resulted in favorable esthetic outcomes.

Methods & Materials: A 12-year-old girl applied to our clinic due to dental trauma with a complicated crown-root fracture of his maxillary right central incisor. Clinical and radiographic examination revealed that the tooth margin was subgingival and extended apically to the alveolar crest on the palatal aspect. To protect the crown-root ratio, the tooth was replanted in a slightly extruded position with 180° rotation to expose the fracture line supragingivally. For initial stabilization, sutures and resin splint (Superbond C&B SunMedical, Moriyama, Japan) were placed. Pulp extirpation and calcium hydroxide dressing of the root canal of maxillary right incisor were carried out immediately. The sutures were removed 1 week after replantation. The canal was obturated with gutta-percha and splint was removed 2 weeks after the operation. A ceramic crown (IPS e-max; Ivoclar Vivadent) was fabricated according to manufacturer's instructions and was cemented with an adhesive luting system (Variolink 2; Ivoclar Vivadent).

Results: At the 12-month recall, no symptoms of periapical pathology, abnormal mobility or root resorption were observed. Esthetic outcome was satisfactory for the patient.

Conclusion: Multidisciplinary approach can be suggested as a treatment choice with better functional and aesthetic results in patients who have severe crown-root fractures.

INVASIVE CERVICAL RESORPTION: A CASE REPORT

Yalçın, Eda Didem*, Uzunoglu, Emel, Nagas, Emre, Görduysus, Melahat, Avcu, Nihal
Dentistry of Hacettepe
Dentomaxillofacial Radiology Endodontics
Ankara, Turkey

Keywords: cervical resorption, invasive resorption, dental trauma

Purpose: Invasive cervical resorption is a relatively uncommon form of external root resorption. Etiologic factors include trauma, orthodontic treatment, intracoronary bleaching, and inflammation, but invasive cervical resorption is often idiopathic. There may be no external signs, and the resorptive condition is often detected by routine radiographic examination. Radiographic features of lesions vary from well-delineated to irregularly bordered mottled radiolucencies and these can be confused with dental caries. In this case report; clinical and radiologic findings are presented of 28-year-old female patient's, free of symptoms, right maxillary second molar tooth with invasive cervical resorption.

Methods & Materials: 28-year-old female patient was attended our clinic for routine dental overhaul and radiographic examination showed that distal surface of right maxillary second molar, a noticeable cervical defect was revealed then evaluation by cone beam computed tomography was done. The defect was very close to the pulp and included fibrovascular tissue derived from the periodontal ligament.

Results: The resorptive lesion diagnosed as invasive cervical resorption and root canal treatment was performed. Where the lesion is visible, the clinical features vary from a small defect at the gingival margin to a pink coronal discoloration of the tooth crown resulting in ultimate cavitation of the overlying enamel which is painless unless pulpal or periodontal infection supervenes.

Conclusion: Invasive cervical resorption is entirely uncommon entities and the etiology is poorly understood. If the reason for the disorder is investigated, it is found that the patient's impacted right maxillary third molar tooth extracted traumatically one year ago. This condition may be caused by dental trauma greatly. Cone beam computed tomography has enhanced radiographic diagnosis and it provides greater three-dimensional geometric accuracy than conventional radiography also.

ENDODONTIC MANAGEMENT OF MAXILLARY INCISORS WITH HORIZONTAL ROOT-FRACTURES

Yalcinkaya, Nil*, Kaval, Mehmet Emin; Gumus, Pinar; Caliskan, Mehmet Kemal
Ege University School of Dentistry
Department of Endodontics
Izmir, Turkey

Keywords: horizontal root fractures, mta plug

Purpose: To describe the treatment approach of maxillary central and lateral incisors with horizontal root fractures.

Methods & Materials: A 33 year-old male patient was referred to our clinic one day after traffic accident. Clinical and radiological examination revealed that there were horizontal root fractures in maxillary right lateral and left central incisors. Under local anesthesia the coronal segments were repositioned and stabilized using wire and composite splint for 8 weeks. Two months later, left central incisor did not respond to vitality test and it was decided to perform root canal treatment. During the root canal treatment procedure, apical part of the involved tooth was vital, hence root canal preparation and obturation was performed at the coronal part in conjunction with placement of 5 mm of an MTA plug.

Results: Clinical examinations at 1-year follow-up, showed that the lateral and central incisors were asymptomatic. Lateral incisor responded positively to electrical pulp testing, and a significant healing was observed at the fracture line of left central incisor.

Conclusion: Repositioning and immobilizing of fractured fragments play an important role on treatment procedure. Placing MTA plug at fracture line was found to affect the prognosis root fractured tooth positively.

IMMEDIATE SELF-REPLANTATION OF AN AVULSED TOOTH AND MULTIDISCIPLINARY-MANAGEMENT AFTER 10-YEARS

Yilmaz, Ayca*, Yilmaz, Serdar., Tak, Onjen., Karagoz-Kucukay Isil
Istanbul University
Endodontics
Istanbul, Turkey

Keywords: avulsion, immediate replantation, multidisciplinary treatment

Purpose: To report a case with immediate self-replantation of an avulsed tooth but without any dental care and follow-up. After 10 years, multidisciplinary step-by-step treatment planning and management of this complicated case was presented.

Methods & Materials: A 20-year-old male was referred to the Department of Endodontics, Faculty of Dentistry, Istanbul University with discoloration of maxillary right central incisor (tooth 11) and a large palatal abscess. He had a history of impact-trauma 10 years previously. At the time of the injury, his completely avulsed tooth 11 had been immediately placed back in the socket/replanted by his school teacher who had a limited knowledge about tooth avulsion. The patient had not sought for any dental care after all. Extraoral examination revealed no signs or symptoms. Intraoral examination revealed a large abscess at the maxillary right palatal quadrant and discoloration of tooth 11. Except for tooth 11, neither of teeth 21, 12, 13 and 14 showed mobility or tenderness to percussion nor responded negatively to sensibility tests. Based on clinical and radiographic findings, the diagnosis of a large cystic-lesion was established, and reconfirmed using Cone-Beam Computed Tomography (CBCT). The initial treatment plan consisted of endodontic treatments of teeth 11, 12, 13, 14, 15 due to the involved localization in the surgical area, and the enucleation of the cystic-lesion. The patient was informed about the possibility of extraction for teeth 11 and 12 due to the loss of supporting bone tissue, and his informed consent was obtained. Since a quick healing at the palatal region following the endodontic treatment of tooth 11 was established, a conservative treatment option was preferred, and the decompression of the lesion was performed. In one-year follow-up with CBCT resolution of the lesion was evident. Teeth 12 and 13 were then endodontically treated, and the lesion was enucleated.

Results: 2-year follow-up after surgery showed successful clinical and CBCT results.

Conclusion: Replantation time is the most critical factor in traumatic dental avulsions. To ensure a favorable outcome, the tooth should be replanted within the first 15-20 minutes. Many avulsed permanent teeth in school children can be saved by immediate replantation if school teachers have knowledge about how to manage an avulsed tooth. Follow-up period of the replanted tooth is also important for successful results. Conservative multidisciplinary treatment instead of invasive surgery may be a better treatment option in such kind of cases.

ENDODONTIC MANAGEMENT OF DOUBLE PINK TOOTH WITH INTERNAL RESORPTION

Yilmaz, Neslihan*, Çiçek, Ersan
Bülent Ecevit University, Faculty of Dentistry
Endodontics
Zonguldak, Turkey

Keywords: Pink Spot, Internal Resorption, Trauma

Purpose: This case report presents the endodontic management of double “pink tooth” maxillary incisors associated with internal resorption. Tooth resorption is a common sequel which follows injuries or irritation to the periodontal ligament and/or tooth pulp. Resorption can be classified as internal and external resorption. Internal resorption has been discussed as a rare occurrence as compared to external resorption. The crown of the tooth clearly shows a reddish spot called as “pink spot” which represents the granulation tissue, showing the resorbed area of the tooth.

Methods & Materials: A 18-year-old male who interested in taekwondo sport came to our clinic due to esthetic problem causing reddish anterior teeth. Clinically, there was no symptom but maxillary central incisors were appeared reddish. Radiographically, there was extensive widening in the pulp chambers. The teeth were extirpated in the same appointment and dressed with calcium hydroxide (Ca(OH)₂) and recalled for second appointment after two weeks. At the second appointment the teeth were obturated with guttapercha and restored with resin composite.

Results: The teeth with internal resorption have seen healing after endodontic therapy. After 12 months follow-up patient was clinically free-symptom and satisfactory with his visual.

Conclusion: This case point out that internal resorption can develop at varying times after dental injuries and can cause the destruction of the mineralized tissues, thus emphasizing the need to establish periodic patient recalls.

A MULTIDICIPLINARY APPROACH FOR HORIZONTAL ROOT FRACTURE: CASE REPORT

Yücel Er, Ceren*, Ergin, Ecem; Gürlek, Önder; Eden, Ece
Ege University Faculty of Dentistry
Pedodontics
Izmir, Turkey

Keywords: Root fracture, MTA, apical resection

Purpose: Root fractures are 0,5-7% of all dental injuries in the permanent dentition. This case describes a multidisciplinary approach for treatment of the horizontal root fracture of a maxillary right central incisor.

Methods & Materials: A 12-year-old female patient was referred after suffering trauma to the right maxillary central incisor within 5 hours. Radiographic evaluation revealed a horizontal fracture in the middle third of her maxillary right central incisor. Clinical evaluation revealed mobility of the coronal segment. The gingiva of the tooth was damaged.

Under local anesthesia the coronal segment of the tooth was repositioned and splinted for 2 months. The coronal segment was extirpated within 3 weeks and the apical segment was removed with apical resection because of the lesion. Then the coronal segment was treated using MTA only since the part of the root which left was very short. Devital bleaching was made in her twelfth month examination for esthetical reasons.

Results: The tooth was followed up to two years. During this time there was no clinical or radiographic symptoms of failure .

Conclusion: Root fractures are difficult to treat and may result with poor prognosis, even tooth loss. This can be avoided with a multidisciplinary approach.

REVASCULARIZATION OF IMMATURE NECROTIC TEETH WITH PLATELET PELLETS: CASE SERIES

Zencirli, Ilkay*, Ulusoy, Ayca Tuba; Zencirli, Ilkay; Ozveren Neslihan
Faculty of Dentistry, University of Ondokuz Mayıs
Department of Pediatric Dentistry
Samsun, Turkey

Purpose: Regenerative endodontic treatment has been gained great attraction for the treatment of necrotic immature permanent teeth instead of conventional endodontic procedures. Regenerative endodontic procedures include revascularization by stimulation of a blood clot from the periapical tissues or implantation of platelet rich plasma into the root canal. The purpose of this case series was to present the regenerative endodontic treatment outcomes of the necrotic immature three permanent teeth with platelet pellet which has higher platelet content than platelet-rich plasma.

Methods & Materials: Three immature teeth of three patients with necrotic pulp were treated via the revascularization protocol using irrigants, a calcium hydroxide paste, placement of platelet pellet and a coronal seal of mineral trioxide aggregate and composite.

Results: After six-month follow-up all three teeth showed continued root development without any clinical symptoms.

Conclusion: On the basis of short-term results of the present cases, it appears that platelet pellet may be a potentially ideal scaffold for the revascularization protocol of immature necrotic teeth.

Research Posters- Endodontics & Periodontal Aspects
EFFICACY OF DIFFERENT AGITATION TECHNIQUES ON CALCIUM HYDROXIDE REMOVAL

Akcay, Merve*, Arslan, Hakan; Saygili, Gokhan; Akcay, Merve; Gok, Tuba; Capar, Ismail D; Ertas, Huseyin
Izmir Katip Celebi Universtiy
Pediatric Dentistry
Izmir, Turkey

Keywords: PIPS, ultrasonic, agitation

Purpose: Calcium hydroxide (Ca(OH)₂) is used in root canal treatment because of the good antimicrobial properties. Complete removal of Ca(OH)₂ placed inside the root canal prior to obturation of the root canal system is recommended. However, it is difficult to completely remove Ca(OH)₂ from root canals using irrigating solutions alone. The aim of this study was to evaluate the effect of various techniques including laser-activated irrigation using an erbium:yttrium-aluminum-garnet (Er:YAG) laser with a novel tip design (photon-induced photoacoustic streaming, PIPS), ultrasonic, sonic, and needle irrigation on the removal of Ca(OH)₂ from an artificial groove created in a root canal.

Methods & Materials: Forty-eight extracted single-rooted teeth were prepared using ProTaper rotary instruments (Dentsply, Ballaigues, Switzerland) up to size #40. After the specimens had been split longitudinally, a standardized groove was prepared in apical part of one segment and was filled with Ca(OH)₂ powder (Kalsin; Spot Dis Deposu A.S., Izmir, Turkey) mixed with distilled water. Each tooth was reassembled and the apices closed with wax. The specimens were irrigated for 60 s as follows: needle irrigation using 17% EDTA, PIPS using 17% EDTA, ultrasonic irrigation using 17% EDTA, and sonic irrigation (EndoActivator) using 17% EDTA. The root segments were then disassembled and the amount of remaining Ca(OH)₂ evaluated under a stereomicroscope at 25× magnification, using a four-grade scoring system [Score 0: Groove was empty; score 1: Ca(OH)₂ was present in less than half of the groove; score 2: Ca(OH)₂ covered more than half of the groove; score 3: The groove was completely filled with Ca(OH)₂]. The data were evaluated statistically using Kruskal-Wallis and Mann-Whitney U tests with Bonferroni correction at 95% confidence level (P = 0.05).

Results: The percentages of complete removal of medication (Score 0) were 100% for PIPS, 50% for ultrasonic irrigation, 0% for needle and sonic irrigation. PIPS was superior in removing Ca(OH)₂ as compared to the needle irrigation (P < 0.001), sonic irrigation (P < 0.001), and ultrasonic irrigation (P = 0.036). Ultrasonic irrigation was superior to needle irrigation (P = 0.006) and sonic irrigation (P = 0.048). There was no statistically significant difference between needle and sonic irrigation (P = 0.215).

Conclusion: PIPS provided complete removal of Ca(OH)₂ in all specimens. This technique could be beneficial in endodontics for activating irrigating solutions. Ultrasonic irrigation enhanced the Ca(OH)₂ removal capacity of irrigating solution but did not provide complete removal.

THE DIFFERENTIATION ABILITY OF PERIODONTAL LIGAMENT CELLS

Bag, Irem*, Can, Alp & Yildirim, Sibel
Selcuk University, Faculty of Dentistry
Department of Pedodontics
Konya, Turkey

Purpose: Replantation of the avulsed permanent teeth is an emergency and rehabilitation treatment with many unpredictable but possible complications. While periodontal ligament (PDL) cells are often left on most of the root surface, inappropriate posttraumatic management can cause prolonged exposure of the root surface to the external environment. Several factors determine the treatment prognosis of avulsion with minimal to severe type of complications, depending on the conditions between avulsion occurrence and replantation. The exact mechanism(s) of the development of root resorption after replantation of avulsed teeth is still unclear. Although majority of the previous studies have focused on the effect of the storage media and storage time on the periodontal ligament (PDL) cells, keeping PDL and pulp cells alive may not be sufficient to improve the long-term prognosis and survival of those teeth.

The purpose of this study was to evaluate whether the differentiation potential of PDL cells would affect osteoclastogenesis and osteogenesis.

Methods & Materials: For this purpose PDL tissue and PDL cells were obtained from healthy extracted human premolars. Several marker proteins expressed by osteogenic cells (Runx2 and alkaline phosphatase), osteoclastogenic cells (RANKL) or fibroblasts (alpha-smooth muscle actin, type XII collagens) were analyzed in cryosections and cultured cells. It was anticipated enzymatic and immunochemical localization of specific markers in PDL tissue and cultured cells.

Results: As a result, the study showed that the obvious differential potential of PDL cells will effect the preference of storage media of avulsed teeth.

Conclusion: Conclusively, the storage media do not only survive the PDL and pulp cells alive, but also maintain their physiological status resembling to the natural dental fibroblasts.

THE EFFECT OF DOXYCYCLINE ON TOOTH DISCOLORATION IN REGENERATIVE ENDODONTICS

Deniz Sungur, Derya*, Aksel, Hacer ; Yilmaz, Zeliha
Hacettepe University, Faculty of Dentistry
Endodontics
Ankara, Turkey

Keywords: discoloration, doxycycline, minocycline

Purpose: To evaluate the coronal discoloring effect of doxycycline in triantibiotic paste (TAP) used during regenerative endodontic treatment.

Methods & Materials: Freshly extracted 40 human maxillary incisors were used. The teeth were sectioned 3 mm coronal and 5 mm apical of cemento-enamel junction. Root canals were enlarged by gates – glidden drills. After the removal of smear layer, samples were assigned into four experimental groups (n=10). Samples were dressed with only minocycline (group 1, only doxycycline (group 2), TAP containing minocycline, ciprofloxacin and metronidazole (group 3) and TAP containing doxycycline, ciprofloxacin and metronidazole (group 4). Samples were stored in humid and dark medium. Color changes were measured by a colorimeter and L*, a* and b* values before treatment (baseline) and after 5 and 10 days after treatment were obtained and ΔE value, representing the colour change was calculated. The data was statistically analyzed by 1-way ANOVA and repeated measures of ANOVA tests. Human perceptibility threshold was set to 3.7.

Results: No difference was found amongst the baseline L*, a* and b* values of the test groups ($p > .05$). Group 4 showed the highest discoloration after five days and this was statistically different than group 1 ($p < .05$). After ten days group 3 showed the highest discoloration but no statistical difference was found amongst the groups ($p > .05$).

Conclusion: Minocycline and doxycycline alone or within TAP induced severe and similar coronal discoloration exceeding the human perceptibility threshold.

THE EFFECT OF RETROGRAD FILLING MATERIALS ON ACCURACY OF TRIAUTO-ZX

Dinçer, Asiye Nur*, Üstün, Yakup. Uzun, Özgür. Er, Özgür. Dinçer, Asiye Nur*. Yalpi, Fatma
Kayseri, Turkey

Purpose: To evaluate the effect of different retrograd filling materials on accuracy of an apex locator integrated device (TriAuto ZX-J. Morita USA) during retreatment procedures of root-end resected teeth

Methods & Materials: A total of 60 extracted maxillary incisor teeth were used. Access cavities were performed, and the teeth were decoronated at the cemento-enamel junction. The true working length (TL) was determined by visual examination. All root canals were prepared up to ProTaper F3 rotary (Dentsply) instrument set. Irrigation was performed with 2.5% NaOCl. Canals were dried and then filled with lateral condensation of gutta-percha cones and AH Plus sealer to the TL. 3 mm from the apical end of the root was resected by using a diamond disk as close to the 0-degree bevel angle. After the apical resection, all roots were measured externally and recorded as resected length (RL). Retrograd cavities were prepared with an ultrasonic device using a retrograd cavity tip. All retrograd cavities length was adjusted to 3 mm. Then roots were randomly divided into 4 groups according to the retrograd filling materials: Group 1 (G1): Amalgam, G2: MTA, G3: Super EBA, G4: Bioaggregate. After setting of the retrograd materials, coronal seal was removed, all samples and lip clips of the devices were mounted in an alginate model. Tri Auto ZX device and ProTaper retreatment files were used for retreatment procedure. Tri Auto ZX device was set to "Auto Reverse mode" and negotiate into the root canal, the operator stopped the device when the auto reverse action began and the rubber stopper of the file was fixed with a flowable composite and a radiograph was taken with parallel cone technique. The distance between file tip and root canal ending was determined as A. The distance between file tip and filling material determined as B and correlation between file tip position and retrograde filling material thickness was determined as C.

Results: In comparisons at variable A the Amalgam group was significantly superior to the MTA, Super EBA and Bioaggregate groups ($p < 0.05$). In comparisons at variable B the Amalgam group was significantly superior to the MTA, Super EBA and Bioaggregate groups ($p < 0.05$). In comparisons at variable C; there were no significant differences among the groups.

Conclusion: When TriAuto-ZX used retreatment of root end resected teeth except amalgam all the other materials did not differ among each other in means of the variables compared in the present study.

UNDERSTANDING ENDODONTIC RETREATMENT IN DENTAL PRACTICES

Ehsen, Sana*, Raza Khan, Farhan
The Age Khan University and Hospital
Department of Surgery (Operative Dentistry)
Karachi, Pakistan

Keywords: Endodontic Retreatment, dental practice, root canal failure

Purpose: Despite the recent improvements in endodontic instruments and techniques, incidence of endodontic failure still ranges between 2% and 40%. To salvage such failed tooth, endodontic retreatment is often warranted. Although, some retreatment guidelines are there but on many areas there is no consensus on retreatment protocols/ procedures, thus, dentists follow different retreatment protocols. Our study objectives were: 1. To assess endodontic retreatment preferences and decision making among practicing dentists of Karachi. 2. To compare retreatment preferences of dentists with varying clinical experience.

Methods & Materials: A questionnaire was distributed by hand to dental teaching faculty at various institutions of Karachi and at some private practices. The questions gained information on aspects like: number of retreatment cases seen per month, most frequent cause of retreatment encountered in practice, use of medicaments & solvents, number of visits for retreatment, antibiotic prescription etc. Descriptive statistics & frequency distribution were computed. Chi-square test was applied to compare the difference between dentists having less than 5 years versus more than 5 years of clinical experience. Level of significance was kept at 0.05.

Results: We received only 58 forms out of 100 sent. Thus, the response rate was 58%. The most commonly reported reason for endodontic retreatment was under prepared/ under filled canals. Gates glidden drills and hand instruments were the most commonly used endodontic instruments. Potaper was the preferred rotary system. 69% of the dentists received 1-3 retreatment cases per month. Dentists with an experience of >5 years preferred 2 visits for the completion of endodontic retreatment. 83.5% of the dentists preferred using solvents while carrying out endodontic retreatment. Chloroform was the most preferred solvent. Calcium hydroxide was the most preferred intracanal medicament. There is no statistically significant difference between the dentists for endodontic retreatment and extraction decisions.

Conclusion: It's alarming to note that almost half of the dentists reported inappropriate decision making in retreatment. Nearly 45% participants were confined to hand instruments only and 15% were not employing any solvent. This shows that in general, retreatment is not done as per the accepted standards.

VERTICAL FRACTURE RESISTANCE OF RETREATED TEETH USING DIFFERENT INSTRUMENTATION TECHNIQUES

Helvacioğlu-Yigit, Dilek*, Yılmaz, Ayca**, Sarıdag, Serkan***, Avcu, Egemen****, Yıldırım, Yasemin****
*Department of Endodontics, Kocaeli University, Faculty of Dentistry **Department of Endodontics, Istanbul University, Faculty of Dentistry ***Department of Prosthodontics, Kocaeli University, Faculty of Dentistry ****Department of Mechanical Engineering, Kocaeli University, Faculty of Engineering
*Endodontics ** Endodontics *** Prosthodontics **** Mechanical Engineering
Kocaeli, Turkey

Purpose: The aim of this study was to evaluate resistance to vertical root fracture (VRF) of retreated roots using rotary and hand instrumentation.

Methods & Materials: Forty five extracted maxillary incisor teeth were decoronated to standardize the root lengths to 16mm. Root canals of specimens were prepared using ProTaper Universal (PTU) rotary instruments and obturated using cold lateral condensation technique with gutta-percha and AHPlus sealer. Teeth were randomly allocated to three groups (n=15). First group was not retreated as a control group. The other two groups were retreated using either PTU retreatment instruments or hand files, followed by obturation using cold lateral condensation technique. The periodontal ligament of filled roots was simulated using elastomeric impression material. Specimens were embedded into self-curing acrylic and subjected to a loading force (1.0 mm/min.) using a metal sphere of 2mm diameter applied vertically in a universal testing machine until the root fractured. The data were recorded in Newtons and statistically analyzed (Kruskal-Wallis and Dunn multiple comparison tests, $p < 0.05$).

Results: Retreated groups revealed decreased fracture resistance of roots compared with control group ($p < 0.05$). However, the difference in the median values among rotary and hand instrumentation was not significant.

Conclusion: Within the limitations of this study, VRF risk increases in retreated teeth regardless of the instrumentation technique used.

FRACTURE RESISTANCE OF VERTICALLY FRACTURED ROOTS BONDED WITH AN ADHESIVE

Özcan, Aysegül*, Sübay, Melike Ordulu, Sübay, Rüstem Kemal
Istanbul University, School of Dentistry
Endodontics & Oral Maxillofacial Surgery
Istanbul, Turkey

Purpose: Bonding of vertically fractured and endodontically treated teeth appears as a promising treatment technique for these hopeless cases. Effect of bonding treatment on resistance of roots which were fractured vertically has not been studied in detail. The objective of this study was to investigate fracture resistance of bonded roots which had simulated vertical fractures.

Methods & Materials: Sixty roots were randomly divided into three groups, 20 in each. Group 1 served as control group and received no treatment. In group 2, roots were shaped using NiTi rotary files and filled with laterally condensed gutta-percha and a sealer. Roots in group 3 were filled like in group 2 and then they were fractured vertically. Fractured root parts were bonded using a self-cured adhesive agent. Apical 4mm part of each root was embedded in resin blocks, exposing coronal 9mm part. Each root was then subjected to a slowly increasing vertical load (1mm/min) until fracture occurred. Load at failure was measured and expressed in newtons. Data were statistically analyzed by using one-way analysis of variance and Tukey-Kramer multiple comparison tests.

Results: Mean fracture resistance values were 1031 ± 205.13 N for group 1, 908.711 ± 216.57 N for group 2 and, 528.274 ± 244.98 N for group 3. Statistically significant resistance differences were seen between the study groups ($p < 0.001$). Multiple comparisons showed that group 3 had significantly lower fracture resistances than both groups 1 and 2 ($p < 0.001$). No statistically significant difference was found between groups 1 and 2 ($p > 0.05$).

Conclusion: Incidence of VRFs following compressive force application ranked as bonded roots > obturated roots > intact roots. Endodontically treated roots may show closer fracture resistance values to intact roots. Bonded roots demonstrated significantly lower resistance values than both intact and obturated roots. Replantation of vertically fractured teeth after bonding with an adhesive resin may not be a treatment technique serving at long-term periods but may be used as a provisional modality. Key words : fracture resistance, adhesive resin, vertical root fracture, replantation.

THE EFFECT OF DIFFERENT IRRIGATION ACTIVATION TECHNIQUES ON BOND STRENGTH

Sahin, Naciye Nur*, Akçay, Merve; Arslan, Hakan; Mese, Merve; Sahin, Naciye Nur
Izmir Katip Çelebi University
Pediatrics
Izmir, Turkey

Keywords: Laser-activated-irrigation, bond-strength, ultrasonic

Purpose: To investigate the effect of various irrigation activation techniques, including laser-activated irrigation using an erbium:yttrium-aluminum-garnet (Er:YAG) laser with a novel tip design (photon-induced photoacoustic streaming, PIPS), on the bond strength of an epoxy resin-based sealer to root dentin.

Methods & Materials: Seventy-two single-rooted human mandibular premolars were prepared using the rotary instruments to size 40. The specimens were then randomly divided into four groups according to the final irrigation activation technique used as follows ($n=18$): conventional irrigation (CI), laser-activated irrigation with PIPS (LAI-PIPS), passive ultrasonic irrigation (PUI), and sonic irrigation (SI) with 5 mL of 17% EDTA and 2.5% NaOCl. The root canals were then obturated with a single gutta-percha cone and AH Plus Jet sealer (Dentsply DeTrey, Kontanz, Germany). Each specimen was sectioned perpendicular to its long axis using a precision saw (Isomet 1000; Buehler, USA) and three slices were obtained from each tooth ($n=54$ for each group) at depths of 4, 7, and 10 mm (apical, middle, coronal) and approximately 1 ± 0.1 mm thickness. A push-out test was used to measure the bond strength between the root canal dentin and the sealer with a universal test machine (AGS-X, Shimadzu Corporation, Tokyo, Japan). After the test procedure, each specimen was visually examined under a stereomicroscope at $32\times$ magnification to evaluate failure mode. Data were analyzed using two way analysis of variance (ANOVA) and LSD posthoc tests ($P = 0.05$). The failure mode data were statistically analyzed using a chi-square test ($P = 0.05$).

Results: The LAI-PIPS and PUI resulted in higher push-out values compared to CI and SI ($P < 0.05$). There were no statistically significant differences between CI and SI ($P=0.978$), and between LAI-PIPS and PUI ($P=0.051$). There was a statistically significant interaction between the final irrigant activation techniques used and root canal thirds ($P < 0.05$). A chi-square test revealed no significant differences in the failure mode within the groups ($P > 0.05$). Adhesive failure between the resin sealer and dentin was the most frequent type of failure mode in all the groups.

Conclusion: Within the limitations of the present study, it can be concluded that the use of laser activated irrigation with a novel tip design (PIPS) and PUI can provide higher bond strength of resin sealer to root dentin compared to CI and SI techniques.

THE EFFECT OF MTA ON FRACTURE STRENGTH OF IMMATURE TEETH

Salem Milani, Amin*, Rahimi, Saeed ; Ghasemi Tabegh, Fatemeh ; Asghari Jafarabadi, Mohammad
Tabriz University of Medical Sciences
Tabriz, Iran

Keywords: Calcium Enriched Mixture Cement, Fracture strength, Immature teeth

Purpose: Immature permanent teeth may become necrotic as a result of traumatic injuries or caries. Endodontic and restorative treatments of these teeth are still a challenge in dentistry. Strengthening these immature teeth has been of concern for many years, and different materials and techniques have been examined in this respect. The ability of mineral trioxide aggregate (MTA) to strengthen the tooth structure has been studied with contradictory results, and there is a lack of data in the case of Calcium enriched mixture (CEM) as a novel endodontic biomaterial. The aim of the present study was to evaluate the reinforcing effect of MTA and CEM cement on simulated immature teeth.

Methods & Materials: This ex vivo study was carried out on a total of 46 human maxillary incisors. Access cavities were prepared. Five teeth were randomly selected as negative control. Rotary files and peeso reamers were used to enlarge the canals. The prepared specimens were randomly assigned into three experimental (n=12) and a positive control (n=5) groups. In group 1 and 2, the canals were filled with MTA or CEM cement, respectively. In group 3, a 5-mm MTA plug was placed, and the remainder of the canal was filled with composite resin. The canals of the positive control were kept unfilled. After 6 months, the teeth were tested for fracture strength in a universal testing machine. The groups were compared using Univariate analysis of variance (ANOVA) followed by Duncan multiple range post hoc test.

Results: The fracture strength of MTA+composite and CEM groups was significantly greater than that of both control groups ($P<0.01$). MTA group also showed significantly higher strength values than positive control ($P<0.05$). However, the differences among the three experimental groups were not statistically significant ($P>0.05$).

Conclusion: After 6 months, MTA and CEM cement exhibit distinct reinforcing effect on immature teeth.

PULPAL EXPRESSION OF OSTEOPONTIN VARIANTS AND DENTAL CARIES

Sattari, Mandana*, Mohammadi, Aram; Dibaj; Masoomeh; Yeganeh, Farshid
Shahid Beheshti University of Medical Sciences
Immunology
Tehran, Iran

Purpose: Pulpitis is an inflammatory condition of dental pulp which in turns is due to microbial invasion during dental caries, tooth filing or trauma. Inflammatory stimuli induce activation of inflammatory cells, which in turn causes the inflammatory changes in dental pulp. Since the precise roles of immune mediators in pathogenesis of pulpitis are not well understood, so the aim of this study was to compare the pulpal expression of osteopontin variants in teeth with different degrees of dental caries.

Methods & Materials: Sample collection was done from individuals with healthy teeth, teeth with superficial, moderate and deep carious lesions (20 samples for each group). All groups were similar in age, sex, and tooth position. After RNA extraction and synthesis of cDNA from each sample, the expression of different variants of osteopontin was measured by Real-Time PCR technique.

Results: It is shown that the expression of variant 2 of osteopontin in healthy teeth group was more than different kinds of dental caries groups ($p<0.05$). There was no difference between different kinds of dental caries regarding the expression of osteopontin variants ($p>0.05$). We also could not find any statistical difference regarding expression of other variants of osteopontin between healthy and carious teeth ($P>0.05$).

Conclusion: Based on our results and also the results of previous studies, which indicated that osteopontin has some role in protection of the periapical tissues or in regeneration of different tooth structures, it is concludes that osteopontin, specially variant 2 of osteopontin, has some protective role for dental pulp against inflammatory stimuli.

EFFECT OF CALCIUM HYDROXIDE ON PREFABRICATED FIBER POST RETENTION

Simsek Derelioglu, Sera*, Pelin Çelik Dursun, Burak Çarikçioglu, Esra Yanar, Yücel Yılmaz
Atatürk University
Department of Pediatric Dentistry
Erzurum, Turkey

Purpose: To evaluate the effect of calcium hydroxide on the push-out test of prefabricated fiber posts bonded with two resin cements on permanent canines, different pre-treatment methods applied on.

Methods & Materials: For this study, 40 human permanent maxillary canines were used. Crowns were sectioned at the cementum-enamel junction using a diamond disc. Roots were covered with nail varnish in order to prevent dye penetration. All teeth root canals were enlarged in a standard way, irrigated with 0.05% sodium hypochlorite and 0.9% saline solution and dried with paper points. Ten of the 40 teeth were used for the control group and the remaining 30 were used for the study groups. No medication has been applied in canals in the control group. Pure calcium hydroxide was injected into apical foramens with a special syringe and condensed to the root canals and walls of the teeth in the study groups. Roots were stored in distilled water at 37 °C for 30 days. Then, calcium hydroxide was removed from the root canals and canals were irrigated and dried. The roots selected for both control and study groups were divided into four main groups. Created main groups were divided into two sub-groups. Group-1: Control Group: Group-1 a: Bifix QM+Rebilda Fiber Post; Group-1b: Unicem Applicap + Rebilda Fiber Post Group-2: Study Group: Group-2 a: Calcicure+Bifix QM+Rebilda; Grup-2b: Calcicure+Unicem Applicap +Rebilda Group-3: Study Group: Group-3 a: Calcicure+dual cure bonding agent (Futurabond U, Voco)+Bifix QM+ Rebilda; Grup-3b: Calcicure+Futurabond U+ Unicem Applicap+Rebilda Group-4: Study Group: Group-4 a: Calcicure+34.5% phosphoric acid+ Futurabond U+Bifix QM+Rebilda; Grup-4b: Calcicure+34.5% Phosphoric asit+Futurabond U+Unicem Applicap+Rebilda All examples were thermocycled. 3 dentin discs of 2 mm thick each were sliced from apical, middle and coronal portions of all samples. Each disc was subjected to the push -out tests with a crosshead speed of 0.5 rpm. Obtained data were statistically analyzed with Two - Way ANOVA and Duncan post-hoc tests.

Results: The F value for root canal preparation of the treated canal dentin surface was statistically significant but the value for resin cements was not.

Conclusion: Within the limitation of this study, no resin cements but different pre-treatment methods might be effective on the bonding strengths of the prefabricated fiber posts cemented to the root canal dentin. Additionally, inserting calcium hydroxide into the canal root temporarily might not affect the bonding strength.

FRACTURE RESISTANCE OF ROOTS OBTURATED WITH FOUR DIFFERENT SEALERS

Sübay, Rüstem Kemal*, Ferah, Fusun
Istanbul University, School of Dentistry
Endodontics
Istanbul, Turkey

Purpose: To compare fracture resistance of roots instrumented with 0.02 and 0.04 taper rotary files, medicated with calcium hydroxide (CH), and obturated with 4 different types of sealers.

Methods & Materials: 200 mandibular incisor roots were instrumented using rotary files with size 30/0.02 tapers, and another 200 roots were instrumented with size 30/0.04 tapers. One hundred roots from both 0.02 and 0.04 taper-instrumented roots were dressed with CH for 7 days. Twenty-one groups each containing 20 roots were as follows: Groups 1–4, EndoSequence BC Sealer (Group 1 was instrumented with 0.02 files plus CH, Group 2 with 0.02 taper files, Group 3 with 0.04 taper files plus CH, Group 4 with 0.04 taper files). The same sequential groups were executed for roots obturated with ActiV GP (Groups 5–8), MetaSEAL (9–12), and AH 26 (Groups 13–16) sealers. In groups 17–20, roots were not obturated and instead served as positive controls. Another 20 intact roots were assigned as a negative control group (Group 21). Apical 9 mm part of each root was embedded in resin blocks, exposing coronal 4mm part. Each root was then subjected to a slowly increasing vertical load (1mm/min) until fracture occurred. Load at failure was measured and expressed in newtons. Data were statistically analyzed by using one-way analysis of variance (ANOVA) test, t-test and Tukey's test.

Results: ANOVA indicated that instrumentation with both 0.02 and 0.04 taper files caused significant reduction in fracture resistance of roots. ANOVA also showed that canal fillings provided significant elevation in resistance of instrumented roots. Negative control group showed significantly higher fracture resistance than all of positive control groups ($p < 0.05$) showed. Difference between 0.02 and 0.04 taper positive control groups was statistically insignificant ($p > 0.05$). One week of CH application did not affect strength of roots ($p > 0.05$). There was no significant strength difference between negative control group and any of groups that used sealers ($p > 0.05$). Three ActiV GP groups, one MetaSEAL group, and one EndoSequence BC Sealer group showed statistically higher resistance than positive controls showed ($p < 0.05$). None of AH Plus groups exhibited significant differences from the positive controls ($p > 0.05$).

Conclusion: Canal obturation with one of the sealers could increase resistance, although with varying degrees when compared with instrumented but not obturated roots. ActiV GP provided the highest resistance to roots. MetaSEAL ranked second, EndoSequence BC Sealer ranked third, and AH Plus ranked fourth.

INTRODUCING FATIGUE TRACKING SYSTEM FOR MONITORING STERILIZED ENDODONTIC ROTARY FILES

Temsah, Abdul-Karim*, Saleh, Amr ; Abozor, Basel ; Temsah, Ahmad
Dr Soliman Fakeeh Hospital
Dental Department
Jeddah, Saudi Arabia

Keywords: Nickel-Titanium, cyclic fatigue, sterilization cycles

Purpose: To evaluate fatigue tracking system (FTS) used to control the usage of re-sterilized nickel-titanium (NiTi) endodontic rotary files in the clinical endodontic practice.

Methods & Materials: Files consumption tables (FCTs) were used to track 99 Revo-S files arranged in 33 sets. Each set has 3 files SC1, SC2 and SU. These sets were used by 2 endodontic clinics. After each case, marks were written on FCT. One mark was given for each simple canal preparation, two marks were given for curved or calcified canals and "S" mark was given for non used files in the set. If any file showed overforcing signs, fractured or reached more than 7 marks of FCT, the whole set was collected. After that all un-fractured files underwent fatigue test. Pearson's product-moment coefficient r was obtained to determine the statistical correlation between number of cycles to failure (NCF) and file consumption.

Results: There was moderate correlation between NCF and file consumption of total tested SU files ($r = -0.453$, $P = 0.009$). But no relationship was found for SC1 and SC2 files.

Conclusion: Implementation of FCT facilitates safe usage of rotary files and saves materials by ensuring proper discarding time of the file allowing the dentist to order certain files refill.

EVALUATION OF VOLUME AND SURFACE AREA AT HORIZONTAL FRACTURE SITE

Toptanci, Ismet Rezani*, Aksoy, Orhan**. Yavuz, Izzet*
Dicle University Dentistry Faculty
*Department of Pediatric Dentistry **Department of Orthodontics
Diyarbakir, Turkey

Keywords: Horizontal Root Fracture, CBCT, 3-D Modelling

Purpose: To investigate the volume and surface area at horizontal root fracture site before and after treatment with using 3-D imaging of Mimics program.

Methods & Materials: This study approved by Dicle University Faculty of Medicine Ethics Committee (no:18.08.2011-235). 10 traumatized patients, 7 boys and 3 girls (mean age was 14) who diagnosed horizontally root fracture at maxillary central incisor teeth included this study. Before and after treatment Cone Beam Computerized Tomography (CBCT) imaging performed for all patients. CBCT images were acquired with an iCAT 3-D imaging device (Imaging Sciences International, Hatfield, Pa). After evaluating HRF at CBCT, their endodontic treatment were planned and finished according to IADT guidelines. Measurements were performed with using Mimics V10.01 (Materialise, Leuven, Belgium). DICOM files obtained from CBCT scans were reconstructed by Mimics software. By using the manual-segmentation function of software, the fracture lines were separated from whole images. 3-D images were used for measurement. Wilcoxon signed ranks test used for statistical analysis.

Results: Differences between volume and surface area values before and after treatment was statistically significant (Volume; $p=0,009$ and $p<0,05$, Surface Area; $p=0,005$ and $p<0,05$). There were no statistically differences between girls and boys in terms of volume and surface area ($p> 0,05$).

Conclusion: The prognosis of teeth with HRF shows varies. It can be concluded that using 3-D imaging for mimics program to compare volume and surface area of fractured site before and after treatment is possible.

DENTINAL MICROCRACK FORMATIONS DURING DIFFERENT ROOT CANAL PREPARATION TECHNIQUES

Üstun, Yakup*, Aslan, Tugrul; Sagsen, Burak; Kesim, Bertan
Erciyes University, Faculty of Dentistry
Endodontics
Kayseri, Turkey

Purpose: To investigate the incidence of dentinal microcracks, which might occur during the preparation of the root canals by means of different preparation techniques with different systems.

Methods & Materials: 110 extracted human mandibular incisor teeth with single canal and straight root were used for this study. All teeth' root lengths were adjusted to 16 mm (from apex to coronal). All samples were randomly divided into 5 experimental groups according to preparation techniques and instruments (n:20): Group 1: Hand preparation with balanced force technique up to #25 K-file Group 2: Preparation with only ProTaper F2 instrument in a reciprocating movement with an endodontic motor (VDW Silver, Munich, Germany) Group 3: Preparation with Reciproc R25 instrument in a reciprocating movement with an endodontic motor Group 4: Root canals were prepared with ProTaper instruments up to F2 instrument in a conventional rotary movement with an endodontic micromotor Group 5: Root canals were prepared with ProTaper Next instruments up to X2 instrument in a conventional rotary movement with an endodontic micromotor Control Group: Ten roots were selected for this group. No procedure was applied to these 10 roots and used as a control group. Totally 10 ml of 2.5% NaOCl was used for irrigation for each group. After preparation, only the crowns of the teeth were embedded in resin (Technovit; Heraeus-Kulzer, Wehrheim, Germany) and all roots were sectioned horizontally at 3, 6 and 9 mm from the apex with a low-speed saw under water cooling (Minitom, Struer, Denmark). Then the slices were examined through a stereomicroscope and photographs were taken and scoring was done with the images. (Type 1: No crack formation; Type 2: Other defects: craze line or partial crack; Type 3: Fracture). Chi square test was done for statistical evaluation.

Results: There were no significant differences among the groups in means of microcrack formations ($p > 0.05$). In group 4, one sample showed "type 2" microcrack formations through the all root thirds. In group 2, in two samples, there were microcrack formations in both coronal and middle thirds but there were no microcrack formations in apical thirds.

Conclusion: Within the limitations of the present study, except the hand file group, all experimental groups showed microcrack formations. Although ProTaper Next files showed more microcrack formations, this did not cause any statistically significant difference.

CALCIUM HYDROXIDE REMOVAL EFFECTIVENESS OF VARIOUS DEVICES FROM ROOT CANAL

Uzunoglu, Emel*, Gorduysus, M
Hacettepe University Faculty of Dentistry
Department of Endodontics
Ankara, Turkey

Purpose: To compare the efficacy of various devices for the removal of calcium hydroxide (CH) from root canals and their erosive effects on root canal walls with scanning electron microscope (SEM).

Methods & Materials: The root canals of 85 freshly extracted human maxillary central incisors were prepared with ProTaper rotary instruments and randomly assigned into five experimental groups ($n = 15$), whilst the remaining teeth ($n = 10$) served as positive and negative controls. In each experimental group, CH was placed into the canals via lentulos. The negative control did not receive CH placement, and the positive control received the CH, but no subsequent removal. After 7 days, the CH was removed using five different techniques: Group (G) I, Master apical file (MAF) + manual needle irrigation (MNI); GII, Canal Brush (CB) +MNI; GIII, RinsEndo (RE); GIV, Self adjusting file (SAF) + Vatea; GV, CB+MNI, followed by SAF+Vatea. Irrigants, total irrigant volumes and total irrigation time were kept constant throughout the study for all the experimental groups. The roots were grooved longitudinally and split into halves. Randomly selected three specimens from each group evaluated with SEM for dentin tubule erosion. Images of each half of the canal were acquired by a digital camera. A scoring system of 1 to 4 was used to assess the amount of residue on the cervical, middle and apical third of the canal. Data were subjected to statistical analysis using Kruskal–Wallis and Mann–Whitney tests, with Bonferroni correction, at 95% confidence level ($P < 0.05$).

Results: Remnants of CH were found in all experimental teeth regardless of the device used. When examining the root canal as a whole, there was no significant difference between the groups. When examining the efficacy of CH removal from the apical, middle and cervical third of the canal separately between groups there was a statistically significant difference between the middle ($p=0,003$) and cervical ($p=0,006$) thirds.

Conclusion: None of the devices removed the CH dressing completely from root canal walls. CB and RE cause dentin tubule erosion

EVALUATION OF CANDIDA ALBICANS ADHESION ON VARIOUS DENTAL SPLINT MATERIALS

Yilmaz, Yucel*, Belduz Kara, N, Tosun, I
Ataturk University, Faculty of Dentistry
Pediatric Dentistry
Erzurum, Turkey

Keywords: dental splint material, candida albicans, candida adhesion

Purpose: To compared the susceptibility of four dental splint materials such as titanium, wire, impregnated fiber (Ribbond) using dentin bonding agent (Futurabond M, Voco), and pre-impregnated fiber (GrandTEC, Voco) to Candida albicans adhesion.

Methods & Materials: Titanium, wire, fiber impregnated using dentin bonding agent, and pre-impregnated fiber were used for this study. Ten specimens of each test material were prepared. The specimens maintained contact with Candida albicans suspension, and whether inhibition around the samples was evaluated. For evaluation of the biofilm formation, the XTT technique was used. The obtained data was analyzed and the level of statistical significance was set at 5%.

Results: There was statistically significant difference among groups according to the XTT values. Pre-impregnated fiber specimens revealed the lowest quantity of biofilm formation ($P < 0.05$). The highest mean XTT value, significantly higher than the other materials ($P < 0.05$), was found for titanium test material. No statistical difference in the mean XTT values was found between the wire and the impregnated fiber using dentin bonding agent.

Conclusion: The type of dental splint material may be seemed to be a decisive factor in Candida levels. In addition, Candida colonization was established in all types of dental splint material.

Case Posters- Epidemiology Social Aspects Education Diagnostics**CBCT FINDINGS OF SPONTANEOUSLY HEALED HORIZONTAL ROOT FRACTURE****Karapinar Umar, Esma*, Altun, Oguzhan****Inönü Üniversitesi****Department of Mouth, Tooth and Jaw Radiology, Faculty of Dentistry****Malatya, Turkey****Keywords:** CBCT, root fracture, dental trauma

Purpose: Traumatic dental injuries may damage teeth and their supporting structures, which occurs most commonly in young patients and affecting function and aesthetics. Intra-alveolar root fractures in permanent teeth are uncommon among dental traumas. This case report aims to detect horizontal root fractures in a maxillary central incisors using a combination of conventional radiographs and cone-beam computed tomography (CBCT).

Methods & Materials: A 36-year-old man was referred to our clinic with complaints of gingival recession in the maxillary right and left central incisors. The fractured roots were discovered during a routine radiographic examination. The teeth were asymptomatic. Vitality testing with an electric pulp tester elicited no response from the maxillary right central incisor. Maxillary left central incisor was vital. Also there was not any periapical pathology in the periapical radiograph. The patient reported a trauma, which occurred 12 years before. To obtain more detailed information on root fractures it was decided to examine the teeth with cone-beam computed tomography with three-dimensional reconstructions.

Results: CBCT images showed the displaced fragments of the root fracture and spontaneously healed root fracture of the in detail. There was no evidence of cervical or internal resorption in the teeth.

Conclusion: It was concluded that CBCT might be a useful complementary diagnostic method conventional radiography in cases of suspected horizontal root fractures.

APICAL ROOT RESORPTION DUE TO TRAUMA AFTER 20 YEARS**Keskin, Cangul*, Sariyilmaz, Evren , Ozdemir, Ozgur****Ondokuz Mayıs University****Endodontics****Samsun, Turkey**

Purpose: To present a case of external apical root resorption of upper central incisors 20 years after trauma.

Methods & Materials: 43-year-old female patient was referred to Department of Endodontics for evaluation of maxillary central incisors. Patient reported she had a traffic accident 20 years ago. After injury patient had no dental complaint so she did not have an examination of her upper incisors. Teeth were asymptomatic since then. There was no history of bleaching, orthodontic treatment and other trauma. There was no relevant medical or family history of systemic diseases. When patient applied university hospital because of periodontal problems a routine orthopantomogram revealed external apical resorption of teeth #11 and #21. Radiographs prior to the original referral were unfortunately unavailable for comparison. Clinical examination of #11 showed no discoloration, no tenderness to percussion and palpation. The tooth responded thermal and electric pulp tests normally. #21 showed no tenderness to percussion and palpation. The tooth had yellowish discoloration and responded thermal and electric pulp tests normally. Periodontal examination displayed probing depths less than 3mm with moderate bleeding. The teeth showed Miller grade II mobility. Radiographic examination revealed advanced external apical resorption and very short maxillary central incisor roots. Remaining teeth were normal in root length. Pulp chamber and root canal was visible on periapical radiographs in #11 however total obliteration was observed in the pulp chamber and root canal of #12.

Results: Patient was decided to be monitored clinically and radiographically in every 6 months. Intervention such as osseointegrated implants is indicated if signs and symptoms require to maintain function and aesthetics.

Conclusion: In the absence of signs and symptoms of pulpal and/or periapical disease, long-term monitoring is essential in apical resorption cases rather than endodontic treatment.

REIMPLANTATION: SUCCESSFUL PROGNOSIS IN ABSENCE OF FOLLOW UP GUIDELINES

Minetto, Rossana*, Guerrero Alexandra, Carrasco Mariana
Armada De Chile/ Universidad De Valparaiso, Facultad De Odontologia
Odontológico/Cátedra De Odontopediatria
Viña Del Mar, Chile

Purpose: An acceptable biological response depends mainly on the environmental risk and on an appropriate and timely treatment. However, this case report shows that despite the unfavorable conditions of any of these factors, a successful outcome can be obtained.

Methods & Materials: A 7 year- old boy sought treatment at the Emergency Room of the Navy Hospital in Viña del Mar, Chile, after suffering avulsion of tooth 21, result of a fall while playing rugby. The tooth was transported in a jar with milk, and was replanted within 35 minutes of the accident. Subsequently, the patient was sent to the Dental Clinic of the same institution in Viña del Mar, to undergo appropriate follow up. Close clinical and radiographic follow-up controls were not possible to carry out, due to lack of patient cooperation, which was manifested by poor oral hygiene and multiple dental trauma episodes on the same tooth (two new knocks against objects). However, the biological response was positive, as the reattachment of the periodontal fibers were achieved and pulp vitality was maintained.

Results: At 9 years of follow up, yellow discoloration was clinically observed in tooth 21, with negative response to thermal test (cold). The radiograph exam showed full root development ,almost complete pulp canal obliteration (PCO),healthy periodontal ligament and bone tissue.

Conclusion: Despite the lack of patient adherence to follow up controls, this case demonstrates that successful treatment lies mainly in the appropriate emergency management of the avulsed tooth at the site of accident, proper storage media used before replantation, and also the degree of root development. Key Words: avulsion, pulp canal obliteration , replantation

USE OF CBCT IN DIAGNOSIS OF INTRUSIVE LUXATION

Sinanoglu, Enver Alper*, Helvacioğlu-Yigit Dilek , Kocak-Büyükdere Ayşe
Faculty of Dentistry, University of Kocaeli

Department of Oral and Maxillofacial Radiology, Department of Endodontics, Department of Prosthodontics
Kocaeli, Turkey

Purpose: Intrusion is accepted as the most serious luxation injury which results in the tooth being displaced apically, leading to a crushing of the neurovascular bundle entering the pulp and severe damage to cementum and periodontium.

Radiographic examination is essential for recognition malposition and type of luxation. Modified projections play an important role for accurate examination depending on the kind of malposition. In case of advanced imaging, cone beam computed tomography (CBCT) appears to be an effective and safe way to overcome some of the problems associated with conventional radiography with less radiation for the patient in comparison with traditional CT scans. This case report presents CBCT findings of an intruded maxillary right central tooth which is not revealed by conventional dental radiographs during examination.

Methods & Materials: 22-year-old male patient was referred to Faculty of Dentistry, University of Kocaeli for the restoration of incisal fracture of maxillary right central tooth three days after having acute dental trauma. The patient also described pain in that region. The intraoral examination revealed no laceration of soft tissue and any bleeding. There was uncomplicated crown fracture in the right maxillary central incisor with no mobility but tenderness to percussion. The periapical radiograph did not reveal any root fracture. CBCT scan was performed for further examination and a diagnosis of intrusive luxation was made. 3-Dimensional (3D) reconstruction revealed an intrusion due to the position of cemento-enamel junction which was not detected during clinical and radiological examination. An oblique fracture line was also detected on the buccal cortex of the alveolar bone.

Results: A 2-visit root canal treatment was carried out and the tooth was restored using composite resin. At 6-month follow-up the tooth was asymptomatic.

Conclusion: CBCT gives high quality diagnostic images of the maxillofacial region and can be studied via using multiplanar reformation and 3-D rendering. In some cases, evaluation of the fractured tooth anatomy by conventional radiographs might be misinterpreted by the clinician. As a complementary radiographic examination, CBCT appears to be an important diagnostic tool in the field of dental traumatology.

Research Posters- Epidemiology Social Aspects Education Diagnostics
HOW DOES DENTAL TRAUMA AFFECT THE QUALITY LIFE OF FAMILIES?

Alaçam, Alev*, Bani,Mehmet; Çinar, Çagdas
Gazi University, Faculty of Dentistry
Department of Pediatric Dentistry
Ankara, Turkey

Purpose: Traumatic dental injury (TDI) could have physical and psychosocial consequences for children. However, there is scarce evidence concerning this impact on their family life. The aim of the present study was to investigate the association between TDI in Turkish children and impact on the quality of family life(QoL) by using Turkish Family Impact Scale (T-FIS).

Methods & Materials: Entire patients who applied to Gazi University Faculty of Dentistry Department of Paediatric Dentistry due to TDI in 2013 were included in the study. Types of TDI were classified according to Glendor et al. Parents of 110 children aged 7-15 years answered the T-FIS on their perception of QoL. T-FIS consists of 14 items divided into four subscales: parental/family activity (PA), parental emotions (PE), family conflict (FC), and financial burden subscale (FB). The questions refer only to the frequency of events in the previous 3 months. QoL was measured through T-FIS items and total score, and Poisson regression was used to associate the variables with the outcome. For this initial analysis, the Kolmogorov–Smirnov was used to assess the normality of the distribution of values. After this procedure, nonparametric (Kruskal–Wallis) test was used.

Results: The mean age of the family representatives was 44 years old (14.8 SD); 52.7% of the respondents were mothers and 47.3% were fathers. The mean age of the children was 9.2 (4.1 SD) years old, and the majority (57.3%) were boys. The maxillary central incisor was the most affected tooth (83.6%). Severity of TDI showed a negative impact on the total score and subscales on PA, PE and FB. This study determined PE > PA > FB > FC values. PE values had higher statistical significant than PA, FB and FC values (P < 0.001).

Conclusion: High PE values affected QoL in family. The T-FIS scores indicated that TDI has significant impact on the Turkish family's QoL.

KNOWLEDGE OF FIREFIGHTERS REGARDING THE EMERGENCY MANAGEMENT OF DENTO-ALVEOLAR TRAUMA

Almeida, Júlio*, Bissacot, Giovanna; Garcia, Fernanda; De Souza, Tiago
University of Brasília
Department of Dentistry and University Hospital of Brasília,
Brasilia, Distrito Federal, Brazil

Purpose: To assess the Knowledge and attitudes of firefighters with paramedic training regarding the emergency management of dento-alveolar traumatic injuries, specially those involving tooth avulsion.

Methods & Materials: A observational cross-sectional study was carried out from a web survey (<http://www.surveymonkey.com>) applied to 54 volunteer military firefighters with special paramedic training in Brasília/DF (Brazil). A semi-structured questionnaire was used to assess specific knowledge and attitudes regarding hypothetical situations of emergency with short history descriptions of dento-alveolar trauma injuries. Inclusion criteria required active service as military firefighters corpsmen for at least 1 year in first-aid care unit before the study. Frequency distribution was used to data analysis.

Results: The results revealed that 50% of the respondents already had seen any type of dento-alveolar trauma during they service; 25,5% of the military firefighters did not know what tooth avulsion means. Among those who knew the meaning of tooth replantation, 86% answered that they would not be able to perform this procedure in tooth avulsion cases; In concern to the best storage medium for an avulsed teeth, 60% of the participants chose a wet medium, 22% chose a sheet of paper, 10% chose ice, 6% chose the patient's hand and 1% chose the patient's mouth. Among those who chose a wet medium to storage an avulsed tooth, 68,8% chose saline or milk as the best storage medium for transportation of an avulsed teeth while 18,7% chose any type of antiseptic solution and 12% chose tap water or alcohol; 58,5% of the firefighters interviewees answered that they did not feel confident regarding the emergency management of dento-alveolar trauma; 84,9% of the firefighters surveyed had not received any specific education on how to proceed in cases of dento-alveolar trauma during their paramedic training course and 100% of them considered this knowledge a requirement for first-aid care to accident victims.

Conclusion: The Knowledge of this group of military firefighters regarding the emergency management of dento-alveolar traumatic injuries was unsatisfactory in several aspects that are important for the success of the treatment procedures. Further continuing education with regards to the firefighters's emergency services is needed. Special emphasis should be given to provide military firefighters with the relevant education to improve their knowledge and ability of dealing dento-alveolar trauma in order to improve treatment prognosis and increase the survival rate of replanted tooth.

DO BEHAVIOR RISK FACTORS IN DENTAL TRAUMA DIFFER FOR GENDER?

Bani, Mehmet*, Bodur, Haluk ; Kapci, Emine Gül

Gazi University Faculty of Dentistry Department of Pediatric Dentistry

Ankara University Faculty of Educational Sciences Department of Psychological Services In Education

Ankara, Turkey

Purpose: Examining the risk factors for childhood traumatic dental injuries for male and female patients have been elusive. Present study aimed to examine whether males and females are differentially vulnerable to Traumatic Dental Injuries in relation to emotion regulation, attention deficiency hyperactive disorder symptomatology and behavior problems.

Methods & Materials: An institutional ethical review board approved case-control study carried out in Gazi University, Faculty of Dentistry, Ankara, Turkey. A total of 80 patients with traumatic dental injuries (Male n=50 and Female n=30) and 80 patients with other dental problems (Male n=56 and Female n=24) participated in the study. Age range of the patients were 7-15. Patients' parents filled in two scales. The first is the Conners' Rating Scales-Revised with Attention Deficiency Hyperactive Disorder-Index, Oppositional Behavior, Hyperactivity, Anxious-Shy, Social Problems, Inattentive and Hyperactive-Impulsive subscales. Second is the Emotion Regulation Checklist, with two subscales of Emotional Lability and Emotion Regulation. Multiple logistic regression analyses were performed separately for male and female patients.

Results: Oppositional behavior, hyperactivity and social problems were found to be risk factors for male patients. Being anxious-shy was the protective factor for both males and females. Classification accuracy for males and females were calculated to be 79.2% and 85.2% respectively.

Conclusion: Several risk factors for childhood traumatic dental injuries were found to differ for male and female patients. Prospective studies from representative populations are needed to confirm the present study findings and examine risk factors for male and female patients separately.

DIAGNOSIS OF IATROGENIC LESIONS BY CONE BEAM CT

Corte-Real Gonçalves, Ana Teresa*, Mesquita, Margarida; Ferreira, Artur; Figueiredo, José;
Caetano, Catarina
University of Coimbra
Faculty of Medicine
Coimbra, Coimbra, Portugal

Keywords: Cone Beam-CT, iatrogenic, tool

Purpose: This paper intends to conduct a research on the scientific community regarding the control and removal of osteosynthesis material. It also aims to evaluate whether CBCT reveals itself as an important a tool for therapeutic decision and follow-up.

Methods & Materials: Structured electronic search of scientific papers was carried out on Pubmed. Using combinations of the following keywords: osteosynthesis material, follow-up, plate removal. The experience of the Unit of Orofacial Trauma of the Faculty of Medicine of the University of Coimbra and University Hospital of Coimbra (Portugal) was reported. This unit's Cone Beam CT database was used to complement the research.

Results: The removal of osteosynthesis material in patients who suffered orofacial trauma or underwent orthognathic surgery is not a routine procedure. In consolidated fractures, aiming the individual's full restitution removal of osteosynthesis material may be performed. In the event of iatrogenic lesions such as infection, exposure of the material in the oral cavity or when there is a conflict with the surrounding anatomical structures, removal is indicated. A iatrogenic lesion such as the violation of the dental intraligamentary space can occur when osteosynthesis material is placed. In a case of the Unit of Orofacial Trauma, a young man was diagnosed with a mandibular symphysis fracture, surgically reduced with placement of osteosynthesis material. After 2 months the injured described pain in the lower left canine and presented functional limitation in all the movements that involved that tooth. Through the CBCT images it was possible to evaluate the proximity of osteosynthesis plates with the dental roots as well as measuring the clamping screws.

Conclusion: In this paper, the diagnosis of iatrogenic lesions can be supported by Cone Beam CT. This tool can improve the success of orofacial clinical procedures. Although CBCT is not widely used in clinical practice, it revealed itself as powerful complementary exam in situations orofacial trauma.

KNOWLEDGE ABOUT TOOTH AVULSION AND ITS MANAGEMENT AMONG DENTAL ASSISTANTS

Halawany, Hassan*, Aljazairy, Yousra; Alhussainan, Nawaf; Almaflehi, Nassr; Jacob, Vimal; Abraham, Nimmi
College of Dentistry, King Saud University
Dental Caries Research Chair
Riyadh, Saudi Arabia

Purpose: Studies evaluating dental assistants' knowledge about tooth avulsion and its management are rare. The purpose of this study was to evaluate the level of knowledge about tooth avulsion and its management among dental assistants in Riyadh, Saudi Arabia.

Methods & Materials: Of the 691 pretested 17-item questionnaires that we distributed, 498 were returned, for an overall response rate of 72.1%. Seven questions were related to knowledge about tooth avulsion. Correct answers to these questions were assigned one point each, and based on this scoring system, an overall knowledge score was calculated. An analysis of covariance was used to test the association between the level of knowledge (total score) and the educational qualifications of the respondents (dental degree and others). A P-value of 0.05 was considered the threshold for statistical significance.

Results: The majority of the respondents (n=387; 77.7%) were non-Saudis (377 were from the Philippines), and 79.1% (n=306) of the Filipinos had a dental degree. The question about recommendations for an avulsed tooth that is dirty elicited the highest number of correct responses (n=444; 89.2%), whereas the question about the best storage media elicited the lowest number of correct responses (n=192; 38.6%). The overall mean score for knowledge about tooth avulsion was 6.27±1.74. The mean knowledge score among the respondents with a dental degree was 6.63±1.37, whereas that among the respondents with other qualifications was 5.71±2.08.

Conclusion: The educational qualifications of the surveyed dental assistants were strongly correlated with the level of knowledge about tooth avulsion and its management.

MOST-CITED ARTICLES IN DENTAL / JAW TRAUMA

Jafarzadeh, Hamid*, Sarraf, Alireza, Andersson, Lars, Talati, Ali
Faculty of Dentistry, Mashhad University of Medical Sciences, Mashhad, Iran
Endodontics
Mashhad, Iran

Purpose: The purpose of this study was to identify the most-cited articles in dental/jaw trauma published over the last 63 years.

Methods & Materials: A list of the most-cited articles was compiled using All Databases of the ISI Web of Knowledge. The characteristics including number of citations, authors, journals, publication year, institution/country, article type, etc were analyzed.

Results: The first 100 articles with 100 or more citations published between 1950 and 2013 were listed. Regarding the type of articles, most of them were original research. The results regarding other parameters would be presented separately.

Conclusion: The most-cited articles in dental/jaw trauma allow for advances in this field and provide useful information for direct future studies and patient care.

DENTAL TRAUMA MANAGEMENT OF DENTISTRY STUDENTS: A SURVEY STUDY

Özisik, Isil*, Küçükaya, Selen ; Zakin, Abdulkadir ; Görduysus, Melahat
Hacettepe University
Endodontics
Ankara, Turkey

Purpose: The purpose of this study was to assess the knowledge and ability of the first, second and third grade dentistry students in Hacettepe University on managing traumatic dental injuries.

Methods & Materials: A questionnaire comprised of 15 multipart questions regarding background, personal experience, and knowledge of dental trauma was prepared. The questionnaires were delivered to 350 students and retrieved in 15 minutes. Thereafter, all responses were gathered in the software SPSS and analyzed statistically using the chi-square test.

Results: A total of 315 dentistry students chose to participate in this survey study. 72.1% of the respondents stated that they did not take first aid education and 78.4% of the respondents did not come across any informative data through media. 28.6% of the respondents had experienced dental trauma incident previously. 41.3% of the respondents answered correctly the suitable time for treatment. Most of the correct answer was given by third grade students and it was statistically significant ($p < 0,001$). 38.4% of the respondents knew how to correctly manage to tooth fracture and the correct answer was mostly chosen by third grade students ($p < 0,001$). 61.3% of the respondents chose the correct reason to go to dentist in tooth color change after trauma and 85% of the third grade students indicated the correct answer ($p < 0,001$). Almost 50% of the respondents knew how to manage to displaced teeth and 96.1% of third grade students chose the correct answer ($p < 0,001$). 41.6% of the respondents chose the answer 'I do not replant the avulsed deciduous teeth' whereas 50.2% of the respondents answered as 'I replant the avulsed permanent teeth'. 43.7% of the respondents could not choose at least one of the appropriate media for storing avulsed tooth. 84.8% of the respondents stated that their knowledge on dental trauma was not adequate.

Conclusion: The results of this study show that the majority of the students are not capable in managing dental trauma. On the other hand, almost half of them answered correctly the emergency questions related to dental trauma.

PREVALENCE OF TRAUMATIC DENTAL INJURIES IN 6-12 YEARS OLD CHILDREN

Seymen, Figen*, Koruyucu Mine, Parmaksiz Esra
Istanbul University, Faculty of Dentistry,
Department of Pedodontics
Istanbul, Turkey

Keywords: Prevalence, Traumatic Dental Injuries

Purpose: Traumatic dental injuries (TDIs) are a common problem in child population of the world. The aim of this study was to assess the prevalence and related factors of TDI in 6-12 year-old school children.

Methods & Materials: A total of 897 children (472 female, 425 male), mean aged 8.9 ± 0.84 were examined from 5 different school. Data's were collected through clinical examinations and interviews carried out by a trained, calibrated dentists. Children were seated and examined using plane mouth mirrors and explorers under a portable light. The records of all patients were analysed according to gender, age, type of dental trauma, type of tooth involved, treatment provided, cause of trauma, and dental data's were evaluated as agenesis, supernumerary teeth, malocclusion, edge to edge occlusion, overjet, openbite, deepbite, crossbite, and parent's job status and number of siblings were recorded for the evaluation of socioeconomic and sociocultural status of family. TDI was classified according to the World Health Organization slightly modified by Andreasen & Andreasen. The data analysis included descriptive statistics (frequency distribution), Chi-square, Fisher's Exact and Continuity (yates) correction tests. The level of significance was set at $p < 0.05$.

Results: The prevalence of traumatic dental injuries was observed 3.5%, of which enamel fracture (38.7%) and cracks (35.5%) of teeth was the most prevalent TDI. Most of the traumas affected the maxillary incisors, especially the maxillary central incisors (64.5%). Only 48.4% of traumatised teeth were restored. Avulsion was observed in 6.4% of traumatic teeth. Normal occlusion was observed in 48.3%, 45.1% class II, 6.4% class III occlusion of children with trauma. Class II incidence in children with trauma were found statistically significantly higher than other malocclusions ($p < 0.01$). However, 6.4% had edge to edge occlusion., 3.2% had overjet in the anterior incisor region, 3.2% had crossbite, 12.9% had open bite and 6.4% had deepbite. The study showed that girls (54.8%) were more inclined to dental traumas than boys (45.1%) (mean aged 7.93 ± 0.85). Falls were more frequent trauma type (54.8%). We also found that mothers have a job in 19.3% and fathers have a job in 93.5% of children. Mean number of siblings were observed 1.7.

Conclusion: In this study, the prevalence of TDI to permanent incisors in 6-12-year-old school children was relatively low. The great variation in reported prevalence has been related to the number of different factors such as the type of study, trauma classification, differences in methodology, limited age groups, geographical and behavioral differences between study locations and countries.

ORAL HEALTH-RELATED QUALITY OF LIFE IN PRESCHOOLERS WITH DENTAL TRAUMA

Tabakcilar, Derya*, Peker, Kadriye; Yilmaz, Dilek Ozge; Tuna-Ince, Elif Bahar; Kasimoglu, Yelda; Seymen, Figen; Gencay, Koray
Istanbul University, Faculty of Dentistry
Department of Pedodontics
Istanbul, Turkey

Keywords: quality of life, traumatic dental injuries, early childhood children

Purpose: Traumatic dental injuries (TDI) are recognized as a serious dental public health problem among children. The aim of the present study was to assess impact of traumatic dental injuries (TDI) on the quality of life (QoL) of Turkish children with 0-6 years old after dental trauma and after treatment according to parents/caregiver's perceptions.

Methods & Materials: The study population consisted of 75 parents/caregivers of 0-6 years old Turkish children who were attending to Istanbul University, Faculty of Dentistry, Clinics of Pedodontics from September to December 2013. Data were collected through clinical examinations and self-completed questionnaires including the Early Childhood Oral Health Impact Scale (ECOHIS), children's dental trauma history, and socio-demographic characteristics of mothers and child. Two calibrated examiners used the Andreasen classification for the diagnosis of TDI. Clinical data included the type of trauma and treatment needs. Data were analyzed using descriptive statistics, Mann Whitney U test, and Spearman correlation coefficient.

Results: The mean age of children (48 boys, 36 girls) was 3.82 ± 1.33 years. Their parents/caregivers were 33.52 ± 6.93 years old. Children with complicated TDI had higher scores in the total ECOHIS ($p=0.017$) and its domains ($p<0.05$) except for child self-image/social interaction and symptoms domains ($p>0.05$). Children with treatment needs had higher scores in the total ECOHIS ($p=0.041$) and its child impacts domain. ($p=0.024$). Children attending a preschool had higher scores in the domain of child functions ($p=0.048$). Parents with higher education had higher scores in parental distress ($p=0.022$) and child symptoms domains ($p=0.020$). No significant differences were found in terms of other socio-demographic factors and trauma history (gender, income, duration time of trauma) in the total ECOHIS and its domains ($p > 0.05$).

Conclusion: Complicated traumatic dental injuries, the presence of treatment needs, having with lower parental education have a negative impact on the quality of life of 0-6 year-old children and their parents.

A RETROSPECTIVE STUDY OF PEDIATRIC TRAUMATIC DENTAL INJURIES IN XI'AN

Wang, Xiaojing*, Yu Zhang, Yuan Zhu, Wenqiang Su, Zhifei Zhou, Yan Jin
School of Stomatology, the Fourth Military Medical University
Department of Pediatric Dentistry
Xi'an, China

Purpose: Pediatric traumatic dental injury (TDI) is an important public dental health issue around the world because of its high prevalence, severe physical or psychological impacts and high prevention and treatment costs. The aim of this retrospective study was to reveal the age-dependent distributive features of pediatric TDI in a university dental hospital in Xi'an, China. We intend to perform further research regarding the prevention of pediatric dental trauma.

Methods & Materials: 681 Children, aged 1 to 15 years, came to the hospital for the treatment of dental trauma from February 2011 to May 2012. The trauma-related information including age, gender, urban or rural residency, etiology and location of trauma, type of tooth involved and time interval between the injury and treatment as well as the classification of TDI were recorded and analyzed.

Results: Most of the TDIs occurred in children aged 7 to 12 years and affected the maxillary incisors. 17.2% of all the children had overjet. Concussion, enamel-dentin-pulp fracture, avulsion and lateral luxation occurred more in the primary dentition (20.9%, 16.5%, 14.3% and 13.2%, respectively). However, 33.7% and 29.1% had enamel-dentin-pulp fractures and enamel-dentin fractures in the permanent dentition respectively. Most TDIs were luxations ($n=156$) in the 1-6-year-old group, while fractures were more common in the 7-12- and >13-year-old groups ($n=549, 84$; $P<0.001$). Totally, 357 urban children had access to immediate medical care, whereas only 12 rural children were able to access a clinic within 24 hours after injury ($P<0.001$).

Conclusion: Based on the information presented in this study, the government should pay more attention to the medical development in rural settings and should attempt to balance the distribution of medical resources between urban and rural areas. In addition, propaganda and education should be promoted to enhance the guardians' awareness regarding pediatric traumatic dental injuries and preventive appliance, such as mouth guard, should also be equipped with susceptible children.

AN EPIDEMIOLOGICAL STUDY IN OROFACIALLY TRAUMATISED CHILDREN IN GAZIANTEP-TURKEY

Yildiz, Esma*, Gundogar, Zubeyde, Simsek, Mine
University of Gaziantep
Department of Pediatric Dentistry
Gaziantep, Turkey

Keywords: trauma, epidemiology, dentistry

Purpose: The aim of this study was to evaluate the prevalence of orofacial trauma in children who were referred to University of Gaziantep Department of Pediatric Dentistry due to trauma between January 2010 and January 2014.

Methods & Materials: Age and gender of patients, type of dentition, type of anterior occlusion, and type of trauma according to the Andreasen and time of patients' treatment request after trauma were recorded in the form of dental trauma. A total of 400 patients with an age range of 1-13 years were included.

Results: According to data, most of dental trauma cases were observed in permanent dentition and male gender. Males were affected almost two times more than females. Most common etiological factors were "fall from anywhere" (46.3%) followed by "impact with a hard object" (18%). The most common types of dental trauma were crown fracture (22.7%) and complicated crown fracture (18.6%). Considering the patients' treatment request periods after trauma, it was found that most frequently reported time period was "in a week" (25.3%), followed by "in 24 hours" (21%), "in a month" (13.5%), "in 1-2 years" (12%).

Conclusion: Crown fracture and complicated crown fractures as the most common types of trauma emphasize the important of immediate treatments and follow up. Informing the parents is essential because one of the most important factors in the successful treatment is time of patients' dental treatment request after trauma.

ORAL HEALTH-RELATED QUALITY OF LIFE IN EARLY-ADOLESCENTS WITH DENTAL TRAUMA

Yilmaz, Dilek Ozge*, Peker, Kadriye; Tabakcilar, Derya; Tuna-Ince, Elif Bahar; Kasimoglu, Yelda;
Seymen, Figen; Gencay, Koray
Istanbul University, Faculty of Dentistry
Department of Pedodontics
Istanbul, Turkey

Keywords: quality of life, traumatic dental injuries, children

Purpose: Dental injuries are a common occurrence in childhood, constituting a dental public health concern. Children who have sustained a traumatic dental injury (TDI) can experience emotional stress, pain and discomfort relating to their dental injury and such injuries can have a negative impact on children's oral health-related quality of life. The aim of this study was to assess the quality of life (QoL) of Turkish children aged 11 to 14 years who suffer from different types of TDI.

Methods & Materials: A cross-sectional study was carried out involving 74 children aged 11 to 14 years (34 girls, 40 boys) attending to the Istanbul University, Faculty of Dentistry, Clinics of Pedodontics from September to December 2013. The eligibility criteria consisted of the following: (i) children aged 11 to 14 years; (ii) healthy children without disabilities; (iii) having some kind of TDI in the permanent teeth; (iv) TDI that occurred in the last 3 months before questionnaire application. Data were collected through clinical examinations and self-completed questionnaires including the translated Turkish version of the Child Perceptions Questionnaire (CPQ11-14), children's dental trauma history, and socio-demographic characteristics of parents and children. Clinical data included the type of trauma (according to Andreasen's criteria), and treatment needs. Two calibrated examiners used the Andreasen classification for the diagnosis of TDI. Data were analyzed using descriptive statistics, Mann Whitney U test, and Spearman correlation coefficient.

Results: Having complicated traumatic dental injuries and clinical assessed treatment needs were not associated with total CPQ11-14 and its domains scores ($p>0.05$). Children who perceive treatment need had higher scores in the total CPQ11-14 ($p=0.006$) and its emotional ($p=0.001$) and social wellbeing domains ($p=0.014$). Female children had higher scores in the total CPQ11-14 ($p=0.003$) and its oral symptoms ($p=0.012$) and emotional wellbeing ($p=0.003$) domains. No significant differences were found in terms of other socio- demographic factors and trauma history (parents' gender and education level, income, duration time of trauma) in the total CPQ11-14 and its domains ($p>0.05$).

Conclusion: Presence of perceived treatment need and being female have a negative impact on the quality of life of children aged 11 to 14 years. Future studies are needed to explore the agreement between clinical and perceived assessments for treatment need in children aged 11 to 14 who had suffered dental trauma.

Case Posters- Esthetics Prosthetics Restorative**MANAGEMENT OF THE PATIENT WITH MULTIPLE ROOT FRACTURES AND EXTRUSION**

Acar, Ozge*, Akgun, Ozlem Marti; Yildirim, Ceren; Basak, Feridun
Gülhane Medical Academy
Department of Pediatric Dentistry
Ankara, Turkey

Purpose: The purpose of this case report is to present the treatment of 12-year-old male patient with root fractures and extrusion.

Methods & Materials: A 12-year-old male patient admitted to the Pediatric Dentistry Department with a history of dental trauma to the mandibular anterior teeth owing to a car accident. On clinical examination, it was determined that his right and left permanent mandibular incisor teeth extruded and had been splinted in emergency unit. Maxillary incisor teeth had crown fractures. Findings of radiographic examination revealed the mandibular right incisor tooth had complicated crown fracture in middle third, the left one extruded and had horizontal root fracture in the apical third. For the mandibular right incisor tooth, the patient was consulted by a periodontologist and oral and maxillofacial surgeon. After consultation the tooth was extracted, the mandibular left incisor tooth was splinted with semi-rigid splint and endodontic therapy was applied. Maxillary incisor teeth were restored with composite resin. The patient was followed-up for 1, 3 and 6 months postoperatively. Six months later, in order to achieve the aesthetic comfort, ribbon bridge was applied.

Results: At 1 year follow-up examination there was no periapical pathology associated with the mandibular left incisor and the patient was gladly using his ribbon bridge.

Conclusion: In patients with dental trauma, consultation is required with a periodontologist and oral and maxillofacial surgeon in terms of determination of tooth prognosis. If extraction is necessary, aesthetic comfort should be provided in a short time for the patient psychology. Ribbon bridges are easy and quickly applied method used to provide aesthetics.

MANAGEMENT OF COMPLICATED CROWN FRACTURES IN IMMATURE INCISORS

Akgun, Erkan Onur*, Dogan, Cem
Cukurova University
Pediatric Dentistry
Gaziantep, Gaziantep, Turkey

Keywords: immature incisors, fragment reattachment, composite resin

Purpose: Managing crown fractures with exposed pulp is a challenging situation especially in immature teeth. In order to preserve pulp vitality and obtain a closure of apices, pulp capping or partial pulpotomy are the treatment alternatives. The advances in adhesive dentistry make the crown fragment reattachment the first choice for treating crown fractures if the fragment is available. In this case report, treatment of anterior central incisors, one with crown fragment reattachment and one with composite resin filling were reported.

Methods & Materials: Seven years old female patient, suffered from a fall trauma was consulted to our clinic with complicated crown fractures in both anterior central incisors one day after the trauma. Tooth surfaces were cleaned and partial calcium hydroxide pulpotomy in tooth number 21 and direct pulp capping even with calcium hydroxide in tooth number 11 were performed. After pulp therapies each tooth was sealed with glass ionomer cement. Two weeks after the trauma glass ionomer fillings were removed, number 11 was restored with composite resin and number 21 was restored with crown fragment reattachment technique.

Results: Three years after trauma the patient was recalled to the clinic for a follow-up appointment. Both teeth were radiologically healthy and apex closures were obtained. Both teeth were replied positive to electrical pulp testing.

Conclusion: Immediate treatment is one of the most important requirements for successful treatment in dental traumas. However it is not possible for every time to see the patient, right after trauma. Successful treatment obtained in this study can be explained by pulp healing capacity of immature teeth.

TREATMENT OF ANTERIOR TOOTH AFFECTED BY TURNER'S HYPOPLASIA AND TRAUMA

Akkurt, Meltem Derya*, Orhan, Ekim Onur
Kayseri Military Hospital
Dental Clinic
Kayseri, Turkey

Keywords: Turner's Hypoplasia, Dental Trauma, Restorative Treatment

Purpose: The aim of this case report was to present the restorative treatment of anterior teeth using a resin-based restorative material to achieve an esthetic smile and optimal functional result.

Methods & Materials: Enamel hypoplasia is defined as an incomplete or defective formation of the organic enamel matrix of the teeth in the embryonic stage of the tooth. Malnutrition, trauma and environmental and genetic factors can be associated with enamel hypoplasia. Turner's hypoplasia is enamel hypoplasia involving a solitary permanent tooth. The reason for Turner's hypoplasia can be local trauma or infection in the primary anterior teeth. Enamel hypoplasia may cause tooth sensitivity, deterioration of the aesthetic appearance, or susceptibility to dental caries. A 16-year-old male patient with a main complaint of dysfunctional and unesthetic view of the maxillary anterior teeth since childhood. Two years ago, the patient who has undergone bicycle accident was seen for the enamel-dentin fracture in insizal third of the maxillary left central incisor's crown. The fracture line was observed in gingival third of the crown and continued in the palatal area. Enamel defects were observed in the maxillary right central, lateral and left lateral incisors. Provisional treatment was performed by covering exposed dentin surface with glass-ionomer cement for 2 weeks. In the permanent restoration, bonding agent and composite-resin was applied to the teeth.

Results: The patient underwent clinical and radiographic examination every 6 to 8 weeks for the duration of 1 year. Any symptoms in the maxillary anterior teeth were found.

Conclusion: The location of the hypoplasia and trauma-affected area may be considered in treatment planning.

EFFECT OF SOFT LINER MATERIAL ON RETENTION OF COMPLETE DENTURE

Arafa, Khalid*, Arafa, Khalid
Al-Baha University
Department of Prosthodontics
Al Baha. KSA, Saudi Arabia

Keywords: material; patient; retention; force guage; viscoelastic; mastication

Purpose: This study cover three types of materials tested on 90 patients for their effect on retention of complete denture by measuring the force of retention using force guage. Soft linings are compliant, viscoelastic materials used to form all or part of the fit surface of a denture. Their complete function is debatable, but they serve to distribute the forces of mastication.

Methods & Materials: Three resilient liners, visco- gel, Silicone soft reline material, and Molloplast-B Super-Soft were selected. Sample of ninety patients were used and divided into three equal groups, each of thirty patients. Each group was treated by complete denture with the different soft liner materials respectively. Force guage was used to record the retention of the all denture bases. The device first adjusted and the unit of measure was selected to be grams. The desired adapter tension hook was attached to sensing head but it was first painted by pressure indicating paste for every measurement. The sending end with the adapter were placed in line with the denture that being measured. Rotation of the testing head was avoided.the patient was sitting in an upright position with the occlusal plane parallel to the floor and the denture base was inserted and allowed to remain for setting time of 4 minuits for the hook of the denture base was engaged.

Results: The failure of adhesion between a silicone based resilient liner and an acrylic denture base material is a significant clinical problem. Adhesive failure between the liner and the denture base resin creates a potential interface for microleakage leading to an environment for potential bacterial growth and accelerated breakdown of soft liner resulting in deteriorating prosthesis. To achieve better bonding between denture lining materials and denture base resin, several experimental procedures have been conducted such as mechanical surface preparation i.e., roughening of denture base resin, effect of polymerization stage at which resilient liner is packed against the acrylic resin and chemical surface treatment of denture base resin . In the present study, the retention strength values of the dentures according to the different lining materials.

Conclusion: Within the limitations of this in-vitro study, the following conclusions were drawn: 1. Mean bond strength of the visco-elastic material was significantly ($P < .05$) higher than silicon liner and Molloplast, for clinical application. 2. Mixed type of failures were more predominant in the third group of Molloplast-B material, while was less in the second group using silicon liner material, and the least was in the last group using visco-elastic lining material.

INTENTIONAL REPLANTATION WITH 180° ROTATION: A CASE REPORT

Atila, Elif*, Ersin, Nazan
Ege University, Faculty of Dentistry
Department of Pedodontics
Izmir, Turkey

Purpose: To aim of this presentation is to report the treatment approach of a 12-years-old boy with a complicated incisor crown fracture that extended below the gingival margin.

Methods & Materials: A 12 years old boy who suffered of dental trauma of maxillary left central incisor attended to Ege University Pediatric Dentistry. Clinical and radiological examinations revealed oblique fracture line which was extending labially towards the coronal third of the root and therefore intentional replantation was planned. Intentional replantation with tooth rotation consists of extraction , 180° rotation and replantation, thus restoring the biological space. A wire-composite splint was used for stabilization for the new position of the tooth. Antibiotic therapy was prescribed for 10 days and the patient was motivated to maintain oral hygiene. After the surgical procedure the pulp was extirpated and root canal was filled with calcium hydroxide. After two weeks later the splint was removed. Before root canal obturation with gutta-percha, a calcium hydroxide dressing was maintained for 3 weeks. Composite restoration was performed after the completion of the root canal treatment.

Results: The patient was followed up with clinical examination (mobility test, gingival sulcus depth) and radiographic analysis (to analyze root resorption: inflammatory and/or substitution) for 6 months and there were no signs of resorption.

Conclusion: It could be suggested that the intentional replantation with 180°-rotation allowed a more conservative approach with a clinical success of six months without resorption in this case but long term follow-up is required.

REHABILITATION OF CROWN-ROOT FRACTURE WITH SELF-CURE DENTAL ADHESIVE SYSTEM

Baser Can, Elif Derve*, Edebal Tolga Han, Edebal Gülsen
Yeditepe University Faculty of Dentistry
Endodontics
Istanbul, Turkey

Purpose: The permanent maxillary central incisors are the most commonly affected teeth by trauma. Treatment of complex cases of crown-root fractures involve the knowledge of treatment procedures and characteristics of the restorative materials. Relieving pain and restoration of fractured tooth in minimally invasive and less expensive way will be gladly approved by the patient. This case report describes the rehabilitation of complicated crown-root fracture of maxillary left central incisor.

Methods & Materials: 11 year-old male patient was referred to our clinic with acute apical abscess derived from tooth 21. History of the patient revealed that the tooth was fractured accidentally during sport activities one month before he has attended to our clinic. Intraoral examination revealed that the fragment was still in place and the fracture line was continued up to the middle third of the root but not exposing the pulp space. Periodontal defect was evident near effected area and the pulp was necrotic. There were no signs of soft tissue laceration or evidence of alveolar bone fracture.

Results: After root canal treatment, fracture line was restored with a self-cure dental adhesive system containing 4-META/MMA-TBB. Subsequent to endodontic and restorative treatment the tooth was restored with composite veneer.

Conclusion: After 1 year follow up, clinical and radiographic findings demonstrate normal periodontal and periapical conditions. The patient was still under observation by regular recalls

REATTACHMENT OF TOOTH FRAGMENTS: FOUR CASE REPORTS

Delilbasi, Asli Evren*, Ozturk Bozkurt, Funda - Toz, Tugba - Gozetici, Burcu
Istanbul Medipol University, University of Yeni Yüzyil
Department of Restorative Dentistry, Department of Pediatric Dentistry
Istanbul, Turkey

Keywords: dental trauma, crown fracture, reattachment

Purpose: Anterior crown fractures are the most common type of injury in dental trauma. With the importance to the person's physical appearance, crown fractures of anterior teeth, requires immediate treatment solutions. There are many therapeutic procedures for fractured anterior teeth. However, reattachment of the fractured fragment is the best approach if the fragment is available. The purpose of this study was to present follow-ups of reattachment of anterior tooth fragments.

Methods & Materials: Tooth fragments were reattached by using etch&rinse dentin bonding (Single Bond, 3M ESPE) and flowable composite (Filtek Ultimate Flowable, 3M ESPE) in four different cases.

Results: 6 months to 2 years clinical results showed harmonious integration of colour, form and texture after the reattachment of the original piece of tooth.

Conclusion: Restoration of the tooth by reattaching the original fragment is the best way of treatment in aesthetic, conservative and economic point of view.

TREATMENT OF TEETH WITH AMELOGENESIS IMPERFECTA: A CASE REPORT

Duruk, Gulsum*, Duruk, Gulsum
Inonu University
Pediatric Dentistry
Malatya, Turkey

Purpose: The congenital or acquired anomalies like, amelogenesis imperfecta (AI), gingival hyperplasia and open bite may cause esthetical and functional problems. To eliminate these problems, various treatments can be applied to teeth.

But in some situations, clinical crown length doesn't allow to restorative and protetic treatments. Surgical crown lengthening procedure can be made to increase the clinical crown length without violating the biologic width with several techniques such as; gingivectomy, apically displaced flap with or without resective osseous surgery, surgical extrusion using periosteal and excisional new attachment procedure (ENAP).

Methods & Materials: This case report is on the treatment of AI. An 11 year-old male was referred to department of pedodontics with pain, sensitivity and complaints of inability to eat. Intraoral examination showed hypoplasia, discoloration, impacted teeth because of gingival hyperplasia and severe anterior open bite. In this study, it's aimed to eliminate the esthetical and functional complaints of the patient with periodontal and conservative treatments, and to prepare teeth to orthodontic treatment. For this purpose initial periodontal therapy; including motivation, instruction in oral hygiene practices and full-mouth scaling and root planning were given to patient. After this therapy, surgical periodontal treatment were done to lengthen crown length and to eliminate gingival overgrowth. To set up an environment for connective tissue attachment, sulcular/pocket epithelium removed by ENAP. After periodontal treatment, restorative treatment was performed under local anesthesia. The incisal and premolar teeth were restored with composite resin by using strip crowns and, molars were performed with stainless still crowns. Flour varnish was applied to unrestorated teeth. Than the patient was ready to receive an orthodontic treatment.

Results: Any failure of restorations was not seen during the follow-up period of 6 months. The patient's complaints of pain, sensitivity, and inability to eat were resolved. The orthodontic treatment is ongoing.

Conclusion: It was concluded that, in the esthetical and functional problems caused of AI may be restored with composite restorations and stainless steel crowns. In addition, this case supports, ENAP is a simple, effective, and predictable procedure for achieving pocket elimination and gingival overgrowth by means of a clinical new attachment of the gingival tissues in suprabony pockets.

TREATMENT OF COMPLICATED CROWN-ROOT FRACTURES BY INTENTIONAL REPLANTATION: TWO CASES

Eden, Ece*, Eden, Ece- Uzel, Ilhan- Gökçe, Bulent -Kaval, Mehmet Emin- Han, Buket- Simsek- Birant
Ege University
Department of Pedodontics
Bornova, Izmir, Turkey

Keywords: intentional replantation, complicated crown-root fracture

Purpose: Crown-root fractures are always challenging for pediatric dentists due to their sophisticated management and uncertain prognosis. The extension of the fracture line below the gingiva, the age of the patient and the developmental stage of the apex are important factors that may influence the treatment. The purpose of this presentation is to report two cases of crown-root fractures with different development levels of apices that are treated with intentional replantation with long follow-up.

Methods & Materials: The first case was an 8-year-old female patient who suffered a complicated crown-root fracture on permanent maxillary left central incisor (tooth 21) with an open apex who was treated using an intentional 180°-rotation replantation technique in order to move the fracture line over the gingival margin. The open apex was obturated using MTA and gutta-percha cones. The tooth was restored with aesthetic resin composite. The second case was a 9 years old female who applied to the clinic with a complicated crown-root fracture on a permanent maxillary left central incisor (tooth 21) with a closed apex. Intentional replantation with 180°-rotation was performed and root canal treatment was applied. 4.5 years later composite restoration was renewed and gingivectomy was applied for esthetic improvement. At the age of 16, the patient fell down again and applied to the clinic with a complicated crown fracture on 11 and subgingival fracture on 21. Pulpotomy was applied for 11 and the tooth was restored by composite veneer. Glass fiber post was applied to 21 and restored by a composite crown.

Results: Case one was followed-up to three years after treatment. Clinical and radiological evaluation revealed ankylosis. The patient needs orthodontic treatment where the case would be evaluated accordingly and extraction may be the treatment of choice. Case two was followed-up eight years for the outcome of the intentional replantation of 21 and one year for complicated crown fracture in 11. The treated teeth were functionally and esthetically acceptable, suggesting that the treatment was successful.

Conclusion: Intentional replantation may be considered as an alternative and effective treatment option for teeth with crown-root fractures. But general rules do not apply and individual treatment plans are necessary for each case.

ESTHETIC REHABILITATION OF ANTERIOR FRACTURED TOOTH: A CASE REPORT

Gokturk, Aslihan*, Ozel, Emre
Faculty of Dentistry, University of Kocaeli
Department of Restorative Dentistry
Kocaeli, Turkey

Purpose: The purpose of this report is to present clinical success of a fractured maxillary left permanent central incisor utilizing polychromatic layering technique.

Methods & Materials: A 15-years old female patient with a non-esthetic view regarding fractured maxillary left central incisor was referred to our clinic. During medical history it was observed that the patient has an orthodontic treatment and old restoration on fractured tooth. It was decided that replacement of the restoration was necessary due to esthetical and functional success. Following the intraoral examination, deviation on the long axis of tooth into the facial and distal direction was observed. No periapical disease or root fracture was diagnosed during radiographic examination. At the beginning of the treatment procedure, beveling with diamond bur was performed. Dentin was cleaned with tungsten carbide bur. The tooth was etched with 37% phosphoric acid, restored with an adhesive system (Single Bond Universal Adhesive, 3M ESPE, USA) and nanocomposite (Filtek Ultimate Universal Restorative, 3M ESPE, USA). A2 Body and A2 Enamel shades are utilized for polychromatic layering technique. Finishing and polishing procedures were performed by discs and burs. Recall was performed at the end of three months.

Results: Direct resin composite restoration was found successful according to modified United States Public Health Service (USPHS) criteria after three months in terms of retention, color match, marginal discoloration, secondary caries, marginal adaptation, and surface texture.

Conclusion: Direct resin composite restoration can present esthetical and functional success with the polychromatic layering technique in short term period.

RESTORATION OF A TRAUMATIC INTERNAL RESORPTION IN THE ESTHETIC ZONE

Grous, Stefania*, Garcia Mur, Berta
Athens, Greece

Purpose: To illustrate the treatment modality of a patient who presented with a central incisor involving internal root resorption and a pulpal polyp due to childhood trauma.

Methods & Materials: The 25 years old female patient with the hopeless tooth in the anterior maxillary esthetic zone, underwent extraction and immediate implant placement. A provisionalization protocol was followed by using the coronal part of the natural extracted tooth as a resin bonded prosthesis. The patient received a definitive all ceramic cement-retained implant crown after 4 months.

Results: The clinical procedures will be presented step by step with emphasis on emergency and provisionalization protocols. The indication of these treatment modalities will be highlighted.

Conclusion: Immediate implant placement is a viable treatment option for patients who suffer from dental trauma. Besides the paramount significance of the 3-D implant position, the emergency treatment and the provisionalization protocol also plays an important role in the soft tissue management and hence the final esthetic outcome.

MANAGEMENT OF CORONAL FRACTURES: REATTACHMENT OF FRAGMENT WITH FIBER-REINFORCED POST

Guder, Gizem*, Ozel, Emre; Aydemir, Seda
Faculty of Dentistry, University of Kocaeli
Department of Restorative Dentistry
Kocaeli, Turkey

Keywords: reattachment, fiber post, crown fracture

Purpose: The purpose of this report is to present clinical success of reattachment of a fractured maxillary left permanent central incisor using fiber-reinforced post.

Methods & Materials: A 22-year-old female patient who had sustained a complicated crown fracture due to a bicycle accident referred to our department. The patient's medical history was unremarkable. Dental history of the patient revealed that there was a horizontal fracture in the cervical region of the left maxillary central incisor and the endodontic treatment was started a week ago but it was not completed yet. Also adjacent teeth were vital and splinted right after the trauma. Radiographic examination indicated that the root and the maxilla were intact. The patient brought the fractured crown in sterile saline solution. The treatment plan was to reattach the fractured crown with a fiber-reinforced post after the completion of endodontic treatment. One week after completion of the endodontic treatment, the root canal was prepared for the post placement with the special drills of the Angelus Exacto Glass-Fiber Post System. A groove was made in the pulp chamber of the fractured crown with a tapered fissure bur for higher retention. Additional tooth preparation was not required. Prepared and fractured zones were etched (37% phosphoric acid) and Clearfil Tri-S Bond Plus (Kuraray, Osaka, Japan) was applied. Glass fiber post (Angelus Exacto Glass-Fiber Post System, Brazil) that had been previously conditioned with the bonding agent was inserted into the root canal along with dual-cure resin cement (Panavia F2.0, Kuraray Medical Inc., Japan) and cured for 60 seconds. Then the groove in the crown was also filled with the dual-cure resin cement and adjusted on the fiber post and cured for another 60 seconds. The residual excess at the restorative margin was finished with discs and burs. Recall was performed at the end of one year.

Results: This case report presents that reattachment treatment with a fiber-reinforced post performed well aesthetically and functionally at the end of one year.

Conclusion: Utilization of fiber-reinforced posts on crown fractures not only maintains preservation and reinforcement of the tooth structure but also enhances the aesthetic quality of the reattachment treatment.

PROSTHETIC APPROACH TO TREATMENT OF TRAUMATIZED TEETH: A CASE REPORT

Gümüş, Hüsnüye*, Aydınbelge, Mustafa ; Cantekin, Kenan
Erciyes University
Pediatric Dentistry
Kayseri, Turkey

Keywords: dental trauma, external root resorption, prosthetic approach

Purpose: Solitary permanent maxillary anterior tooth loss in a child or young adolescent is usually because of either direct trauma or its sequelae. Following traumatic loss of the anterior tooth, it is important that an immediate replacement is provided in order to avoid esthetic, masticatory and phonetic difficulties, and to maintain the edentulous space. Restorative options available to the practitioner for treatment of anterior tooth loss include both removable and fixed appliances. The fixed appliances include bonded appliances and soldered wire and crowns/bands appliances. Removable appliances are space maintainers, dentures and spoon dentures. In this case report, prosthetic approach of a patient with maxillary right central incisor loss is presented

Methods & Materials: A 13 year-old boy, with a chief complaint of missing of the right central incisor was referred to the our pediatric dentistry clinic. His medical history was non-contributory. He had experienced traumatic injury one year ago and went to the local dentist's office after than. The dentist restored the right central incisor with root-canal treatment and finished with crown restoration and restored the left central incisor with composite-resin. After nine months of treatment, with complaint of mobility and pain of the right central incisor went to the local dentist's office again. Radiographic evaluation was found root fracture of the right central incisor and traumatized tooth was extracted by the dentist.

Results: Missing right central incisor was made by fabrication of a temporary denture for the rehabilitation of function and esthetics in our pediatric dentistry clinic.

Conclusion: A fixed appliance-type provisional prosthesis was fabricated by using the appropriate size and color of a tooth. This method provide a very adequate, esthetic treatment solution before a permanent restorative plan could be developed in the future.

PRACTICAL APPROACH FOR THE TREATMENT OF MULTIPLE TRAUMATISED TEETH

Hatirli, Hüseyin*, Yasa Bilal
Izmir Katip Celebi University, Turkey
Department of Restorative Dentistry
Izmir, Turkey

Keywords: dental trauma, treatment of traumatised teeth, trauma and silicone matrix

Purpose: Anterior dental trauma(ADT) is the most common injury pattern of the dentoalveolar system among children and adolescents. Traffic accidents and physical fights, sporting injuries and hitting an object are general causes of ADT. Traumatized anterior teeth need quick, effective and esthetic treatment because it is thought that tooth loss in anterior region is unfavorable due to psychological and social terms especially for younger patients. When an anterior trauma contains multiple teeth, esthetic management of trauma becomes more challenging. The aim of this case report is esthetic and practical management of anterior dental trauma affecting all anterior region caused by hitting pool ball.

Methods & Materials: 21 year-old male patient, who was hit by pool ball when he was playing in a competition two years ago, referred to our clinic with esthetic complaints. He neglected his treatment after trauma and did not refer to anywhere. All of the right and left upper central incisors and laterals were affected by trauma, both of the central incisors fractured horizontally from middle third and laterals had mesially inclined oblique fracture. Owing to positive radiographic and clinical findings, direct composite restorations with the help of silicone matrix were concluded for the treatment. Impression was taken and cast model was obtained. Fractured teeth were restored on cast model and silicone matrix(Express XT putty soft, 3M ESPE) was prepared. After bevelling and etching fracture surfaces, an etch-and-rinse bonding system (Optibond FL) was applied. Teeth were restored with enamel and dentin composite resins with incremental technique (Filtek Ultimate, 3M-Espe) by means of silicone matrix. Restorations were finished and polished with diamond burs and polishing disks and polishing paste.

Results: At six month follow-up control, restoration results were very satisfying for both the patient and dentist. Restorations demonstrated quite acceptable colour match and aesthetic appearance.

Conclusion: If an anterior dental trauma affects more than one tooth, reestablishment of esthetic and function becomes more difficult because of distribution of spaces for achieving natural appearance. Balancing of spaces after fractures on the cast model and obtaining of silicone matrix prior to the treatment increase the control and make the final restorations easier.

PLEASURABLE SMILE DESIGN FOR SEVERELY DAMAGED TEETH

Kanik, Özgür*, Atalay, Yusuf
Afyon Kocatepe University
Restorative Dentistry, Oral and Maxillofacial Surgery
Afyonkarahisar, Turkey

Keywords: Fiber post, dental implant, smile design

Purpose: To design a pleasurable smile and functional mastication with preventive multidisciplinary treatment approach.

Methods & Materials: A twenty year-old male was referred to the department of restorative dentistry for aesthetical and functional problems which effected to his social life and psychological situations negatively. Clinical and radiological examination was revealed that there were loss of teeth, translocated teeth and severely damaged teeth in the oral cavity. After extracting upper second molars, upper right first molar and upper anterior region teeth with excessive crown loss were treated endodontically (Flexmaster,VDW,Munich,Germany). Following endodontic treatments, severely damaged upper anterior abutment teeth were restored with fiber posts (UniCore,Ultradent,USA) and resin composites. Fiber posts were fixed into the root canals with dual-cure self-adhesive resin cement (G-CEM Automix,GC Corp.,Tokyo,Japan). Afterwards, all abutment teeth were prepared for the prosthodontic treatment and finished with fixed metal-based ceramic restorations. Moreover, two dental implants (BioHorizons,USA) were inserted to lower left posterior region and implant supported metal-based ceramic restorations were cementated after a period of three months required for a proper osseointegration.

Results: A pleasurable smile and fuctional mastication were designed with preventive multidisciplinary treatment approach. The cost and the surgical treatment procedures was decreased with the advantages of fiber posts. Besides, functional mastication comfort of the patient was increased due to fixed prosthodontic dentures. Above all, the new oral view of the patient was effected to his social life and psychological situations positively more than predicted.

Conclusion: Application of fiber posts with dual-cure self-adhesive resin cements is a preferable preventive and restorative approach for aesthetical and functional rehabilitation of severely damaged teeth.

TOOTH DISCOLORATION AND WHITE MINERAL TRIOXIDE AGGREGATE AFTER TRAUMATIC INJURY

Kisbet Durmuslar, Simge*, Ölmez, Aysegül , Akça,Gülçin
*Bülent Ecevit University
Pediatric Dentistry
Zonguldak, Turkey

Purpose: A number of vital pulp therapy techniques have been recommended to preserve pulp vitality in teeth with complicated crown fractures, especially in young patients. These treatments aim to preserve pulp vitality to development of lateral root dentin to prevent cervical root fractures caused by thin dentinal walls in young permanent teeth with closed apices. For this purpose recently, Mineral Trioxide Aggregate (MTA) has been recommended as a pulp capping material. However, discoloration following MTA pulpotomy is a significant clinical complication. This case report describes the treatment of tooth discoloration caused by white MTA (WMTA) used for the management of a complicated crown fracture.

Methods & Materials: Twelve-years-old patient was referred to clinic 4 hours after trauma. A partial pulpotomy was performed with the use of WMTA after a complicated crown fracture of the upper right central incisor. At 12 months, the patient and his parents were concerned with the crown discoloration. Therefore the pulp chamber was reaccessed and upon access, the WMTA was discolored. A high-speed round stainless steel bur without water was used to remove only the discolored WMTA. The removed WMTA particles were collected into a glass petri dish and microbiological analyzes were performed.

Results: Candida non-albicans species were detected according to a conventional microbiological test. After the discolored WMTA was removed, a significant color change was observed in the tooth crown. Most of the discoloration was with in the WMTA and not in the dentin. Therefore, internal bleaching may not be required. The patient was recalled 6 months later, and there was no change in the color of the crown; the tooth continued to respond to pulp vitality testing. There were no clinical and radiographic pathology at 18 months-follow-up.

Conclusion: Although the MTA is very successful as a pulp capping material in teeth with complicated crown fractures, this case confirmed that WMTA was responsible for the discoloration of tooth. Therefore, the use of WMTA in the esthetic zone after traumatic exposure of the pulp, with its potential for discoloration of tooth structure, might be questioned. Further research is required to determine the chemical process leading to color alteration.

POST-TRAUMATIC PULP DYSTROPHIC CALCIFICATION - REVIEW AND CASE SERIES

Marques, Fernando*, Ramos, João; Vinagre, Alexandra; Costa, Ana; Chambino, Ana
Faculty of Medicine, University of Coimbra
Dentistry Department
Coimbra, Coimbra, Portugal

Purpose: The purpose of this paper is to review the current literature on the subject post-traumatic pulp dystrophic calcification (PDC), addressing the various treatment options illustrated with 10 clinical reports, including different types of dental bleaching, composite restorations, partial composite veneers and ceramic crowns with 3 to 12,5 years of clinical and radiographic controls.

Methods & Materials: Literature search was carried out from a database of medical articles (Pubmed/Medline and EBSCOhost), using as keywords "dental", "trauma", "pulp obliteration" and "dental pulp calcification" (MeSH term), without temporal limits. A group of 12 articles were selected taking the scientific content and integral text availability. Ten clinical reports are presented in detail with different treatment options and with significant clinical and radiographic controls.

Results: Pulp dystrophic calcification (PDC) or pulp canal obliteration is defined as a pulpal response to trauma that is characterized by deposition of hard tissue within the root canal space. The exact mechanism of pulp calcification is still partial unknown, but the damage to the neurovascular supply of the pulp is probably significantly related to this process, with dentin formation by odontoblasts. Clinically, the pulp cavity is partial or totally filled with mineralized tissue. Studies indicate a direct relation between severity of dental trauma and develop of teeth with PDC (3-7% in concussion, 8-11% in subluxation, 9-45% in luxation) and 1-16% of teeth with PDC develop pulpal necrosis.

Conclusion: The radiographic and clinical characteristics allow a proper diagnosis of PDC. The more severe the trauma is, higher the probability of PDC developing and pulpal necrosis with periapical periodontitis occurring. The treatment plan should be progressive and minimally invasive, with bleaching techniques and/or conservative adhesive restorative procedures, complemented with frequent clinical and radiographic controls, allow the optimization and maintenance of functional and aesthetic results, without the additional costs and risks inherent to endodontic treatment. Root canal treatment is not recommended unless previous symptomatology or periradicular pathology is presented.

MULTIDISCIPLINARY APPROACH OF COMPLEX TRAUMATIC DENTAL INJURIES: CASE REPORTS

Ramos, João*, Costa, Ana; Marques, Fernando; Vale, Francisco; Palma, Paulo
Coimbra Medical School; University of Coimbra; Portugal
Department of Dentistry
Aveiro, Aveiro, Portugal

Purpose: The sequelae of dental trauma can be serious and, potentially, resulting in biological, structural, physiologic, esthetics and, even, psycho-social consequences. Often, the approach and appropriate resolution of more complex cases requires multidisciplinary treatments involving surgical, periodontal, endodontic, restorative, prosthetic, implant, orthodontics and preventive procedures. Purpose: The aim of this work is to present 4 clinical complicated cases of dental trauma involving anterior permanent teeth.

Methods & Materials: This series of clinical cases illustrates 4 patients (ages 7-21 years) with complex traumatic dental injuries involving 11 teeth that, globally, include complicated crown fractures with pulp involvement, luxations, avulsions, dento-alveolar fractures and several soft tissue lesions. Besides the primary traumatic lesions the patients showed some secondary pathologies as pulp necrosis, an apical cyst, tooth discoloration, interruption of root development, root resorption and tooth loss. The overall rehabilitation of these cases comprised inter-disciplinary approaches including: tooth-splinting; conventional endodontic treatment and apexification procedures with mineral trioxide aggregate; conventional and laser soft tissue surgeries; ablation of an apical cyst and bone regeneration; adhesive fiber post cementation with a dual-cure composite resin; crown restorations with a direct composite resin stratification technique using a customized silicon matrix; bleaching therapies; orthodontic procedures; dental implant and ceramic crown placement; and mouthguards fabrication.

Results: After a clinical and radiographic average follow-up period of 4 years all the subjects showed good outcomes concerning biological, structural, physiologic and esthetics evaluation.

Conclusion: Conservative and progressive approaches, combined with multidisciplinary and complementary treatments, provide an adequate oral rehabilitation of some complex traumatic dental injuries and their resultant complications.

TURNER TOOTH – A CLINICAL CASE REPORT

Schwartz, Luiz*, Abad, Ernani; Machado, Andreia; Cortes, Antonieta; Almeida, Bernardo
Estacio De Sa
Endodontics
Rio De Janeiro, Brazil

Purpose: This work presents the clinical conduct adopted by the team of dental professionals in the Trauma Project of Estácio de Sá University, facing a case in which the patient presented localized enamel hypoplasia, "Turner's Tooth", caused by trauma with intrusion of predecessor deciduous teeth and approximately one year and a half later, it was noticed the formation of an abscess which made it necessary to look for specialized dental care that led to the decision to perform the extraction of the remnants of intruded teeth.

Methods & Materials: Three months after tooth extraction, the eruption of permanent teeth started. During the process of permanent teeth eruption it was observed the presence of yellow brownish colour stains and the enamel was 'weak' which caused painful sensitivity to cold, hampering the dental hygiene and consequently causing damage to aesthetics. On this occasion it was decided to conduct expectant treatment with provisional restorations with glass ionomer. When the incisors were completely erupted the group of dentistry professionals, aiming at the appropriateness of buccal means, held dental prophylaxis and the polishing of upper and lower arches as well as hygiene orientation and after the absolute isolation the enamel microabrasion was conducted by using a compound of hydrochloric acid on concentration (6%) and associated with micro particles of silicon carbide. In the same clinical section, restorative procedure was accomplished. The restoration was carried out using the technique of stratification which sought to recreate the internal anatomy with resin to create greater body opacity, covered with enamel resin with greater translucency, for this, which allowed to recreate the existing transparency and brightness in natural teeth.

Results: Clinical control has been done every three months in which pulp vitality tests are conducted and after the period of 18 months, the teeth continue to present a normal pulp response and with no other complaint by the patient.

Conclusion: A growing number of deciduous teeth is affected by trauma or by carie lesions which cause localized infection, bringing about alterations in the development of successor permanent teeth. Localized enamel hypoplasia, "Turner's Tooth", is one of several types of existing hipoplasias. When this type of alteration in dental development occurs in permanent anterior teeth, it also tends to cause behaviour problems and psychological disorders with loss or decrease in self-esteem and social marginalization due to changes in the aesthetics and weakening of self-esteem.

RECONSTRUCTION OF A TRAUMATIZED ANTERIOR TOOTH: RESTORATIVE APPROACH

Serim, Merve Efe*, Ozel, Emre
Faculty of Dentistry, University of Kocaeli
Department of Restorative Dentistry
Kocaeli, Turkey

Purpose: The aim of this report is to present re-establishing lost dental esthetic appearance caused by trauma, using universal adhesive system and layering technique.

Methods & Materials: A 15-years old female patient with a fractured maxillary right permanent central incisor was referred to our clinic. Clinical and radiographic examinations confirmed coronal fracture. The long axis of tooth was located to the vestibular side. Fracture zone was paralel to horizontal plane. During vitality test it was observed that the tooth was vital. As a first step of treatment procedure, beveling with diamond bur was performed. The tooth was etched with 37% phosphoric acid, restored with an adhesive system (Single Bond Universal Adhesive, 3M ESPE, USA) and nanocomposite (Filtek Ultimate Universal Restorative, 3M ESPE, USA). A1 enamel, A2 body and dentin shade of the resin composite was used as layering technique. Finishing and polishing procedures were performed by discs and burs. Recalls were performed at the end of two weeks and six months.

Results: At the end of six-months, clinical and radiographic examinations revealed successful rehabilitation of the fractured tooth according to the modified United States Public Health Service (USPHS) criterias. The patient was satisfied with the final result.

Conclusion: The treatment of anterior region's traumas in a single appointment would provide patient's expectation as well as preventive of remaining dental hard tissues.

ADHESIVE TOOTH FRAGMENT REATTACHEMENT WITH INTENTIONAL REPLANTATION: 24-MONTH FOLLOW-UP

Serin, Buse Ayse*, Dervisoglu, Zeynep; Akgun, Erkan Onur; Dogan, Cem
Cukurova University
Pediatric Dentistry
Adana, Yuregir, Turkey

Keywords: crown fracture, dental trauma, tooth reattachment

Purpose: Crown-root fracture is one of the most challenging fracture types in dental traumatology literature. Aesthetic and functional rehabilitation is the primary goal of the treatment of crown-root-fractured tooth.

Methods & Materials: This paper reports the case of a reattachment of a complicated crown-root fracture with intentional replantation in a 16-year-old boy patient.

Results: At the 24-months follow-up appointment, clinical and radiographic examination revealed a normal aspect.

Conclusion: Reattachment of the fragment to its original position for crown-root fracture should be an alternative treatment choice.

FIBER REINFORCED COMPOSITE BRIDGE WITH EXTRACTED AND BLEACHED TOOTH

Sisman, Reyhan*, Dayi, Burak*. Yalcin, Muhammet*
Faculty of Dentistry, İnönü University
Restorative Dentistry
Malatya, Turkey

Keywords: glass fiber, intracoronary bleaching

Purpose: In today's dental practice for anterior restorations patients have to wait for more conservative and aesthetic procedures also as quickly and economic as possible.

Methods & Materials: A 50 year old male patient's left upper central tooth was planned to be extracted because of periodontal disease, was referred to our clinic. After radiographic, periodontal and prosthetic assessments it was decided to use extracted tooth as pontic with glass fiber to be drawn in the bridge. After tooth extraction and healing, root was cut. Pulp chamber was cleaned and filled with sodium perborate for intracoronary bleaching due to discoloration. It was stored in distilled water for 2 days. Bleaching agent was removed, apical hole and incisal fracture were restored with universal micro hybrid composite. It was prepared grooves on palatal surfaces of bleached crown and adjacent teeth. The bleached crown was placed into the edentulous space as a pontic with the aid of contact surfaces. The palatal grooves were etched with %37 phosphoric acid, rinsed and air-dried. The bonding agent was applied and light cured. The required length of glass fiber was cut and fitted into grooves which were pre applied flowable composite. Restoration was completed with universal micro hybrid composite. The occlusion was controlled, contacts were eliminated. Embrasures were conformed and polished.

Results: The clinical situation has been observed successfully with photographs taken 1 and 6 months later.

Conclusion: In appropriate cases fiber-reinforced composite bridges are aesthetic, rapid and economic like anterior restoring single tooth missing using the natural tooth. But this restorations should be followed in terms of long-term success.

LATERAL LUXATION INJURIES MANAGEMENT IN YOUNGER PATIENTS WITH NOVEL TECHNOLOGIES

Türk, Gülnur Isil*, Kaki, Gültür Devrim**, Keskin Tunç, Serap***. Kara, Emine*
Yuzuncu Yil University

*Department of Restorative Dentistry **Department of Endodontics ***Department of Oral and Maxillofacial Surgery
Van, Turkey

Keywords: lateral luxation, laser, ribbon

Purpose: Lateral luxation injuries are commonly seen on young people and children. As all traumatic injuries, it is also thought to be an 'urgent case'. Lateral luxation is defined as the displacement of the tooth in a direction other than axially and this kind of trauma is rarely increased mobility and it is so painful during hard and soft tissue examination. Traumatic injuries cause estetical, fonetical and functional problems. In cases of traumatic injuries, biostimulation of soft tissue wound providing to healing lesion faster by using diode laser and less post-traumatic discomfort and pain. The aim of this current study is consideration of treatment procedures of the patients with different ages who suffered from traumatic injuries and diagnosed as lateral luxation.

Methods & Materials: Three patients between 8-19 years old who suffered from traumatic injuries that came to our clinic and diagnosed as lateral luxation are added this study. Firstly, traumatic area is cleaned with saline solution. Then, the tooth is repositioned by digital pressure in local anesthesia into its original location. Polietilen Fiber Strip (Ribbon, USA) is used for splinting material in all cases. There were no alveolar bone fracture so that splinting period ended after three week. To accelerate the healing process of soft tissues, diode laser Ezlase 940 (Biolase, USA) was performed at the first, third and seventh days of treatment.

Results: In some cases, the teeth which gave negative answer to vitalometer in the beginning of treatment, turned to positive. But some of teeth were needed root canal treatment. Clinical and radiographic controls of cases are still pending. There were no teeth loss or unexpected result in each cases.

Conclusion: Early intervention of traumatic injuries always raises the success of treatment. Furthermore, patients co-operation and oral health motivation also effect the result of the treatment.

THE AESTHETIC RESTORATION OF TRAUMATIZED TEETH

Umar, Ibrahim*, Kamalak, Hakan. Yalçın, Muhammet
Inönü Üniversty
Restorative Dentistry
Malatya, Turkey

Keywords: aesthetic, teeth, trauma

Purpose: The injuries occurring as a result of trauma is often seen in anterior teeth and is one of the emergency dental problems after caries. The traumatized teeth are generally treated with fiber post, composite build-up and crown-restoration techniques on the back of endodontic treatment. This case report aimed to report the treatment 18-years-old male with enamel-dentin complicated crown fracture which is seen together with pulp expansions due to a trauma.

Methods & Materials: In extraoral examination of the patient with visual inspection, a swelling, redness, hemorrhage and ecchymosis were determined on the lips. In the intraoral examination, tongue and sublingual examination of the patient, not any pieces of fractured teeth were detected. The teeth were evaluated in terms of discoloration. The teeth were determined to be mobile and sensitive in percussion. On palpation, soft tissue swelling in the mucosa was determined. Vitality tests can be misleading in the early stages of treatment. Transillumination was used for understanding whether the tooth is necrosis or not. Radiographically, localization of the fracture was detected, and an expansion on laminadura was observed. Two dentin pins for each tooth were planted onto the dentin surface of teeth. The around of pins were enclosed with flowable composite. Then a transparent matrix band was adapted to mesial and distal edges of the teeth and was fastened up with appropriate wedge. Then afterwards, phosphoric acid gel of % 37 and bonding agent (Clearfil SE Bond, Kuraray, Japan) were applied to enamel surfaces respectively and it was restored using composite resin (Arabesk, Voco, Germany) by layering technique. Finally, the restoration was polished with surface finishing discs (Sof-lex, 3M ESPE, USA).

Results: The patient was evaluated after 6 months and not any fractures or discoloration was observed aesthetically. The prognosis of crown fractures depends firstly upon periodontal ligament injury status, then it depends upon pulp open duration, upon the width of dentin surface and root growth phase. The optimum treatment results depend on the emergency assessment and care.

Conclusion: What is important in practice of pins is that the selection of the appropriate pin should be done according to preference and experience of the physician, and those factors like appropriate pin size, appropriate distance remaining between the arc should be taken into account when making choice. Developments in materials brings different dimensions to researches. In recent years studies, various adhesive resins are used to increase the retention of pins.

REHABILITATION OF TRAUMATISED-ANTERIOR-TEETH WITH E-MAX CAD ENDOCROWNS INCREASED INTRARADICULAR RETENTION

Yasa, Bilal*, Hatirli, Huseyin
Izmir Katip Celebi University, Faculty of Dentistry
Department of Restorative Dentistry
Izmir, Turkey

Keywords: Endocrown, Increased retention, CAD-CAM

Purpose: The endocrown is described as a monolithic ceramic bonded construction characterized by a supra-cervical butt joint, retaining maximum enamel to improve adhesion. The endocrown invades the pulpal chamber, but not the root canals. It can be applicable if the remaining tooth structure is sufficient support. Unless the remaining tooth structure have enough support, including of root canals to preparation of endocrown may increase support and also retention. The aim of this case report is rehabilitation of old and fractured restorations on traumatised anterior teeth with E-max CAD endocrowns increased intra-radicular retention.

Methods & Materials: 25-year-old female patient, who has old and fractured restorations on traumatised both upper central teeth, referred to our clinic with aesthetic complaints. It was mentioned about on dental history that she had a trauma and received a treatment after endodontic therapy two years ago. Secondary trauma on right central and unesthetic restoration on left central were observed at intraoral examination. Owing to positive radiographic and clinical findings, endocrowns were concluded for the treatment. Because of extensive loss of structure caused by previous treatment preparation elongated to the root canals for increased anchorage and support. After impressions were taken with polyether impression material, E-max CAD endocrowns were milled under CAD-CAM system (Cerec, Sirona, Germany). Individual characteristics were obtained using cut-back technique. Restorations were cemented with a dual-cure luting cement (Variolink N, Ivoclar). Following the excess cement was removed, restorations were finished with ultra-fine burs and ceramic polishing paste.

Results: At 6-month follow-up, E-max CAD endocrowns were demonstrated highly satisfied clinical performance. Marginal and gingival adaptation of restorations were perfect. Clinically perfect color matching of natural tooth color were obtained thanks to cut-back technique.

Conclusion: Although preparation of endocrown is limited pulp chamber and possibly root canal entrance, it may be elongated thorough root canal carefully in order to increased retention and support. And also, thanks to developments in digital technology, it is possible that natural-like restorations can be obtained with CAD-CAM system.

RESTORATION OF MISSING PERMANENT ANTERIOR TEETH AFTER TRAUMA

Zilberman, Uri*
Barzilai Medical Center
Pediatric Dental Unit
Ashkelon, Israel, Israel

Keywords: avulsion, restoration, everStick

Purpose: Restoration of missing permanent incisors following trauma is a challenging task in the dental clinic. The possibility to restore immediately after trauma is beneficial for both the patient and his family. The purpose is to evaluate the use of glass-fiber ribbon (everStick C&B by GC Corporation) based composite performed tooth as provisional or final restoration of the missing tooth.

Methods & Materials: Case no 1. BR, 10 years following a dental trauma that arrested root development of tooth #21. The tooth was treated at Barzilai dental clinic according to the protocol with calcium hydroxide followed by a root canal treatment and followed for 5 years, without any clinical or roentgenographic pathology. After 5 years the patient underwent orthodontic treatment followed by a build-up and a ceramic crown in another clinic. The patient returned to Barzilai dental clinic due to mobility of tooth #21 and fistula on the buccal surface of tooth 22. The X-ray and CT scan revealed a broken root and a large radiolucent lesion, that caused also tooth #22 to be mobile too. The tooth was extracted and the lesion was filled with artificial bone. Two days following the surgery, the missing tooth was restored using the everStick C&B glass fibers ribbon attached to the buccal surface of upper front teeth and composite material (G-aenial A2 by GC Corporation). Case no 2. KS, two days after a head injury that caused the avulsion of tooth #12 and of a ceramic crown on tooth #21. Tooth #21 was restored with composite material using the Odus celluloid crown , everStick C&B glass fibers ribbon was attached to the palatal surfaces of the upper teeth and tooth #12 was restored using composite material (G-aenial A2).

Results: Six months follow-up showed very good esthetic results and the patients were satisfied with the restorations.

Conclusion: Conclusion: Glass-fibers ribbons (everStick C&B) together with composite materials (G-aenial) can be used safely and effectively for restoration of missing permanent upper incisors as soon as possible after dental trauma in order to restore missing permanent teeth.

Case Posters- Oral & Maxillofacial Surgery/ Transplant/ Implant**ORTHODONTIC TREATMENT COMBINED WITH
AUTOTRANSPLANTATION: TWO CASE REPORTS**

Akçay, Huseyin*, Veli, İlknur; Akçay, Huseyin; Ulusoy, Nazlı; Ozen, Emrullah; Arslan, Hakan
Izmir Katip Celebi University
Oral Maxillofacial Surgery
Izmir, Turkey

Keywords: Autotransplantation, Orthodontic Treatment, Autogenous Repositioning

Purpose: Autotransplantation refers to the autogenous repositioning of a tooth in a surgically formed socket when a suitable tooth is available and anatomic circumstances are favorable. The aim of this study was to present two multidisciplinary approaches including orthodontic treatment and autotransplantation of permanent premolars.

Methods & Materials: Case Report: The first patient was a 14-year-old adolescent girl who referred to orthodontic department with the chief complaint of crowding. Pretreatment intraoral and radiographic examinations revealed an Angle Class I molar relationship on both sides and periapical lesion in mandibular left first molar. The patient had mild and moderate crowding in her maxillary and mandibular dental arches, respectively. The maxillary and mandibular incisors were labially inclined and therefore, orthodontic treatment with the extraction of four premolars was proposed as the treatment plan. Also extraction of mandibular left first molar and autotransplantation of maxillary left first premolar was planned. After preparation of recipient site, the donor tooth was extracted and rotated 90° during placement in the recipient site. The donor tooth was held in position with wire fixation during the healing period for 6 weeks. After 6 weeks fixed orthodontic treatment was initiated. At the end of 2 months, the tooth was found devital and root canal treatment was performed. The patient was observed for 7 months and no resorption was detected. The second patient was a 12-year old female. In her intraoral and radiographic examinations, congenitally missing mandibular left central and mandibular left second premolar, impacted maxillary right-left second premolars and persistent deciduous mandibular left first molar were detected. Further examination with cone-beam computed tomography revealed no root formation in maxillary left second premolar. Treatment plan for this patient was to extract the impacted maxillary left second premolar and persistent deciduous tooth and then autotransplantation of maxillary right second premolar to deciduous tooth site. The donor tooth was held in position with wire fixation for 6 weeks. After 6 weeks fixed orthodontic treatment was initiated. At the end of 6 months, the tooth was found vital and on the panoramic radiograph, no signs of inflammation in the recipient site were detected.

Results: Multidisciplinary approaches including orthodontic treatment and autotransplantation of permanent premolars was successful in the short term controls of our two cases.

Conclusion: Multidisciplinary approaches including orthodontic treatment and repositioning of an extracted premolar by autotransplantation, is a viable option for suitable cases. However further follow-up is needed to evaluate the long term effect and success.

IMPLANT COMBINED WITH REGENERATIVE PROCEDURES TO MANAGE SEVERE DENTOALVEOLAR TRAUMA

Akman, Abdullah C*, Elçin Süküroğlu**, Sevim Günday*, Emel Tugba Ataman*
Hacettepe University Periodontology Karadeniz Technical University Prosthetic Dentistry
*Periodontology **Prosthetic Dentistry
Ankara, Turkey

Purpose: Trauma due traffic accidents may cause severe damage to the teeth and alveolar bone system. Tissues affected and lost may present difficulties for successful rehabilitation. Use of dental implants combined with regenerative bone surgeries may be the choice of treatment to overcome esthetic and functional shortcomings. In this case report, a 28 year old male patient who lost 8 teeth in the maxilla and 6 teeth in mandible including almost all anterior teeth after a car accident was treated dental implant supported fixed restorations and a 5 year follow up is presented.

Methods & Materials: A 27 year old male patient with complaints of esthetically and functionally unsatisfactory teeth supported fixed prosthesis presented to our clinic. After clinic examination, radiographic and tomographic evaluation, bone augmentation and implant placement for implant supported fixed prosthesis was decided. Remaining roots of the missing mandibular teeth was extracted and sockets were augmented using autogenous bone-bovine HA mixture and collagen barrier membrane. Four months later implants were placed in augmented sites. In maxilla, where the remaining bone was inadequate, bone splitting was performed to increase bucco-palatinal dimensions and four implants were placed simultaneously. Four months after the placement of the implants fixed bridges were fabricated.

Results: Six months after the prosthetic rehabilitation implants were found to be clinically and radiographically healthy except for mild peri-mucositis infection around several implants due to poor oral hygiene. The patient was satisfied with the functions and esthetics provided by the implant supported restorations. The clinical status was maintained for the following 5 years with routine visits and prophylaxis.

Conclusion: Atrophy of the alveolar bone seen after the loss of teeth due to trauma may result with a residual crest severely inadequate for placement of dental implants. Guided bone regeneration and bone splitting applications may increase the dimensions of the remaining bone and enables the use of dental implants.

SURGICAL REPOSITIONING OF A COMPLETELY INTRUDED MAXILLARY LATERAL INCISOR

Aykut Yetkiner, Arzu*, Çağır Dindaroglu, Funda; Ersin, Nazan
Ege University Faculty of Dentistry
Pediatric Dentistry
Izmir, Turkey

Keywords: surgical repositioning, intrusive luxation

Purpose: This report aimed to present a case of severe intrusive luxation of mature maxillary left lateral and extrusion of central incisor of an 11-year old boy.

Methods & Materials: His maxillary central incisor was repositioned and splinted with a rigid splint by another dentist. He referred to our clinic because of his missing permanent maxillary lateral incisor. Radiographic examination revealed a completely intruded permanent maxillary left lateral incisor to the interdental bone beyond 7 mm. A flap was raised to expose the crown of underlying intruded lateral incisor followed by gently luxating the tooth with dental forceps and was brought back into the desired position. After repositioning to normal occlusion and suturing the soft tissue, tooth was stabilized and splinted with flexible splint for four weeks. Pulp extirpation and calcium hydroxide dressing of the root canals of maxillary left incisors were carried out immediately. Definitive root canal treatments were accomplished 2 weeks later.

Results: Clinical and radiographic examination during recalls and after 9 months revealed no signs of progressive root resorption, marginal bone loss or periapical disease.

Conclusion: Surgical repositioning can be suggested as a successful treatment of choice for completely intruded permanent incisors in some cases.

REIMPLANTATION OF A FUSED INCISOR FOLLOWING INTENTIONAL EXTRACTION FOR HEMISECTION.

Cehreli, Sevi Burcak*, Gülsahi, Kamran; Ates, Ufuk; Keçik, Defne; Tirali, Ebru; Sahinoglu, Zahir; Çehreli, Burçak
Baskent University Faculty of Dentistry
Pediatric Dentistry
Ankara, Turkey

Purpose: Fusion is the union of dentin and/or enamel of two or more separate developing teeth. This morphoanatomic anomaly may result in esthetic problems as well as malocclusion. The aim of this case report is to present management of a central incisor fused with a supernumerary tooth.

Methods & Materials: The patient was 12 year-old otherwise healthy male who attended to the department of pediatric dentistry with a complaint of unpleasant esthetics in maxillary anterior region. Clinical and radiographic evaluation showed that the problem was related with fusion between maxillary left central incisor and a supernumerary tooth. There was inadequate space for eruption of right maxillary canine, thus, orthodontic treatment was indicated. Interdisciplinary evaluation by an orthodontist, pediatric dentist, oral surgeon and endodontist ended up with a decision of extracting the fused teeth, performing hemisection and root canal treatment extraorally, and reimplanting the sectioned central incisor. Surgical interventions were accomplished following the consent of the patient. The incisor and supernumerary tooth was separated extraorally. At the moment of reimplantation, the tooth was positioned rotationally, as its previous position in order to obtain adequate immobility in the large socket. Further stabilization was accomplished with a semi-rigid fisherman splint. At the same appointment root canal therapy was initiated. Splint was removed and endodontic therapy was completed after 2 weeks. After this appointment the patient did not attend to control visits. Orthodontic treatment was initialized within 1 year post-operatively. At that time, reimplanted central incisor was ankylosed. Therefore, the tooth was not bonded to the arch-wire and it was still in rotational position. The patient moved to another city and another orthodontist continued the treatment.

Results: The reimplanted tooth is in function preserving the alveolar ridge.

Conclusion: Although the treatment is ended up with ankylosis, the reimplanted tooth is serving functionally for 4 years, as an interim solution until the orthodontic treatment is completed and the patient is ready for fixed prosthodontic rehabilitation. Orthodontist and pediatric dentist should work as a team in order to prevent unexpected complications of orthodontic treatment in arches with an ankylosed tooth.

INFECTION AFTER WIRE OSTEOSYNTHESIS TECHNIQUE OF MANDIBLE FRACTURE

Celik Topcu, Pinar*, Coskunes Fatih Mehmet, Cilasun Ulkem, Kan Bahadir
Kocaeli University Faculty of Dentistry
Oral and Maxillofacial Surgery
Kocaeli, Turkey

Purpose: Mandibular fractures are the most common facial fractures in maxillofacial area. The treatment goal is to restore the mandible structure, proper occlusion and chewing function with the lowest morbidity and complication rate. Wire osteosynthesis technique which caused an infection of tooth is presented in this report.

Methods & Materials: 31 years old man referred to Kocaeli University Faculty of Dentistry Oral and Maxillofacial Surgery Department with the pain and intraoral abscess in region of the left second molar tooth. In radiological examination, a wire and radiolucency around the related tooth was observed. According to the patient's statement, he had a fracture in mandible corpus area and had wire osteosynthesis treatment in 1998. Under the local anesthesia the fixation wire was removed and surgical extraction of the tooth is made.

Results: Mandibular fracture treatment with wire osteosynthesis technique at the apical region of mandibular second molar tooth caused neurovascular damage.

Conclusion: Even though wire osteosynthesis technique is an easy and effective method with low cost and especially useful in small isolated fragment fractures, it may complications such as neurovascular damage and infection.

COMPREHENSIVE TREATMENT OPTIONS OF COMBINATION INJURIES WITH UPPER INCISORS

Chen, Yong-Jin*, Liu, Yan-Li, Zhan Min
College of Stomatology, Fourth Military Medical University
Department of General Dentistry & Emergency
Xi'an, Shaanxi, China

Purpose: Combination injuries is defined as complex oral disease. It may have serious medical, aesthetic, and psychological consequences on patients. This is a case about treating an adolescent patient with serious combination injuries in upper incisors. The left central incisor has crown fracture with avulsion. The right central incisor has extrusive luxation, and the right lateral incisor has subluxation and crown-root fracture.

Methods & Materials: All the injured teeth were fixed with titanium trauma splint (TTS). This case involved operative evaluation with dental computed tomography and a multidisciplinary approach including surgical, endodontics, periodontal therapy, as well as strengthened postoperative observation and regular follow up.

Results: All the injured teeth had pulp necrosis during treatment in two weeks, and root canal therapies were carried out immediately. Six weeks later, no root resorption was observed on the injured teeth. Then the right lateral incisor was restored with fiber post and composite-resin restoration, and the left central incisor was restored with composite-resin restorations. In the follow up reviews (about one year), All the injured teeth were in the correct position, and the root was in its original position.

Conclusion: We performed a satisfactory treatment of combination injuries. This case illuminates that the timely endodontic therapy is necessary, and titanium trauma splint (TTS) is beneficial to dental trauma. Meanwhile, comprehensive treatment options are important for combination injuries.

INTENTIONAL REPLANTATION WITH EXTRUSION/ROTATION OF AN ABSCESSED CROWN-ROOT FRACTURED INCISOR

Cilensek, Maja*, Sapundzic, Dime, Kriznar, Igor, Plut, Alja, Gaspersic, Rok, Kosem, Rok
University Medical Centre Ljubljana
Clinical Department of Paediatric and Preventive Dentistry
Ljubljana, Slovenia

Purpose: Young permanent teeth with crown-root fractures (CRFs) present restorative challenge, especially when associated with established inflammatory lesions. The purpose of this case report is to present management for a CRF of previously injured and endodontically treated central incisor with paradicular abscess using intentional replantation with extrusion and 180° rotation.

Methods & Materials: A 16-year-old girl was referred for treatment of tooth 11 with CRF. Six years earlier, this tooth reportedly sustained complicated crown fracture and was treated by immediate pulpectomy, root canal filling and composite restoration. Two weeks before referral, it became mobile after a minor traumatic event. After a few days, sensitivity appeared, mobility increased, composite restoration was lost and an abscess developed. Clinical examination revealed transverse fracture line crossing gutta-percha filled pulp cavity of the remaining cervical part of the crown and extending subgingivally. Labial fragment was mobile. An abscess, 7mm in diameter, located labially to the tooth 11 was evident. Radiographically, paradicular radiolucency in the cervical half of the root with an existing incomplete root canal treatment was shown. Tooth 11 was carefully extracted under local anesthesia. Labial fragment was separated, extending 4.5mm below the cemento-enamel junction. Granulation tissue adhering to the remaining labial root surface was removed and the tooth was replanted with 5.5mm extrusion and 180° rotation. Wire-composite splint was applied, amoxicillin/clavulanic acid was prescribed and instruction on importance of plaque control was given. Healing was uneventful. Four weeks later, root canal retreatment was initiated and calcium hydroxide paste was placed for a period of two weeks. Thereafter, root canal was filled with gutta-percha and sealer. Following 6 weeks of immobilization, tooth 11 was orthodontically extruded for another 1mm. After 9 months of retention, gingivectomy with palatal osteotomy was performed to correct the newly established level of gingival margin and to explore the radiographically detected defect of distal marginal bone. Finally, restoration was fabricated with glass fiber-reinforced composite post and composite crown.

Results: At the 2-year follow-up, the patient was asymptomatic. No progression of marginal bone defect distally to tooth 11 was revealed radiographically. There was no evidence of root resorption or periapical pathology.

Conclusion: Intentional replantation appears to be a viable treatment option for CRF-affected teeth even in the presence of paradicular abscesses. Placing the tooth into the socket with extrusion and rotation such that compromised root surface contacted previously healthy socket areas and vice-versa, presumably contributed to successful periodontal healing.

AN ANALYSIS OF MANDIBULAR FRACTURES: REPORT OF 8 CASES

Coskunes, Fatih Mehmet*, Celik Topcu Pinar, Kan Bahadir, Cilasun Ulkem
Kocaeli University Faculty of Dentistry
Oral and Maxillofacial Surgery
Kocaeli, Turkey

Keywords: Mandible, fracture

Purpose: Mandible fractures have a substantial proportion among fractures in maxillofacial region. In the study, we aimed to present the age, mechanism of trauma, gender proportion, anatomic site and treatment modalities of mandibular fractures treated in Kocaeli University Faculty of Dentistry .

Methods & Materials: Data of 8 patients who had been diagnosed and treated with a mandible fracture between May 2013- December 2013 at Kocaeli University Faculty of Dentistry Oral and Maxillofacial Surgery Department was retrospectively reviewed. The patients were evaluated retrospectively for etiology, localization, treatment modalities and complications.

Results: The study comprised 8 patients aged between 19-60 years, (mean age 42) with maxillofacial trauma. All patients were male. Mandible body was the most common site by 62.5 % followed by angle (%12.5), condyle (%12.5) and symphysis (%12.5)sites. All patients were followed for at least 6 months after surgery. Seven of the patients were treated with open reduction except for one who was closely followed-up and advised to take soft diet.

Conclusion: Although associated with some complications, open reduction and miniplate fixation would be preferred in dislocated fractures; since it provides a better fixation and predictable results.

THE VALUE OF DECORONATION PROCEDURE PRIOR TO IMPLANTS REHABILITATION

Diaz, Jaime*, Olate, Sergio ; Weber, Benjamín
Faculty of Dentistry, Universidad De La Frontera, Temuco, Chile
Paediatric Dentistry & Orthodontic
Temuco, Cautin, Chile

Keywords: tooth ankylosis, decoronation, implant rehabilitation

Purpose: Delayed Replant of avulsed permanent teeth in growing patients is frequently complicated with the development of ankylosis, that may result later in aesthetic compromise, orthodontic complications, local arrest of alveolar ridge growth and infraocclusion. Alternative treatment in this cases is decoronation procedure for posterior implants rehabilitation. The aim of this case report is to present a complete 8 years follow-up period of young male patient with dental avulsion of his both upper maxillary central incisors, which received a treatment for preservation of the alveolar ridge by decoronation procedure for future implants rehabilitation.

Methods & Materials: A 10-year-old boy sustained avulsion of both central incisors. Because of the general commitment with clavicle and right forearm fracture, a delayed replantation and splinting were carried out. Both central incisors developed ankylosis and infraosition 30 and 42 months after replantation respectively. He had finished some months ago orthodontic treatment due to severe dentomaxilar discrepancy, which involved the extraction of four first premolars. Thus, there was no possibility of dental transplants. The ankylosed teeth were removed with decoronation procedure to avoid more complications in the alveolar bone volume that could jeopardize future rehabilitation. The patient remained in clinical control and monitoring with radiographs and cone-beam computed tomography (CBCT) until the age of 18 years. These tests showed a continuous and systematic process of intra-alveolar replacement root resorption and alveolar bone remodeling

Results: To date, four years following of the decoronation of both ankylosed upper maxillary central incisors, once the completion of facial growth, two immediate loading oral implants (Zimmer ®) were inserted, followed by prosthetic porcelain crown rehabilitation. During the surgical procedure it was possible to verify and check a complete replacement resorption of the decoronated roots remnants, with an optimal quality of bone tissue which indicated the feasibility of inserting implants without any bone augmentation surgical procedure. After 8 months, the patient presents an adequate functional and aesthetic outcome of implants rehabilitation

Conclusion: To prevent the collapse and disturbances in alveolar bone growth, decoronation should be performed in cases of ankylosed of permanent teeth, where orthodontic closure or premolars autotransplantation are not feasible. The decoronation procedure maintain the alveolar bone ridge and allow implants-supported porcelain crown rehabilitation without the need for another surgical procedure to enhance the alveolar bone volume.

AUTOTRANSPLANTED THIRD MOLARS WITH 3-YEAR FOLLOW-UP: REPORT OF TWO CASES

Efe, Saime Esin*, Ates, Ufuk; Cehreli S. Burcak; Tirali, Ebru; Kaya, Tugba
Baskent University Faculty of Dentistry
Pediatric Dentistry
Ankara, Turkey

Purpose: Autotransplantation of immature or mature third molars for replacement of a nonrestorable molar is a viable treatment alternative. The aim is to present two cases in which third molars were autotransplanted to replace first molars in the mandibular posterior region.

Methods & Materials: The first case described herein is a 16 year-old patient whose chief complaint was spontaneous pain due to flare up of pulpitis on tooth number 36. The medical history of the patient was non-contributory. Clinical and radiographic evaluation revealed pathological mobility and a large periapical lesion respectively. Autotransplantation of tooth 38 for replacement of tooth 36 was planned. In order to eliminate infection at the recipient site, a two-step surgery was performed. First, tooth 36 was extracted and healing of the infected socket was observed in about 4 months. At the second intervention, recipient site was prepared with implant drills, tooth 38 was extracted and autotransplanted into the prepared socket. Primary stabilization was achieved with sutures and supported by wire-composite splint on the lingual side of teeth. Splint was removed after 3 weeks. Continuing apical development was observed on the follow-up appointments.

The second case is a 25 year-old female patient who had a non-contributory medical history. On clinical and radiographic examination, a deep carious lesion and an apical lesion were observed on tooth 46. The patient told that she had an endodontic intervention previously but she did not attend to appointments, thus the treatment was not completed. Due to an unrestorable crown and questionable success chance of endodontic treatment, autotransplantation was considered as alternative. The tooth 46 was extracted and tooth 48 was autotransplanted into the socket of tooth 46 at the same appointment. Stabilization with a fisherman splint was utilized for one-week. Endodontic treatment was performed on the 5th week.

Results: The autotransplanted teeth presented were in full function at the 3rd year follow up.

Conclusion: Autotransplantation is an successful treatment alternative for the molars when an adequate donor is available. The method is simple, has a high long-term success and it has lower-cost when compared with dental implants, orthodontic treatment or prosthodontic interventions.

AUTOTRANSPLANTATION: CRITICAL DECISION MAKING

Guerrero, Alexandra*, Minetto Rossana, Carrasco Mariana
Facultad De Odontologia, Universidad De Valparaiso/ Armada De Chile
Càtedra De Odontopediatria
Concon, Chile

Purpose: Accidental tooth loss in children is a great challenge, since there are not many treatment options, and implants are not indicated in growing patients.

Methods & Materials: A 13 year-old girl, sought orthodontic treatment because of severe crowding in both arches. Class I malocclusion was diagnosed and extraction of the first four premolars was indicated. First extraction of tooth 44 was performed. Afterwards, an unfortunate situation occurred when tooth 45 was wrongly removed instead of tooth 34. This dental error was noticed three hours later. Faced with this critical situation, and according to the orthodontist's indication, autotransplantation of tooth 34 was performed and moved to the position of the recently extracted tooth socket.

Results: At 4-year control and following autologous dental guidelines, the tooth remains functional in its position. On the radiograph, healthy periodontal ligament and bone tissue are observed. The patient is at the final stage of orthodontic treatment.

Conclusion: Decision making, timely management, patient cooperation and multidisciplinary treatment allowed observation of a successful biological, functional and aesthetic result, even in a critical and unfavorable situation. Key Words: autotransplantation, dental errors, multidisciplinary treatment.

MAXILLARY CENTRAL INCISOR INJURY FOLLOWED FOR 4 YEARS WITH CBCT

Igarashi, Mitsuhiro*, Igarashi Naomi
Utsunomiya-City, Tochigi-Prefecture, Japan

Purpose: In children of school age, tooth luxation, crown fracture, and root fracture associated with injury of the permanent maxillary incisor are often caused by accidents in daily life, traffic accidents, and sports and recreational activities. We present here is a case of a 10-year-old patient with subluxation and root fracture of the maxillary right central incisor (tooth 11) and subluxation, crown fracture, and pulp exposure of the left maxillary central incisor (tooth 21) caused by a bicycle accident, which were treated and followed for 4 years with cone beam computed tomography (CBCT).

Methods & Materials: Its utility for evaluating the treatment outcome of root fracture is also discussed along with a review of previous literature.

Results: Particularly interesting findings were observed in the treatment course of tooth 11. On examination, significant mobility of tooth 11 was noted and tooth fixation was performed. No root fracture was detected on either dental or panoramic X-ray. CBCT taken after fixation revealed root fracture at one-third of the distance from the root apex. For tooth 21, pulpotomy was performed using the standard procedure. Due to loss of the fractured tooth fragment, composite resin was used for restoration. Tooth 21 eventually developed pulp infection and was treated by root canal treatment. In tooth 11, although a fracture line was observed immediately after injury, the vital reaction of the pulp was restored around 4 months after injury. CBCT showed progressive separation of the fractured tooth fragments and gradual apex formation from the coronal fragment. The tooth has shown a positive response to the electric pulp test.

Conclusion: The present findings suggest that CBCT is effective for the accurate diagnosis of tooth injury. To decide the treatment of tooth injury, it is important to assess the presence or absence of adequate blood flow to the pulp based on the condition of the apical foramen and the severity of fracture. The outcome of treatment also depends on the growth state of the root, as well as the number and activity of pulp cells, which change with age. The present findings also suggest that the mobility of fracture fragments and the displacement, extension, or rupture of the pulp due to loss of a fragment significantly affect survival of the pulp. These findings suggest that performing appropriate treatment while considering these factors should lead favorable long-term outcomes in patients with tooth injury.

THE ROLE OF DENTAL TRAUMA IN BISPHOSPHONATE RELATED OSTEONECROSIS

Kenan, Sevinc*, Senel, Neslihan** Duymaz, Bilge* Ramazanoglu, Mustafa* Onur, Ozen Dogan*
Istanbul University

*Department of Oral and Maxillofacial Surgery **Department of Oral and Maxillofacial Radiology
Istanbul, Turkey

Keywords: bisphosphonate, dental, trauma

Purpose: Bisphosphonates are drugs used for inhibition of bone resorption in metastatic bone diseases, multiple myeloma, osteoporosis, Paget's disease, osteogenesis imperfecta and hyperparathyroidism. Bisphosphonates function mainly by inhibiting osteoclastic activity and therefore preventing bone resorption. Bisphosphonate-related osteonecrosis of the jaws (BRONJ), which is the most serious complication of this treatment, is defined as the pathologic condition characterized by the presence of exposed necrotic bone in the maxillofacial region for more than eight weeks in a patient who has received bisphosphonate therapy with no history of radiotherapy. Although spontaneous cases are reported, dental trauma is known to be the most important cause of BRONJ.

Methods & Materials: In this study, we evaluated the BRONJ patients who were referred to Istanbul University, Department of Oral and Maxillofacial Surgery between 2011 and 2014. We investigated the etiology of BRONJ including the role of trauma, risk factors associated with the administration protocol of the drug and the underlying disease, serum CTX values, and the overall prognosis of the disease related to these factors.

Results: Trauma caused by dental prosthesis and tooth extraction is the main etiology of BRONJ. The risk of BRONJ is greater with i.v. administration of the drug and correlated to the length of therapy. Prognosis is worse for cancer patients than patients treated for osteoporosis.

Conclusion: Oral surgical procedures, including tooth extraction and implant placement, and traumatic soft tissue injury induced by ill-fitting dentures are the most frequent triggers of this pathology. Sharp protuberances and irregularities of the alveolar bone might render the oral mucosa prone to trauma and cause spontaneous exposures of necrotic bone. The treatment of BRONJ is extremely difficult once it is diagnosed. Therefore elimination of any dental trauma and avoidance of dental surgery during bisphosphonate treatment are essential to prevent BRONJ.

AUTOTRANSPLANTATION OF 2ND MOLARS OF AN 11 YEAR-OLD PATIENT

Tago, Jasper*, See, Karen
Pediatric Dentistry Center Philippines
Pediatric Dentistry
Taytay, Rizal, Philippines

Keywords: autotransplantation, Young-Permanent Molar, Oral Surgery

Purpose: All throughout the age of adolescence, most Filipino at this age could have their 1st molars indicated for extraction for the following reasons: poor tooth-restorability due to severe caries, acute and chronic infections, and costly endodontic treatment. Also, during this stage of life, 2nd molars are developing hence; maintaining the position of the 1st molars is imperative to a suitable occlusion. The aim of this treatment is to perform autotransplantation of young-permanent 2nd molars as an alternative and cost-efficient dental treatment for adolescent patients where first permanent molar is indicated for extraction to be able to maintain a desirable occlusion also allowing the 3rd molar to migrate mesially.

Methods & Materials: This report will present a case of an 11year-old Filipino girl who has undergone autotransplantation procedures of her three young-permanent second molars (Nola's Stage 8) after extraction of severely carious first molars. Prior to treatment, radiographs and diagnostic casts were taken to assess the viability of the donor teeth and recipient sites. The clinician divided the treatment in three appointments (lower right, lower left and upper left) with 1week interval. After extraction of each molar, the recipient site was enlarged and debrided. The second molar was carefully removed from the socket and replanted into the recipient site. The tooth was secured with either flexible splint or silk suture.

Results: Routine radiograph and oral examination were done after 4weeks, 6weeks, and 3months and 6months. The stability of a replanted tooth was attained 4weeks after the treatment, radiographic assessment reveals bone deposition in the alveolar socket on the 6th week, and continues apical development of the three replanted teeth was noticeable 3months after all procedures were done. Mesial migration of the 3rd molars (Nola's stage 5) were also noted.

Conclusion: Autotransplantation of 2nd permanent molars can be an alternative treatment plan when removal of 1st permanent molars is inevitable and 3rd molar is unviable as a donor tooth during adolescent years.

FLAPPING AND NON-FLAPPING SURGERY MANAGEMENT IN COMPLEX DENTAL TRAUMA

Xu, Tao*, Ji, Aiping; Chen, Nan
Beijing, China

Purpose: To compare results of cases with or without flap procedures.

Methods & Materials: Two cases with maxilla incisors displacement and labial bone plate fracture were delay treated for 1-week. In case 1, labial flap procedure was performed during debridement and dislocated teeth were re-implanted back to the sockets after conventional root canal treatment extra-orally. Guided tissue regeneration was applied on the labial bone defect. The re-implanted teeth were fixed with rigid wiring for 3 months. In case 2, the treatment procedures were followed except wound debridement was conducted without flap procedure.

Results: Wiring fixation was discontinued after 3-months and no mobility of the re-implanted teeth were observed in both cases. The labial gingival margin recessions ranged from 2 to 4mm were revealed in case 1. No recessions of labial gingival margin were disclosed in case 2. Results of CBCT exam revealed no significant root resorption of all re-implanted teeth but with labial bone plate deficiency in both cases. The interdental alveolar ridges and papillae tissue were preserved.

Conclusion: The re-implanted teeth were stable because of ankylosis. The margin of the labial gingiva and the shape of the interdental papilla were based on the height of the interdental alveolar ridge. Non-flapping surgery could preserve the shape of the gingiva and the aesthetic with better results than flapping case.

AUTOTRANSPLANTATION-HOW LONG SHOULD THE DONOR ROOT LENGTH BE?

Zagury, Amram*, Zilberman Uri
Barzilai Medical Center Ashkelon Israel
Oral &Maxillofacial Surgery
Ness Ziona, Israel

Purpose: To evaluate the possibility of using a donor mandibular premolar with only one third roots length for autotransplantation in the anterior area

Methods & Materials: Case report: September 2012. BO, a healthy 7.5 years old boy, arrived to ER, Belinson Hospital, Ashkelon, Israel with an avulsed tooth #21, at a basketball play. The tooth was reimplanted after 2.5 hours and splinted with composites. He was observed at the pediatric dental clinic 2 days later. After a week the original splint was broken and the tooth showed mobility 3rd degree. The length of the root of tooth #21 was 10%. The splint was reinforced with glass-fiber perio ribbon (Stick-tech). The pulp chamber was open and filled with Ca(OH)₂, and a protective monoblock was performed in order to keep the tooth in place. After fourteen months and three additional traumas, inflammatory resorption of the stumped root was observed and a decision for autotransplantation of the first mandibular premolar was made. The root length of the premolar was only one third. The procedure was performed under general anesthesia, the upper incisor was extracted and the lower first premolar was removed from the buccal with its follicle. The donor site was prepared and the premolar was placed in the artificial socket with no pressure and the gingiva sutured transversally. The tooth appeared in the mouth three weeks later and restored with composite material to resemble the upper central incisor and splinted for two weeks to the contra lateral incisor.

Results: Follow up of six months showed root growth and favorable esthetic result, and the tooth is ready for orthodontic movement.

Conclusion: Autotransplantation of a premolar to the anterior area after tooth loss have shown very high survival rates, 90-98%, after long periods. There are two accepted protocols for the premolar root length before autotransplantation: for the vital protocol the adequate root length should be three fourth root formation and the for the non vital protocol (with root canal treatment to follow) we can use a premolar with full root length and closed apex. But, with careful evaluation and proper surgical procedure we can consider premolars with only a third of root length for autotransplantation to the anterior area for an avulsed or compromised incisor.

A NOVEL STANDARDIZED BONE MODEL FOR THERMAL EVALUATION OF OSTEOTOMIES

Giannis, Katharina*, Vasak, Christoph; Unger, Ewald; Mittlboeck, Martina; Zechner, Werner; Strbac, Georg

University Clinic of Dentistry, Medical University of Vienna, Vienna, Austria

Unit Division of Dental Student Training and Patient Care

Vienna, Vienna, Austria

Purpose: Based on a novel standardized bovine specimen, the aim of this study was to investigate thermal effects of different irrigation methods during intermittent and graduated drilling.

Methods & Materials: Temperature changes during implant osteotomies (n = 320) of 10 and 16 mm drilling depths with various irrigation methods were investigated on manufactured uniform bone samples providing homogenous cortical and cancellous areas and analogous thermal conductivity comparable to human bone. Automated sequences were performed with surgical twist drills of 2 mm Ø and conical drills of 3.5, 4.3 and 5 mm Ø. Real-time recording of temperature increase was done using two custom-built multichannel thermoprobes with 14 temperature sensors at a predefined distance of 1 and 2 mm to the final osteotomy. The effects of drilling depth, drilling diameter and irrigation methods on temperature changes were investigated by a linear mixed model.

Results: Using this uniform bone specimen, the greatest temperature rise was observed without any coolant supply with 29.87°C, followed by external with 28.47°C and then internal with 25.86°C and combined irrigation with 25.68°C. Significant differences (P = 0.0156) between drill depths of 10 vs. 16 mm could be observed with all irrigation methods evaluated. With each of the irrigation methods, significantly higher temperature changes (P < 0.0001) during osteotomies could be observed between twist drills of 2 mm Ø and conical drills of 3.5, 4.3 and 5 mm Ø. During 10 and 16 mm drilling osteotomies, external irrigation showed significantly higher temperatures (P < 0.05) for all conical drills compared with internal or combined irrigation, respectively. Significantly lower temperatures (P < 0.05) could be detected with internal or combined irrigation for the use of conical drills with various diameters and drilling depths.

Conclusion: This fully standardized bone model provides optimized comparability for the evaluation of bone osteotomies and resulting temperature changes. As regards the efficiency of the various irrigation methods, it could be demonstrated that internal and combined irrigation appears to be more beneficial than external irrigation.

EVALUATION OF LAG-SCREW VERSUS MINIPLATE-FIXATION IN TREATMENT OF ANTERIOR-MANDIBULAR FRACTURES

Lambade, Pravin*, 1) Lambade, Dipti 2) Rajkhokar, Dilpreet

*Swargiya Dadasaheb Kalmegh Smruti Dental College & Hospital, Nagpur

1) V.S.P.M's Dental College & Research Centre, Nagpur

2) Swargiya Dadasaheb Kalmegh Smruti Dental College & Hospital, Nagpur

*Department of Oral & Maxillofacial Surgery 1)Department of Prosthodontics 2)Department of Oral & Maxillofacial Surgery
Nagpur, Maharashtra, India

Keywords: Lag-Screw, Miniplates, Anterior-mandibular Fractures

Purpose: To compare the efficacy & surgical outcome of treatment of anterior mandibular fracture using either lag-screw technique or miniplate Fixation.

Methods & Materials: A total of 70 patients were treated by open reduction & internal fixation utilizing the miniplate & lag-screw technique for fractures of anterior mandible. The patients were randomly divided into two groups Group I (n=35 patients) were treated with titanium (2.5mm×20-22mm) Lag-screws & group II (n=35 patients) were treated with titanium (2mm 4-hole with gap) miniplates. Intraoperative duration of surgery was measured from time of incision till closure of the wound. Preoperative & immediate-postoperative panoramic-radiographs were taken to assess the gap between fracture segments. On the Panoramic-radiograph the infraorbital plane was drawn. Then a perpendicular line was drawn from this plane till the inferior border of mandible 1cm away from the fracture site & it was divided into three equal parts. Perpendicular lines were projected onto the fracture line for reproducible measure points a,b,c&d. Follow up was done at 3,6,12,24 weeks postoperatively & patient was assessed clinically for malocclusion, biting-efficiency & postoperative complications (infection, hardware failure, malunion, non-union, segmental mobility, neurosensory deficit). Results were evaluated using Chi-square & unpaired t-test.

Results: The mean duration of surgery (mins) was 33.86±4.237 for Group I & 49.49±4.341 for Group II. The difference was found to be statistically significant (p value<0.001). The mean post-operative radiographic distance between all measuring points was slightly more in case of Group II as compared to Group I but the difference was not found to be statistically significant (p value>0.001). The biting efficiency of Group I showed faster improvement as compared to Group II. The neurosensory deficit was not noted in Group I whereas it was found to be of transient nature in Group II. In both groups, the occlusion was satisfactory, no malocclusion or non-union was noted. Soft tissue infection was noted in 1 case in Group I & 2 cases in Group II.

Conclusion: According to results of this study, Lag-screw technique has several advantages over Miniplate-fixation technique. The operative time is reduced & also less implant hardware is required in Group I which ultimately reduces incidence of complications. This technique is a better method to achieve Rapid & safe fixation with primary osseous healing especially in linear fractures of anterior mandible and there is early return of function as compared to miniplates.

FRACTURES OF THE MANDIBULAR BODY :A RETROSPECTIVE STUDY

Turki, Asma*, Hadyaoui, Dalenda, Berrezouga, Latifa, Ben Khelifa, Mohamed
Dental Faculty of Monastir
Departement of Oral Surgery and Medicine, FBUH, Monastir, Tunisia
Monastir, Tunisia, Tunisia

Keywords: Fractures , Mandibular body , Retrospective study

Purpose: This study aimed to investigate epidemiological features of mandibular body fractures (MBF) and the treatment options as well.

Methods & Materials: A 10-year retrospective study was conducted, based on 55 documented clinical cases. Patients were treated in the Department of Oral Medicine and Surgery of F. Bourguiba University Hospital of Monastir, Tunisia.

Results: Most patients were aged from 20 to 29 years (79.9%). Children less than 10 years and patients aged more than 40 years represented 7.3% and 5.5%, respectively. Men were more frequently affected (81.8%) than women (18.2%). Assaults were the most common aetiology in our series (36.4%) followed by falls (27.2%), road traffic (25.5%), sport (9.1%) and work accidents (1.8%). Mandibular Fractures were isolated in 78.2% of the cases. The parasymphysial region was mostly affected (48.8%). MBF were either unilateral (45.5%) or bilateral (20%). Association to other types of fractures were seen in 34.5%. Unilateral parasymphysial fracture was associated to condyle (28.6%), or ramus (23.8%) fracture. The fracture line was not displaced in 76.4% of the cases and displaced in 16.3% and 7.3% for unilateral and bilateral fractures, respectively. Maxillomandibular fixation was performed in 90.5% for a period of 4 to 6 weeks. Healing was obtained in 85.4% of the cases.

Conclusion: In our series, MBF were frequently seen in young male patients. Maxillomandibular fixation was the treatment of choice.

QUANTITATIVE ASSESSMENT OF STABILITY OF DENTAL IMPLANTS AND NATURAL TEETH

Westover, Lindsey*, Raboud, Don; Faulkner, Gary
University of Alberta, Edmonton, AB, Canada
Department of Mechanical Engineering
Edmonton, AB, Canada

Purpose: The ability to evaluate the stability (stiffness) of both dental implants and natural teeth is extremely useful in practice. In the case of dental implants, stability refers to the stiffness of the bone-implant interface, while for natural teeth stability refers to the stiffness of the periodontal ligament. An impact procedure has been developed which provides a quantitative assessment of stability that is applicable in both of these situations. Objective: The objective of this study is to evaluate the in vivo stability of dental implants and natural teeth and to provide a quantitative comparison of the stability measurements between these physiologically different cases.

Methods & Materials: The developed method uses an impact technique combined with a numerical model of the system to provide a quantitative measure of the stiffness at either the bone-implant interface or at the level of the periodontal ligament. The assessment procedure records an accelerometer signal measured during an impact with the tooth. The interpretation of this signal, which includes the numerical model, provides the measure of stability. For implants this allows the stability to be monitored from initial implantation through the healing phase and over the longer term to assess potential failure. In the case of natural teeth it can again be employed to measure the changes in stability that occurs over the course of orthodontic treatment. In this study, a comparison between the stability measurement for dental implants and for natural teeth is presented in terms of the difference in the measured accelerometer signals as well as the difference in the measured stiffness parameters.

Results & Conclusion: The results of this work show that the developed technique can provide a quantitative measure of interface stability that is applicable across a range of stiffness values including both dental implants and natural teeth. The developed method has the potential to provide a useful assessment tool that can be widely used in dental and orthodontic clinics, and can be used to monitor the progress or outcomes of reconstruction work associated with dental trauma.

Case Posters- Pediatrics and Orthodontics**REVASCULARIZATION OF TRAUMATIZED IMMATURE PERMANENT MAXILLARY INCISORS: A CASE REPORT**

Akbay Oba, Aylin*, Erkmen Almaz, Merve, Saroglu Sönmez, Isil
Kirikkale University Faculty of Dentistry, Adnan Menderes University Faculty of Dentistry
Pediatric Dentistry
Kirikkale, Turkey

Keywords: immature tooth, pulp revascularization, trauma

Purpose: In recent years, the concept of 'Pulp Revascularization' therapy has been developed, that attempts to obtain a longer and thicker root. The revascularization of immature permanent teeth following trauma could be beneficial to reduce the risk of fracture, because with a thin root dentin and large canal lumen, the tooth is prone to fracture. The purpose of this case report is to describe the revascularization treatment of two traumatized immature permanent maxillary central incisors.

Methods & Materials: A 9-year-old boy was referred to our clinic with extrusive luxation and crown fractures on the maxillary permanent central incisors. The radiographic examination showed immature roots in both incisors. The teeth were repositioned and splinting was performed for 2 weeks. After four weeks both teeth had pain to percussion and negative response to pulp test. Revascularization treatment with triantibiotic mix (including ciprofloxacin, metronidazole, minocycline) was administered for 2 weeks and then mineral trioxide aggregate was placed to the canals.

Results: After two years follow up, teeth were asymptomatic, there was radiographic evidence of proceeding root development with a positive response to the pulp test.

Conclusion: Considering the successful results, revascularization treatment could be effective for managing immature necrotic permanent teeth.

MANAGEMENT OF HORIZONTAL ROOT FRACTURE: A CASE REPORT

Akçay Özer, Sezin*, Aytepe, F. Zeynep
Istanbul University
Department of Pediatric Dentistry
Istanbul, Turkey

Keywords: horizontal root fracture, pedodontics, trauma

Purpose: The purpose of this case report is to demonstrate the maintenance of pulp health in a tooth with horizontal root fracture without any complications and endodontic treatment.

Methods & Materials: A 12-years-old boy with horizontal root fracture in the middle third of his upper incisor (11) was referred to the Department of Pedodontics, Istanbul University. Clinically the tooth showed mobility and a positive response to the pulp test. Splinting was performed and the child was observed under a regular follow-up regime.

Results: 12 months follow-up period the tooth was asymptomatic and showed a positive response to the pulp test. No pathological sign was observed radiographically.

Conclusion: The dental pulp is characterized by the ability to heal spontaneously in cases of root fracture. The vitality of the teeth with horizontal root fracture can be maintained without any endodontic treatment.

MANAGEMENT OF A TRAUMATIC INJURY WITH A REMOVABLE SPLINT

Akdemir, Yasemin*, Ölmez, Aysegül
Gazi University Faculty of Dentistry
Pediatric Dentistry
Ankara, Turkey

Keywords: Traumatic injury, avulsed tooth, removable splint

Purpose: Dislocation of teeth is a frequent finding following orofacial trauma. It has been estimated that three or four in 10 children sustain injuries to their primary teeth prior to school age. An important issue in trauma therapy is the splinting method used for stabilization of injured teeth to support periodontal healing. A large variety of fixation or stabilization techniques have been reported. In this case report, treatment of traumatic injury with using different types of splints will be explained.

Methods & Materials: 8-year-old boy approached to Department of Pediatric Dentistry with complaint of dislodgement of his tooth. He had fallen in the school garden 4 days before and his parents had admitted to a hospital that day. The first intervention was made there. In the intraoral examination, it was observed that the right permanent upper central incisor was avulsed and there was a composite roll splint between the left permanent upper central incisor and the left primary upper canine. In the radiographic examination the socket cavity of upper right central incisor, alveolar bone and upper left central incisor were healthy. The apex of upper left central incisor was open. Physiological root resorption in the primary upper left lateral incisor and a pathological root resorption in the primary upper left first molar was observed. Due to poor oral hygiene and instability of the composite roll splint, renewal of the splint was decided. Before removing the composite roll splint, dental impression was taken and the model was obtained. The removable splint was prepared. Then, the composite roll splint was removed and primary left lateral incisor and first primary molar were extracted. The patient was informed for using the removable splint during whole day and night and then was given an appointment after 1 week. At the 3-week follow up the stability of permanent left central incisor was obtained. Use of removable splint was terminated. Removable prosthesis was planned for the aesthetic, function and phonation. The patient was followed for 3 months, 6 months, 1 year and 3 year appointments.

Results: At the 1-year follow up the apex of upper left central incisor was closed and 3-year follow up the vitality of left upper central incisor was maintained.

Conclusion: According to this case report, it can be suggested that removable splint treatment may be a good alternative in this kind of traumatic cases.

MANAGEMENT OF ANTERIOR TOOTH LOSS IN A GROWING CHILD

Al-Bahlani, Suhaila*, Al-Jadidy L, Al-Lawatiy H, Hanna N
Ministry of Health, Oman Government
Paediatric Dentistry
Muscat, Oman, Oman

Purpose: Anterior tooth loss in children is very common and many factors contribute to it, the most common factor is dental trauma.

Methods & Materials: A 10 years old boy was referred to Paediatric dentistry department at Al-Nahdha hospital by the oral surgery department for management of teeth 11,12,21,22. Clinical examinations indicated the teeth 11,12,22 non vital. The second case is an 11-year-old boy who was referred by an orthodontist for management of tooth 11. On clinical examination the tooth 11 was badly broken, non vital and with poor prognosis.

Results: With the first case, radiographic and clinically examination revealed the teeth 11,21,22 non vital. In the subsequent visits teeth showed signs of ankylosis and replacement resorption. After consultation with an orthodontist, autotransplant of the impacted 15 and the horizontal impacted tooth 43 was carried out under general anesthesia and the tooth 15 was transplanted on 11 area, tooth 43 transplanted on the 21 area and decoration of the tooth 22. In the second case after clinical and radiographic examinations, the tooth 11 was found non restorable. After consultation with an orthodontist regarding premolar autotransplant, it was agreed to transplant the tooth 25 in 11 area. The treatment was carried out under general anesthesia and the tooth 25 was autotransplanted in 11 area and was restored in the subsequent visits to match the tooth 11. There was a follow-up period of 5 years for the first case, and 42 months for the second case.

Conclusion: In these case reports showed the long-term success of autotransplanted teeth.

ARE INTERNATIONAL ASSOCIATION OF DENTAL TRAUMA GUIDELINES REALLY INTERNATIONAL?

Al-Jaddir, Ghaida*, Barnard, Kate
Chelsea and Westminster NHS Foundation Trust
Department of Paediatric Dentistry
London SW10 9NH, United Kingdom

Purpose: Emphasise the importance of following International Association of Dental Traumatology Guidelines (IADT) internationally.

Methods & Materials: Three cases of mismanaged dental trauma in paediatric patients leading to unfavourable dental and psychological outcome. Information regarding emergency dental management from three different countries was collected. All three paediatric British patients sustained dental injuries during their summer holiday. They received emergency dental treatment in these destinations then sought further dental treatment at The Department of Paediatric Dentistry at Chelsea & Westminster NHS Foundation Trust. The first case is of an eight year old boy who avulsed his upper immature left central incisor. The tooth was re implanted after three hours stored in a tissue. The tooth was scrubbed clean and immediate root canal treatment was undertaken before re implantation. The tooth was rigidly splinted for eight weeks. The second case is of twelve year old girl who had intruded her upper right mature central incisor. Only 1mm of fractured incisal edge was visible. The patient was rushed to an emergency department where she was reassured, prescribed analgesia and advised to await re-eruption of the tooth. The patient did not seek dental treatment immediately after returning to London following the above advice. The third case is of an eleven year old boy who had both upper incisors avulsed. The emergency dental treatment was undertaken in a paediatric department at a dental school. Root canal treatment on both teeth was undertaken before re-implantation. Teeth were splinted for six weeks with a rigid wire and composite. All three patients and their parents were not warned about the potential loss of these teeth and subsequent need for their replacement. They were not advised to seek urgent treatment on their return to London. Radiographs were not taken in any of the cases but good documentation of the emergency treatment was available.

Results: The first case resulted in the tooth exfoliating as the splint was removed leaving a very distressed patient and parents. The second case of intrusive injury resulted in saving the tooth with orthodontic and endodontic treatment. This patient and her mother endured a stressful time (lengthy treatment, multiple visits, loss of income) and psychologically affected the patient's training and attendance at a dancing school. The third case resulted in the extraction of teeth and their replacement with an immediate upper removable denture.

Conclusion: Following IADT Guidelines will improve the prognosis of traumatised teeth. IADT guidelines should be encouraged to be an essential part of the teaching curriculum in dental schools internationally.

TRAUMATIC INTRUSION OF MAXILLARY PERMANENT INCISOR: A CASE REPORT

Arat Maden, Eda*, Özen, Bugra, Altun, Ceyhan
Gulhane Medical Academy
Pediatric Dentistry
Ankara, Turkey

Purpose: Intrusive luxation is a kind of traumatic injury characterized by an axial displacement of the tooth toward the alveolar bone. Its main causes are bicycle accidents, sports/recreational activities, and falls or collisions. Treatment strategies include waiting for the tooth to return to its position, immediate surgical repositioning, and repositioning through dental traction by orthodontic devices. In order to decide which treatment to follow, the degree of root formation, the patient's age, and intrusion severity should be taken into consideration. This study aimed to report a 9-year follow-up of a patient that suffered permanent incisor (PI) traumatic injury.

Methods & Materials: A healthy 9 year-old male was referred to Pediatric Dentistry Department with a complaint trauma to his left maxillary central incisor, following a bicycle accident occurred. Clinical and radiographic examination revealed intrusion of left maxillary central incisor. The treatment of choice was watch and wait to the tooth 21. After 12 months spontaneous eruption of tooth was detected. In the follow-up visit after 5 years, radiographic examination showed maintenance of pulp vitality, and absence of signs of periapical pathosis.

Results: The patient is on clinical and radiological follow up for maintenance of pulp vitality and periapical pathosis.

Conclusion: Regardless of the treatment strategy traumatically intruded teeth should undergo periodical clinical and radiographic surveillance on a long-term basis to allow early detection of possible complications.

INTERDISCIPLINARY MANAGEMENT OF AN UNERUPTED DILACERATED MAXILLARY CENTRAL INCISOR

Araz, Melis*, Ulug, Sermin Dicle, Guven, Yeliz, Cankaya, Burak, Gencay, Koray, Aktoren, Oya
Istanbul University
Paediatric Dentistry
Istanbul, Turkey

Purpose: Unerupted dilacerated incisors can be highly challenging for the clinicians. The objective of this case report is to present the interdisciplinary management of an unerupted dilacerated maxillary central incisor.

Methods & Materials: A 7-year-old girl was referred to Paediatric Dentistry Clinics of Istanbul University for the management of the clinical absence of maxillary right permanent central incisor. The dental history has revealed a dental trauma to maxillary deciduous incisors at age of 4. The intraoral radiographs exhibited that the maxillary right permanent central incisor was horizontally impacted due to dilaceration. Surgical repositioning and orthodontic treatment were planned to align the unerupted right maxillary central incisor. The dilacerated incisor was repositioned surgically. The orthodontic treatment was started after 6 month waiting period for the complete eruption of the right maxillary lateral incisor.

Results: The right central incisor was moved into alignment orthodontically in 9 months. The tooth has been asymptomatic and pulp testing showed a vital pulp at the 20-month follow-up.

Conclusion: The present case highlights the importance of early diagnosis and the interdisciplinary treatment approaches for unerupted permanent incisors with dilaceration.

CLINICAL AND RADIOGRAPHIC FOLLOW-UP OF A LATE-REPLANTED AVULSED IMMATURE INCISOR.

Ataol, Elif *, Turgut, Melek, Ileri, Tulin, Cehreli, Zafer
Hacettepe University Faculty of Dentistry
Department of Pediatric Dentistry
Ankara, Altindag, Turkey

Keywords: avulsion, trauma, replantation

Purpose: This case report describes the emergency intervention and follow-up of an avulsed immature central incisor with an extraoral dry time of 60 minutes and consequent milk storage of 15 minutes before replantation.

Methods & Materials: A 7-year-old boy was referred to the pediatric dentistry clinic 14 days after a bicycle accident. Reportedly, the tooth was stuck in volleyball net while passing under it with a bicycle on the schoolyard, and the tooth was found one hour after the accident. The avulsed tooth was immediately transferred into milk and the child was referred to a general dentist within 30 minutes. The clinician replanted and splinted the tooth, sutured the lacerations and prescribed medications with the recommendation of visiting a specialty clinic later. 14 days after the referral, the patient presented with the avulsed tooth, fixed with a rigid splint. Radiographically, the root had an open-apex and thin dentinal walls. The splint was removed, and the patient was scheduled for future recalls. 2 months after initial trauma, the tooth was injured again during fencing training. Following suturing of soft tissue lacerations, controls were maintained without splinting the tooth.

Results: Radiographic evidence of periradicular healing was observed 6 months after the avulsion injury. Clinically the tooth has uneventfully remained in function.

Conclusion: In "borderline" cases of late referral, replantation of avulsed immature teeth may be attempted, pending careful, long-term follow-up.

MANAGEMENT OF TRAUMATICALLY INTRUDED PERMANENT MAXILLARY CENTRAL INCISORS

Özmekek Atikler, Özge*, Sahin Ünsal, Gülcan, Ulukapi, Isin
Istanbul University
Pediatric Dentistry
Istanbul, Turkey

Purpose: The intrusion of teeth involves damage to the gingival tissues, periodontal ligament, cementum, bone and the neurovascular supply to the pulp. This report presents 3 cases of intrusive luxation injuries of maxillary immature permanent central incisors.

Methods & Materials: Three cases (7,8,8 year old boys) with intruded central incisors were referred Pediatric Dentistry Clinics of Istanbul University Faculty of Dentistry. In case one, both central incisors; 11, 21 were intruded. In case two and three 11 was intruded. In all cases intruded teeth were left for spontaneous re-eruption. The patients were reviewed at 2, 4, and 8 week intervals and every 3 months thereafter. At each recall visit, mobility, percussion, vitality tests and radiographic controls of the related tooth were carried out.

Results: All of the teeth re-erupted spontaneously in a 3-4 months. The root development continued and all pulps remained vital. During periodic follow-ups for up to 2 years the teeth did not show any clinical or radiographical problems and it was observed that teeth were fully re-erupted and are in functional alignment with other teeth. There were no other signs of pulpal and/or periapical pathology.

Conclusion: It can be concluded that intruded immature permanent teeth can spontaneously re-erupt, conserve their vitality, and continue their root development without any surgical or orthodontic management.

THE TREATMENT APPROACH TO THE HORIZONTAL ROOT FRACTURE

Avci, Serap*, Cantekin, Kenan; Aydinbelge, Mustafa
Erciyes Üniversitesi Dis Hekimligi Fakültesi
Pedodonti Anabilim Dalı
Kayseri, Turkey

Purpose: Horizontal root fractures usually are characterized by a fracture line that is perpendicular to the long axis of the tooth's root. The upper central incisors are most affected teeth by trauma. The purpose of this study was to report the case of an 11-year-old boy who experienced soft tissue injury and pain in his permanent maxillary central incisors following blunt trauma from a iron stick.

Methods & Materials: Eleven -year-old healthy male who was suffered from soft tissue injury and pain in maxillary central incisor referred to Erciyes University , Faculty of Dentistry , Department of Pediatric Dentistry two hours later the dental trauma. The maxillary right central incisor has been seen with a horizontal root fracture in radiographic examination. Then the fracture has been removed and the pulp tissue extirpated under the local anesthesia. The part has been waited in sterile serum physiologic solution. Extra oral root canal treatment has been made with MTA and the part has been gently replaced. Then wire splinted with acid etch composite resin attached to adjacent teeth for a period of 6 weeks.

Results: The patient has been followed up regularly at 1,3,6,12 th months. At 3 th month appointment external and internal resorption has been found in the radiographically. At one year follow up period we have decided to extract the tooth and prosthetic rehabilitation has been applied.

Conclusion: Horizontal root fractures are one of the most challenging cases for dental clinicians. In this case, we applied extraoral root canal treatment and unfortunately we could not reported successful findings.

REGENERATIVE ENDODONTIC THERAPY OF AN AVULSED, ROOT-FRACTURED, IMMATURE TOOTH

Ballikaya, Elif*, Cehreli, Zafer
Hacettepe University
Pedodontics
Ankara, Turkey

Keywords: avulsion, root fracture, regenerative endodontics

Purpose: This case report presents the short-term outcome of regenerative endodontic therapy in an avulsed, open-apex tooth with root fracture.

Methods & Materials: An 8-year-old patient was referred to the pediatric dentistry clinic 1 week after a fall accident. Reportedly, the tooth was found 3 minutes after an avulsion injury, and put into water. Upon consultation with a dentist, the tooth was transferred into milk 15 minutes after the water storage, and was replanted and splinted 2 hours later. The dentist referred the patient to a university clinic for further recalls. Radiographic and clinical examination revealed a fractured, open-apex, immature root and a bulky, rigid wire-and composite splint made by the dentist. The composite bulk was reduced to facilitate cleaning, and the patient was scheduled for controls. Three weeks later, the patient returned with severe spontaneous pain and swelling. Endodontic access was gained, and a triple antibiotic dressing was placed into the root canal after copious sodium hypochlorite irrigation. Four weeks later, the antibiotic paste was removed and regenerative treatment involving induced apical bleeding and an MTA coronal seal was performed. The original splint was removed 5 weeks later.

Results: Radiographic evidence of continued root development, apical closure and periradicular healing was observed during the 12-month follow-up. Clinically, the tooth had optimal gingival condition and physiologic mobility. The patient has been attending regular controls.

Conclusion: Over a 12-month follow-up period, the regenerative endodontic treatment provided radiographic healing and continued root development in the absence of symptoms.

SEVERE FRACTURE OF THE MAXILLARY ALVEOLAR PROCESS: A CASE REPORT

Barlak, Pelin*, Koruyucu, Mine, Çankaya, Burak, Seymen, Figen, Gençay, Koray
Istanbul University
Department of Pediatric Dentistry
Istanbul, Turkey

Keywords: Alveolar fracture, semi-rigid splint, children

Purpose: The aim of this report is to present a case of severe fracture of the maxillary anterior alveolar process with substantial bone dislodgement associated with teeth luxation and parasymphiseal mandibular fracture.

Methods & Materials: A 10-year-old boy with severe dentoalveolar trauma to the maxillary anterior region was referred to the clinic 2h after a fall accident. In clinic examination lingual hematoma was observed and on radiographic evaluation parasymphiseal unilateral mandibular fracture was detected but mandibular basal bone was not affected. Treatment consisted of fracture reduction of the maxillary alveolar process, repositioning of the teeth that had suffered extrusive luxation and placement of a semi-rigid splint. Soft diet was recommended to the patient.

Results: After 12 months of follow up, the fracture of the both alveolar processes were completely healed and the displaced teeth presented no signs of necrosis, ankylosis and root resorption. The traumatized teeth protected their pulpal vitality.

Conclusion: Cases of dentoalveolar trauma should be evaluated on an individual basis. In this case, a normal alveolar process was re-established by early intervention and transplantations, resulting in an optimal biological and satisfactory esthetic results. Early emergency management and adequate follow-up can prevent further complications and contribute to treatment success.

MANAGEMENT OF TWO COMPLICATED CROWN FRACTURES

Bayat, Ayse Derya*, Aydinbelge, Mustafa; Çetin, Seçil
Erciyes Üniversitesi Dis Hekimliği Fakültesi
Pedodonti Anabilim Dalı
Kayseri, Turkey

Keywords: trauma, fiber post, cvek pulpotomy

Purpose: This case report describes the rehabilitation of two traumatized mandibular incisor teeth.

Methods & Materials: A 10 years old male patient referred to our clinic, with crown fracture and severe pain. His parents reported that injury occurred 5 hour ago. At clinical and radiographic examination it was observed that two of mandibular anterior teeth has complicated crown fracture and lateral luxation. Central incisor tooth was restored by root canal treatment, fiber post core and strip crown. Lateral incisor was treated by Cvek Pulpotomy and composite restoration. Three month after the treatment, an acute apical apse observed at lateral incisor. And the tooth treated with root canal treatment. Routine follow up controls continues.

Results: Teeth were asymptomatic and in function at the 16 months follow up after the treatment. And there were no radiographic symptoms about periapical radiolucency or root resorption.

Conclusion: Traumatized teeth can be treated by root canal treatment, fiber post core, strip crown or cvek pulpotomy before final aesthetic restorations successfully. In some cases partial pulpotomy is not enough for success and it is necessary to do total pulpectomy. But long term follow-up is essential for dental trauma cases.

SEGMENTAL ALVEOLAR PROCESS FRACTURE: TREATMENT AND 12- MONTH FOLLOW UP

Bayram, Merve*, Barlak, Pelin; Koruyucu, Mine; Çankaya, Burak; Gençay, Koray; Seymen, Figen
Istanbul University, Faculty of Dentistry
Department of Pedodontics
Istanbul, Turkey

Keywords: alveolar process fracture¹, trauma², treatment²

Purpose: Alveolar process fractures are particularly complicated by the developing jaws, the presence of tooth germs and the eruption of permanent teeth. The aim of this report describes the management and 12-month follow up of a segmental mandibular alveolar process fracture.

Methods & Materials: A 8-year-old boy was referred to the clinic 1 day after falling down, which resulted in the fracture of the mandibular alveolar process with substantial dislodgement of the cortical bone. Emergency treatment consisted of fracture reduction in the dislodged bone and repositioning of the permanent incisors, followed by placement of a lower arch bar as a tension band including mandibular 1st primary molar and permanent incisors. The bar was removed at the end of 2 weeks, and the affected permanent incisors remained asymptomatic.

Results: Mobility was not present at the fracture site. At 12 months recovery was uneventful and occlusion was satisfactory and the patient had good masticatory efficiency.

Conclusion: Since the anatomical complexity of the developing mandible and teeth in cases of mandibular fractures of a young child, disruption of periosteal envelope may have unpredictable effects on growth. Thus, if intervention is required, closed reduction is favored.

THREE CASES REPORT MAXILLARY PERMANENT INCISORS WITH CROWN ROOT FRACTURED

Botsali, Murat Selim*, Gezgin, Onur; Kahraman, Kamil; Borbay Akgül, Sevil; Bag, Irem; Tosun, Gül & Yildirim, Sibel
Selcuk University, Faculty of Dentistry
Department of Pediatric Dentistry
Konya, Turkey

Purpose: A crown–root fracture is defined as a fracture involving enamel, dentin and cementum and may be classified as either complicated or uncomplicated according to the pulpal involvement. While crown fractures occur most frequently in the permanent dentition, crown–root fractures account for 5% of all traumatic injuries. The study included 3 patients, a female with crown root fracture and two male with complicated crown-root fracture in maxillary permanent incisors. The aim of this study is to present the treatment of a vertical complicated / uncomplicated crown–root fractures with reattachment of fractured maxillary incisors.

Methods & Materials: Coronal fragments were extracted atraumatically with flap operation. Follow-up flap operation, fracture fragments were bonded with dual cured resin composite (Panavia F®). After the healing of root periodontal tissues, canal treatments were done.

Results: After the healing of root periodontal tissues, canal treatments were done.

Conclusion: In cases of crown-root fractures, pulpal involvement plays a critical role in vital or devital of teeth.

RE-ERUPTION OF A SEVERELY INTRUDED IMMATURE PERMANENT INCISOR

Budanur, Damla*, Oztas, Evren; Sepet, Elif
University of Istanbul, Faculty of Dentistry
Department of Pedodontics
Istanbul, Turkey

Keywords: intruded incisor, removable appliance, re-eruption

Purpose: Traumatic tooth intrusion is a type of dental injury that involves displacement of the tooth into the alveolar socket. Intrusion injuries are more common in primary teeth but it also affect permanent teeth. This case report presents an interdisciplinary treatment approach to a severely intruded immature permanent incisor.

Methods & Materials: An 8-year-old boy was referred to Istanbul University, Department of Pediatric Dentistry for dental trauma as a result of fall at the school. He did not have any medical problem. Clinical and radiographic examinations revealed intrusion of immature right maxillary central incisor with a crown fracture and enamel-dentin fracture of left central incisor . Left central incisor was restored with composite resin. Right maxillary central incisor was restored with Biodentine material and composite resin, occlusal vertical dimension was increased and spontaneous eruption of the tooth waited for three weeks. Re-eruption was not satisfactory and in order to prevent ankylosis the eruption of right maxillary central incisor was forced with a removable appliance. Periodic follow-ups and radiographic controls were performed.

Results: Treatment options should be based on the stage of root development, severity of the trauma and individual factors

Conclusion: Intrusion is a severe type of dental trauma and the healing may be associated with various complications therefore proper management and long term evaluation is necessary in intrusion injuries.

THE ROLE OF BIOAGGREGATE IN PREVENTION OF INFLAMMATORY RESORPTION

Büyük, Cansu*, Akal, Nese
Gazi University, Faculty of Dentistry
Pediatric Dentistry
Ankara, Turkey

Keywords: Bioaggregate, root-end filling material, removable partial denture

Purpose: This case report aims to describe the prevention of inflammatory resorption by using bioaggregate as an end-filling material and demonstrate the use of the patient's tooth as a part of the removable denture.

Methods & Materials: An 8-year-old girl patient was referred to the Department of Pediatric Dentistry, Gazi University, Faculty of Dentistry with the complaint of fractured maxillary central incisors and mobile maxillary left lateral incisor because of a traffic accident. In clinical examination, a metal splint was observed on teeth (#53, #11, #21, #22, #63). The periapical radiograph showed the maxillary right and left central incisors with a normal socket, but maxillary left lateral incisor's position was not normal in the socket. The patient expressed that she was hospitalized for two days after the accident and then referred to a general dentist. Her avulsed maxillary left lateral incisor which was left in a dry cup for two days, was replanted and then she had a metal splint on her central incisors, left and right primary canin and late replanted left lateral incisor in that clinical. The metal splint was replaced with a semi rigid composite splint. After one week, the maxillary left lateral incisor was extracted because of over mobility and kept in saline and prepared for using as a part of a removable partial denture. And root canal treatments were carried out on maxillary central incisors with calcium hydroxide. After two weeks, semi rigid splint was removed and after five weeks, inflammatory resorption was seen on both of the maxillary incisors' roots. Three months after the replacement of calcium hydroxide in root canals, left maxillary central incisor had better prognosis, but the right one got worse. The right maxillary central incisor's apical thirds which had also resorption, decided to be plugged with Bioaggregate. Each root canal treatment was completed with AH Plus and Gutta-Perka. And the patient was introduced with the removable partial denture which her extracted left maxillary lateral incisor was a part of.

Results: She is still under the control for her central incisor and removable denture. At 15-month-followup, the teeth was symptom-free and the crowns and removable denture were aesthetically satisfactory.

Conclusion: In pediatric cases, traumatic injuries to the incisors are observed very frequently. And in these cases, it's essential to get treatment as soon as possible otherwise inflammatory root resorption which causes the loss of tooth may occur.

USE OF CYANOACRYLATES FOR EMERGENCY LIP SUTURING IN PEDIATRIC PATIENTS

Cardenas, DDS, MS, PhD, Lina*
San Antonio, TX, United States

Purpose: Lip laceration is a common clinical soft tissue injury in pediatric patients that sustain dental trauma. Behavior management can pose significant challenges in small children when an emergency sedation is contraindicated. Conventional lip suturing requires local anesthesia, making it difficult to provide integral emergency care in many patients that present for an emergency visit secondary to dental trauma. Although cyanoacrylates have been used commonly by dermatologists for the treatment of skin lacerations, their use is not widespread among the pediatric dentistry community. The purpose was twofold: 1) Present a literature review describing the differences between the available cyanoacrylates, their chemical structure, biocompatibility and physical properties. 2) Develop a clinical protocol for the use of cyanoacrylates as an alternative suturing method for lip lacerations supported by a case presentation.

Methods & Materials: A Medline search was performed and articles related to treatment of lip lacerations and use of cyanoacrylates as alternative to conventional suturing were reviewed. After applying inclusion and exclusion criteria, there were 7 research papers available for analysis. Additionally, 3 case reports were included. Advantages and disadvantages of each product were reviewed and discussed. A clinical protocol for the use of cyanoacrylates for the suturing of lip lacerations was developed and is introduced. A clinical case is presented, outlining the steps and clinical results during the emergency visit and at subsequent follow up in a patient.

Results: Advantages and disadvantages, as well as biocompatibility, were analyzed. Chemical structure seems to have a strong relationship to tissue irritation. A protocol for the use of cyanoacrylates as an alternative method to conventional suturing of lip lacerations was developed and supported by a case presentation. A 3-year old ASA 1 patient presented to the office after sustaining dental trauma. He was a pre-cooperative child with age appropriate cognitive abilities. The patient had history of difficulty coping with dental treatment. An assessment of his behavior rendered a Frankl 1 grading.

An in-office sedation was contraindicated because the patient had eaten 1-hour prior to the dental visit. Long term results are compared to those of conventional suturing.

Conclusion: Based on the review of the literature and the results on clinical cases, the use of cyanoacrylates is encouraged with appropriate case selection. Due to the scarcity of well-designed research studies, there is a myriad of opportunities for research in this area that will lead to sound data with clinical applicability.

REPAIR OF HORIZONTAL ROOT FRACTURE WITH MTA: 36 MONTH FOLLOW-UP

Cekmegeli, Ezgi*, Peker, Sertac; Kargul, Betul; Akyuz, Serap
Dental School of Marmara University
Pediatric Dentistry
Istanbul, Turkey

Purpose: Root fractures are uncommon injuries among dental traumas, comprising 0.5–7% of the cases and occur more frequently in fully erupted permanent teeth with closed apices. Fracture occurs most often in the middle-third of the root and rarely at the apical-third. The consequences can be complex because of combined damage to the pulp, dentine, cementum, bone, and periodontium. Management of horizontal root fractures depends on several factors, with the result that various clinical modalities have been suggested. This case report describes the treatment and 3-year follow-up of upper left central incisor with horizontal root fracture using mineral trioxide aggregate (MTA).

Methods & Materials: A 10-year-old boy with no general health problems was referred after suffering trauma to the Department of Pediatric Dentistry, Dental School of the Marmara University. Clinical examination revealed luxation of the upper left central incisor. Radiographic evaluation with different angulations revealed horizontal fractures in the middle third of his maxillary left central incisor. The initial treatment plan was slight reposition and non-rigid splinting (removed 4 weeks later) of maxillary left central incisor. 2 weeks later, root canal treatment was applied for the coronal part of the root. MTA (Pro-Root MTA, Dentsply Maillefer, Ballaigues Switzerland) was mixed according to manufacturer's instructions and coronal portion of the root was filled with MTA. After placing a sterile wet cotton pellet over MTA, the access cavity was sealed with glass ionomer cement (GIC). GIC and cotton pellet was removed after one week and the set of the MTA was gently tested. Coronal restoration was completed with a composite resin. Clinical and radiographic controls was done at 1, 3, 6 month and every year.

Results: The patient showed absence of any painful symptoms and tooth mobility returned to normal limits. Recall examination after 36 months revealed healing of the horizontal fractures. This case report shows a good long-term outcome when MTA was used in a horizontal root-fractured tooth.

Conclusion: MTA can be considered as an effective material for a definitive root filling material in horizontal tooth fractures with excellent biological and physical properties.

MTA PULPOTOMY IN TRAUMATIZED INCISOR TOOTH: 36 MONTH FOLLOW-UP

Çelik, Burcu Nihan*, Zeren, Ali Emre, Sari, Saziye
Ankara University
Pediatric Dentistry
Ankara, Turkey

Keywords: MTA, partial pulpotomy, trauma

Purpose: The aim of this case report was to present 36-month clinical and radiographical follow-up of an immature permanent central incisor with complicated crown fracture treated by partial pulpotomy with mineral trioxide aggregate (MTA).

Methods & Materials: An 8-year-old boy was referred to the Department of Pediatric Dentistry at the same day having fallen at school. Intra-oral examination revealed complicated crown fracture of the maxillary left central incisor. The tooth had no spontaneous pain, was not mobile or sensitive to percussion, and responded positively to electric pulp test. Radiographic examination indicated that there was no apparent periapical pathosis or alveolar bone fracture and the tooth was immature. These signs were associated with vital and healthy pulp response and partial pulpotomy was indicated. Pulp tissue was amputated 1-2 mm depth of exposed area and bleeding was controlled by flushing the wound surface with sterile saline solution. White MTA (ProRoot MTA; Dentsply Tulsa Dental, Tulsa, OK, USA) was applied according to the manufacturer's instructions. Final restoration was completed with glass ionomer cement (GIC) and composite resin. Tooth was examined clinically and radiographically at 6-months intervals over a follow-up period of 36-month.

Results: At the 36-month follow-up, tooth was clinically asymptomatic except grey discoloration of crown at third month. Radiographically, the apex of tooth was closed without any pathology, dentinal wall thickness was increased and a dentin bridge was clearly seen at the pulpotomy site. At 24th month an access cavity was prepared removing the entire restoration to initiate a bleaching procedure. It was seen that when all MTA material was removed, there was a favorable esthetical outcome for the color of tooth and the cavity was sealed again with GIC and composite resin without MTA. 36 month follow-up period the color of crown was stable.

Conclusion: Partial pulpotomy can be the treatment choice in complicated crown fractures on condition that exposure time/size and degree of root development were well evaluated. The objective of treatment is to maintain pulp vitality with well-sealed coronal restoration and continues root development. From this point of view MTA can be used in partial pulpotomy with its sealing ability, biocompatibility and induction ability for hard tissue formation. MTA has some disadvantages such as leading discoloration problems in anterior teeth. These disadvantages could be compensated by removing the entire material after the completion of dentin bridge and apical closure

MANAGEMENT OF CROWN FRACTURE WITH INDIRECT COMPOSITE VENEER AND FIBER-POST

Çetin, Seçil*, Aydınbelge, Mustafa
Erciyes Üniversitesi Dis Hekimliği Fakültesi
Pedodonti ABD.
Kayseri, Turkey

Keywords: trauma, indirect composite, fiber post

Purpose: The multiple teeth injury cases are common due to accidents. Tooth fracture may occur at any age because of trauma. According to Andreasen, most of the dental traumas in permanent teeth occur at period of 8-10 years old children. Studies have shown that some children and adolescents are affected only once with dental trauma, while others seem to be accident-prone and suffer from multiple dental trauma episodes. Less is known about treatment consequences related to repeated traumatic dental injuries to the same tooth and treatment guidelines are not well established. Aim: This case report describes the management of complicated crown fracture in maxillary first incisor of 11 year old child's in which had a second trauma on the same tooth.

Methods & Materials: 11-year-old male patient ho felt down the stairs and crashed his maxilla at school, applied to our clinic in need of treatment. The patient reported a second injury due to sports had occurred 1 month before(2 year later first trauma). At clinical examination, complicated crown fracture and subgingival caries under the fracture line observed. First of all, root canal treatment (retreatment) performed to the tooth and than restored with fiber post and composite core. After the knife-edge preparation, the tooth isolated. After gingival retraction, impression process completed with heavy body and light body. The plaster models obtained than trimmed and articulated for the indirect composite veneers. Than, a light-cured resin cement of the same shade is used for final cementation.

Results: At the 1-year follow-up, teeth were asymptomatic, in function, and have not shown any radiographic or clinical symptoms of pathology. The alternative treatment modalities of crown fractures are fragment reattachment, composite resin restoration and full crown coverage. Aesthetic and functional implications of tooth fracture depend upon its severity and age of the patient. Fracture and particularly dislodgment of tooth-colored restorations are the main causes of failure after the reconstruction of extensively damaged anterior teeth.

Conclusion: Fiber posts are considerable treatment choices with indirect composite veneers to provide a better retention of the restoration.

CONE-BEAM CT IN PEDIATRIC DENTISTRY - CASE REPORT

Corte-Real Gonçalves, Ana Teresa*, Caetano, Catarina; Amorim, José; Lopes, Maria-Das-Dores;
Figueiredo, José; Alves, Sónia
University of Coimbra
Dentistry
Coimbra, Coimbra, Portugal

Keywords: Cone Beam-CT, injury, slices

Purpose: A child who suffers a trauma is physically and emotionally debilitated. When the injury extends to the oral cavity and surrounding tissues radiographic registration is essential for the diagnosis and therapeutic success. In these situations, the lodging of a device between the two dental arches is a painful procedure.

Methods & Materials: We report a case of a 12 years old child who was hit by a four-wheeled vehicle, on her way to school. Coronal, sagittal and axial slices were registered by cone-beam computed tomography (CBCT) with iCAT equipment®(Pennsylvania, EUA). The software InVivo5® (Anatomage Inc, EUA) was used to visualize and analyze the tomographic slices and 3D reconstructions.

Results: Injuries of teeth, bone and surrounding structures were detected. The severity and extensions of these lesions allowed to define a rapid diagnosis and to guide therapy. From these lesions, we emphasize the existence of tooth fragments in the anterior region of both lips. It was also possible to measure the intrusion of a central incisor and to date its apexification to make the decision of doing orthodontic traction and repositioning of the occlusal plane.

Conclusion: Radiographic CBCT registration allowed to optimize the X-ray exposure in the diagnose of the traumatic injuries that resulted from the accident. This technique enabled to guide the treatment plan with greater safety compared to conventional examinations (panoramic and peri-apical radiographies) and to minimize exposure to ionizing radiation comparatively to conventional CT. The three-dimensional reconstruction of DICOM images facilitated the removal of tooth fragments once it allowed to accurately identify their location. Ultimately, radiographic registration with CBCT allowed to complement endodontic and orthodontic treatments, for the rapid aesthetic and functional recovery of the injured.

IMPLICATIONS OF TRAUMATIC EPISODES IN PRIMARY DENTITION: CASE REPORTS

Costa, Ana Luísa*, Ramos, João Carlos; Xavier, Maria Teresa; Vinagre, Alexandra
University of Coimbra
Department of Dentistry
Coimbra, Portugal, Portugal

Purpose: Oral trauma is assumed as a cause of increasing concern given both the high incidence and prevalence presented. The major concern when managing trauma in primary dentition is the potential damage to the permanent teeth. These reports seek to illustrate some clinical approaches of different sequelae of traumatic episodes in primary teeth that occurred in children's different development stages.

Methods & Materials: The clinical and radiographic analysis of traumatized children (7 to 13 years-old) with story trauma in primary anterior teeth revealed aesthetical defects, disturbances of position, crown and root development, hypoplasia and odontoma-like malformations. These pathologies were treated according to the type and extent of injuries, age, child's cooperation, dentition stage, risk of local complications and social constraint. Globally, the treatments performed included surgical ablation, orthodontic and aesthetic restorative techniques.

Results: Although the potential variability and complexity of clinical complications of these episodes in primary teeth, it can be performed by multidisciplinary approaches, as described, resulting the aesthetic and function required to the child.

Conclusion: Considering both the unfavourable functional and psychosocial consequences every effort should be done to provide a prompt and appropriate treatment based on a careful selection of materials and techniques that need to take into account several anatomic, biologic and physiologic principles in order to provide a safe, progressive and conservative treatment. The need for prolonged follow-up is moreover recognized and desirable.

ROOT RESORPTION DUE TO TRAUMA RELATED WITH MALFORMED ROOT FORMATION

Delikan, Ebru*, Aydinbelge, Mustafa; Dogan, Salih
Erciyes University
Pediatric Dentistry
Kayseri, Turkey

Keywords: trauma, external resorption, apical resection

Purpose: External resorption is reversible or irreversible progressive and destructive loss of tooth structure including bone, cementum, and dentine. It may occur as a consequence of trauma and may lead to inflammation. This inflammatory response can exacerbate after pulp necrosis. If it is allowed to progress, the resorption may lead to rapid tooth loss. This case report describes the management of an extreme apical root resorption of permanent maxillary incisor tooth with atypical root formation due to traumatic injury.

Methods & Materials: Ten years old male patient referred to our clinic with the severe pain mobility and recurrent swelling in the labio-gingival aspect of maxillary right central incisor. There was a history of traumatic injury 12 months ago. We have splinted the tooth and performed root- canal treatment than finished the treatment with composite restoration. After that apical curettage was performed. Patient called for follow- up appointments at 1st, 3rd, 6th, 12th months. A fistula recurred one year after the treatment. So re-treatment and apical resection was planned and applied.

Results: At the 19 months follow- up after treatment, tooth was asymptomatic, functional and the periapical radiograph showed regression in the size of periapical radiolucency with signs of osseous repair.

Conclusion: Early intervention is very important in trauma cases and affects the success of treatment. Delayed treatments may increase root resorption possibility. Long term follow-up is very important.

3D-VOLUMETRIC TOMOGRAPHY OF EXTERNAL RESORPTION AS A RESULT OF INTRUSION

Duman, Canan*, Tzifa, Vasiliki; Mentés, Ali
Marmara University
Paediatric Dentistry
Istanbul, Turkey

Purpose: Dentoalveolar trauma is a very common event in children. Intrusion is an apical displacement of the tooth into the alveolar, representing only the 0.3-2% of traumas affecting the permanent dentition and it is considered also one of the most severe form of dental injuries affecting the maxillary incisors. External inflammatory resorption and replacement resorption are complications that may result from traumatic luxation or avulsion followed by replantation of the tooth. Resorption may, ultimately, result in loss of the tooth.

Methods & Materials: This case report presents a 7- year-old female patient that was referred to Marmara University Faculty of Dentistry one day after a severe fall from her bicycle. The patient was provided first aid treatment in another hospital with dressing at the upper incisors' area for soft tissue's damage, stitches for the lower lip and systemic administration of antibiotics at same day. Intraoral examination showed a completely intruded upper left central and lateral permanent incisors and an avulsed primary canine. The radiographic evidence of open apices was present for both incisors. The central and lateral incisor were surgically repositioned and stabilized with a flexible splint for 3 weeks. Endodontic treatment was not chosen as an initial treatment plan, because of the capacity for healing of immature teeth. At second month, a severe external resorption was observed at the central incisor which was re-stabilized with right lateral incisor using a resin splint for 2 weeks. The left lateral incisor also exhibited a mild external resorption at the seventh month.

Results: At ninth month, a 3D volumetric tomography was taken to estimate more accurately the severity of the resorption. The apical 1/3, from the palatal and mesial root side, was resorbed. In the middle 1/3 only the mesial side was resorbed. Moreover, resorptive areas were seen at the cervical sides of the central incisor. But there was no mobility maybe due to the integrity of the distal part. Lateral incisor's middle part of the root had a mild resorptive area. Given these facts the plan was made to use the triple antibiotic paste and followed by complete endodontic treatment.

Conclusion: Intrusive luxations are serious injuries with high risk of complicated sequelae. It is important that treatment provision is evidence-based to ensure that the best possible dental outcomes are achieved.

TREATMENT OF A SEVERE DENTAL TRAUMA CASE: ONE YEAR FOLLOW-UP

Durmuslar, Cenk*, Demiriz, Levent
*Bulent Ecevit University
Oral and Maxillofacial Surgery
Zonguldak, Turkey

Purpose: The aim of this report is to present a severe dental trauma case which included all maxillary central incisors and it's multidisciplinary treatment.

Methods & Materials: A 9-year-old boy patient referred to our clinic with a complaint of tenderness and mobility in his maxillary central incisor teeth after an accident. In the clinical and radiographical examination, horizontal root fracture attended with dislocation of coronal fragment was detected in the right central incisor. In addition, complicated crown fracture was observed in the left central incisor. Treatment plan included the fixing and root canal treatments of all affected teeth. In the right central incisor coronal fragment was relocated and splinting application was completed with 0.3 mm orthodontic wire and composite resin. The pulp tissue was extirpated and calcium hydroxide paste was placed through the root canal of the left central incisor tooth. Because of the spontaneous healing chance of the horizontal root fracture, the right central incisor tooth was followed up clinical and radiographically in every week, however the spontaneous pain situation indicated to the root canal treatment of this tooth also. Splint was removed after 4 weeks, however calcium hydroxide dressings were continued to decrease the complaints for a month. Because of the open apex, root canal treatments in all teeth were completed with using Mineral Trioxide Aggregate (MTA) as an apical plug. The right central incisor tooth root canal was entirely filled with MTA. A fiber post was used in the left central incisor tooth crown to support the restoration structure. Crown restorations were completed with composite-resin. Periodical follow-up was done with clinical and radiographic examinations.

Results: At the end of 12 months, no clinical or radiographic signs of pathology were observed in all teeth. In addition, there was not any complaint stated by the patient about the functions of the teeth.

Conclusion: Although the one year results, further clinical and radiographical follow-up period was needed to be certain for being successful. Moreover, factors such as long term follow-up and cooperation of patients have an importance to provide a success in dental trauma cases.

A RADICULAR CYST OWING TO BOXING WITHOUT PROTECTION

Duygu, Nagehan*, Cinar C, Oztas N
Gazi University, Faculty of Dentistry
Department of Pediatric Dentistry
Ankara, Turkey

Keywords: Cone-Beam Computed Tomography, Mouthguard, Radicular Cyst

Purpose: Sport activities often increase the risk of traumatic injuries to dental and oral tissues. A number of sports carry a considerable risk of dental injury, not only in contact sports such as rugby, hockey and boxing, but also in less dangerous sports such as basketball. This case report describes a radicular cyst of maxillary region in an amateur boxer.

Methods & Materials: A 15-year-old boy was referred to Pediatric Dentistry Department of Gazi University with complaint of the presence of a inflammation in gingiva. In intraoral examination, although tooth decay was no observed, fistula was diagnosed in upper left lateral incisor. According to the history, patient who was non professional boxer, received repeated blows to the head without using a mouthguard. In panoramic radiography, in the upper left maxillary region had found a large radiolucent lesion. Due to conventional radiography failed to provide the requisite information for treatment planning, Cone-Beam Computed Tomography (CBCT) was used to determination of the location of lesion. CBCT showed lesion associated with upper right central incisor, lateral incisor, canine and first premolar. Root canal treatments were done these teeth. Treatment was done surgical enucleation of cyst and apical root resection of affected teeth with Mineral Trioxide Aggregate (MTA) and primary closure of the surgical area.

Results: At 3-year follow-up, clinical and radiographic success was noted.

Conclusion: This case emphasized the need for a mouthguard to be used even with amateur boxing. The dental practitioner should educate sportmen-patient of the risk of spor related dental trauma.

TREATMENT OF A COMPLICATED TRAUMA CASE WITH DAHL CONCEPT

Sakaryali, Didem*, Alacam, Alev
Gazi University, Faculty of Dentistry
Department of Paediatric Dentistry
Ankara, Turkey

Keywords: Complicated crown fracture, Crown root fracture, Dahl concept

Purpose: Vertical dimension is an important factor for satisfactory aesthetic and functional restorations. To increase the vertical distance temporary crowns, orthodontic treatment, extention of the length of crowns and Dahl concept can be applied.

Methods & Materials: This case report describes treatment procedures for a thirteen year old patient whom vertical dimension decreased after a traumatic injury. As a result of the clinical evaluation, complicated crown fracture on the right central incisor and mobility on the left central incisor was observed. In the radiological evaluation crown root fracture on the left central incisor had diagnosed. After extraction of fractured coronal part of the left central incisor, root canal treatment was initiated for both teeth. The following treatment was planned as fiber post and strip crown restoration. However, during endodontic treatment period, increased overbite was developed. For ideal aesthetic and functional restorations it is planned to increase the vertical dimension. In this case Dahl concept applied as an acrylic anterior bite plane to increase the interocclusal space for available restorations. After using Dahl appliance for 10 weeks, sufficient distance for fiber post and strip crown restorations was obtained and final restorations have done.

Results: The restorations evaluated clinically with modified USPHS criterias and seen that, there was no aesthetic and functional problems during three years follow-up.

Conclusion: The Dahl concept appears to be safe and avoids performing destructive restorative procedures on compromised teeth. Also, this concept is more easy than other methods which can use for increasing vertical dimension.

MULTIDISCIPLINARY MANAGEMENT OF A SEVERE COMPLICATED CROWN-ROOT FRACTURE

Erbas Unverdi, Gizem*, Cehreli, Zafer., Aktas, Alper.

Hacettepe University

Pedodontics

Ankara, Turkey

Keywords: crown-root fracture, fragment reattachment

Purpose: This case report presents the combined endodontic, surgical and restorative treatment approach for reattachment of coronal fragments in a case of complicated crown-root fracture involving two central incisors.

Methods & Materials: A 13-year-old boy was referred to the Pediatric Dentistry clinic with the complaint of severely fractured front teeth three days after a fall accident. Clinical examination of the affected central incisors revealed an oblique, buccal fracture line that extended below the gingival toward the palatal direction. In order to initiate endodontic treatment, the exposed pulp was removed with excavator under local anesthesia, and the fractured fragments were temporarily reattached to the teeth with etch-and-rinse adhesive and composite-resin. Then, endodontic access was gained, and a calcium hydroxide dressing was placed into the root canal. Two weeks later, the root canal was obturated with gutta-percha and sealer. In a separate appointment, buccal and palatal gingival flaps were raised to expose the fracture line. The coronal fragments were removed, and both adhesive reattachment and intracoronal reinforcement with custom fiber-reinforced composite(FRC) posts was performed under strict isolation conditions using sterilized rubber dam.

Results: The reattached teeth remained in function uneventfully for two years, after which the patient had a second fall accident and lost his left central incisor as a result of avulsion. A fixed, semi-rigid prosthetic appliance involving two molar bands, an archwire, and an acrylic tooth was fabricated to restore function and esthetics. The patient has been attending regular controls.

Conclusion: Reattachment of severely fractured crowns below the gingival level can be accomplished with the aid of strict isolation methods and internal/external adhesive reinforcement of fragments.

A BIG DILEMMA ABOUT DELAYED REPLANTATION: CASE REPORTS

Erken Güngör, Özge*, Karayilmaz, Hüseyin

Akdeniz University, Faculty of Dentistry

Pediatric Dentistry

Antalya, Turkey

Keywords: Avulsion, extended extraoral time, replantation.

Purpose: Tooth avulsion is a traumatic dental injury which results in dislocate of the tooth from the alveolar socket and accounts for 1-16 % of all dental traumatic injuries. Maxillary incisors are most commonly affected. The treatment choice is immediate replantation. However, factors such as lack of knowledge of the people about management of an avulsed tooth, unavailability of finding appropriate storage medium and bleeding due to soft tissue injury mask the loss of teeth. In this study, we have reported five cases of delayed reimplantation of avulsed teeth that occurred after prolonged times. Treatment success of delayed reimplanted teeth were evaluated clinically and radiographically.

Methods & Materials: Case Reports: The cases were selected between the patients that were applied to Akdeniz University Faculty of Dentistry Department of Pediatric Dentistry for traumatic dental injury. The information about age, gender, time and cause of the injury, number of affected teeth, the root maturation level (mature/immature), vitality of the affected teeth, condition of supporting tissues, extra-oral time of avulsed teeth, storage media, time of replantation, type and duration of splinting, and healing process was obtained from the patients' records. Avulsed teeth were reimplanted according to the guidelines for delayed reimplantation. Patients follow up are going on our clinic.

Results: The sample consisted of five traumatized children who had a total of five avulsed anterior permanent teeth.

The age of these patients ranged from 7 to 10 years. The most frequent causes were falls (n=4). A total of five permanent maxillary central incisor teeth were reimplanted. The avulsed teeth had been stored in dry condition until replantation. The teeth were replanted different times between 3 hours-a week. Endodontic therapy was completed extra-orally for two cases. The follow-up period was approximately 1 year. After clinical and radiographic evaluation, an inflammatory resorption was seen at one replanted tooth and replacement resorption was seen at two replanted teeth.

Conclusion: Immediate replantation of avulsed teeth are required for good prognosis, but it is not always possible. The replantation of maxillary incisors maintains growing of bone and soft tissues of alveolar process. Therefore some factors such as extra-oral period and type of storage medium of avulsed teeth should not be an obstacle for replantation. However, the dilemma continues about delayed replantation of avulsed teeth between practitioners.

AUTOTRANSPLANTATION COMBINED WITH ORTHODONTIC TREATMENT: 7-YEAR FOLLOW-UP

Ferreira, Manuel*, Ferreira, Hugo M; Botelho, Filomena; Carrilho, Eunice V P
Faculty of Medicine, University of Coimbra Portugal
Endodontics, Dentistry
Coimbra, Portugal

Purpose: Autotransplantation of the teeth has been a promising approach to replace missing teeth. However some undesirable prognosis is still remaining. This case report presents the treatment of a patient that suffer a traumatic injury at 9 years old, and after the ankylosed traumatized teeth were removed, autotransplantation of premolars was carried out to reconstruct their dentition in order to avoid dentoalveolar ankylosis and concerning aesthetics and function.

Methods & Materials: This case report presents the treatment of a patient 14 years old with an open bite, which have had a traumatic injury at 9 years old, with avulsion of the upper central incisor (21), that had been reimplanted and intrusion of the 21. At radiographic evaluation, pulpal canal obliteration (PCO), presence of inflammatory root resorption (IRR), and replacement root resorption (RR) are present. The treatment planning consisted of orthodontic treatment with premolars extraction. The lower premolars extracted were transplanted to the site of the upper incisors. The transplanted teeth were stabilized with silk suture that were removed 7 days after the transplantation. Orthodontic treatment was performed and clinical evaluation made through radiographic, percussion and mobility tests, during 7 years follow-up period. At radiographic evaluation, presence of periradicular area, inflammatory root resorption (IRR), replacement resorption (RR), lamina dura formation, outline of the periodontal membrane, and periapical pathology were registered.

Results: The transplanted teeth developed pulp necrosis after 6-8 months and root canal treatment was made. Within the 7 years follow-up period, none of transplanted teeth developed replacement resorption, ankylosis or periapical pathology. In this 7 years follow-up period, the survival rate was 100%, regarding aesthetics, function, clinical appearance, and radiographic image of alveolar process.

Conclusion: Autotransplantation of the teeth is a reliable approach to replace teeth lost due traumatic injury. This technique can be integrated into a multidisciplinary treatment, providing an alternative to dental implants in growing patients.

SEVEN CASES REPORT: EXTRUSION TREATMENT

Gezgin, Onur*, Bag, Irem; Borbay Akgul, Sevil; Kahraman, Kamil; Öner, Ela; Akman, Hayri; Botsali, Murat Selim & Tosun, Gul & Yildirim, Sibel
Selcuk University, Faculty of Dentistry
Department of Pediatric Dentistry
Konya, Turkey

Purpose: Extrusion is the partial displacement of the tooth out of its socket. Extrusive luxation of permanent teeth is one of the most serious injuries in dental traumatology. The frequency of extrusive had been found to be 7% among traumatized permanent teeth examined at a major trauma center. These teeth may undergo necrosis and inflammatory resorption and also if extrusion untreated, causes problems aesthetically. However, these conditions can be prevented with suitable treatment approaches. The aim of this study was to document the treatment outcomes of the 7 cases of extruded maxillary incisors (all central incisors, four of these teeth have mature apex, three of them have immature apex) in our clinic (Selcuk University, Faculty of Dentistry, Department of Pediatric Dentistry).

Methods & Materials: All of patients teeth has been extruded as a result of falling. In all cases the exposed root surface of the displaced tooth is cleaned with saline before repositioning. The extruded teeth were reposition in original position and splinted with semi-rigid splint material for two weeks.

Results: Because of all teeth lost their vitality and root-canal treatment was performed. These cases are followed.

Conclusion: A high rate of success can be obtained when extruded teeth has immature apex and apply to dental clinic as soon as possible.

TREATMENT OF OBLIQUE ROOT FRACTURE USING MTA: A CASE REPORT

Gokkaya, Berna*, Kalyoncu, Isil ; Kargul, Betul
Marmara University
Pediatric Dentistry
Istanbul, Turkey

Purpose: Despite the traumatic injuries of all ages, children and adolescents can be more often exposed to trauma and the upper incisor teeth most affected by it. Root fractures involve dentine, cementum, and the pulp. The healing process of horizontal fractures depends on different variables such as the age of the patient, the mobility of the coronal fragment, location of root fracture, and stage of root formation. The tissue types forming between the fragments during the healing process are as follows: healing with calcified tissue, interposition of connective tissue, interposition of bone and connective tissue, and interposition of granulation tissue. This case report describes the treatment and 2-year follow-up of tooth 11 with horizontal root fracture using mineral trioxide aggregate (MTA).

Methods & Materials: A 10-year-old boy with no general health problems was referred after suffering enamel- dentin fracture to the Department of Pediatric Dentistry, Dental School of the Marmara University. Clinical examination revealed no pain or sensitivity, no luxation of tooth 11. Radiographic evaluation revealed a oblique fractures in the apical third of his tooth 11. Electric vitality testing was performed and no sign of vitality was obtained. MTA (Pro-Root MTA, Dentsply Maillefer, Ballaigues Switzerland) was mixed according to manufacturer's instructions and was placed. The temporary filling material and paper point was removed after one week and the set of the MTA was gently tested. Coronal restoration was completed with a composite resin after one week.

Results: Clinical and radiographic controls were done at 1, 3, 6 month and 24 months. The healing of teeth was observed clinically and radiographically at 1st, 6th months follow-ups. The patient showed absence of any painful symptoms and the tooth had normal mobility. Radiographic controls revealed an unaltered status of connective tissue. Recall examination after 12 months, we observed that an oblique resorption at the apical portion of the tooth. The root length is reduced in the present case. An additional problem encountered in the present case was the insufficient apical plug formation of the central incisor which was consequently restored with MTA.

Conclusion: There are limited reports in the literature regarding the use of MTA in oblique root fractures. This case report showed a good long-term outcome when MTA was used in a root-fractured tooth. MTA can be considered as a good choice for a definitive root filling material in tooth fractures with excellent biological and physical properties.

CROWN FRACTURES OF PERMANENT MOLARS: A CASE OF INDIRECT TRAUMA

Gorcek, Hilal Merve*, Alacam, Alev; Bani, Mehmet
Gazi University Faculty of Dentistry
Department of Pediatric Dentistry
Ankara, Turkey

Keywords: indirect dental trauma, crown fracture, posterior trauma

Purpose: Although dental trauma prevalence to permanent anterior teeth is high, crown fractures at posterior region are seldomly observed. Indirect trauma sustained to the chin increases the risk of posterior teeth fractures.

Methods & Materials: This case report presents a 13-year-old boy who had uncomplicated crown fractures of maxillary permanent first molar 16, 26 and mandibular permanent first molars 36,46. Violent closure of the teeth was caused when the patient hit his chin on hard ground after a bicycle fall. The patient was referred to Gazi University Faculty of Dentistry, Pediatric Dentistry Clinic 7 months after trauma. The teeth were vital. All traumatized molars restored with composite resin restoration. The patient as referred to our clinic again because of missing restoration of maxillary left first molar after 2 weeks. Cvek pulpotomy and stainless steel crown was applied instead of composite resin restoration to the tooth.

Results: No negative findings were encountered in throughout 9 months of follow-up process.

Conclusion: This case indicates that a complete examination of all posterior teeth should be made considering the possibility of an indirect dental trauma.

ROOT RESORPTION OF AN AVULSED TOOTH AFTER TREATMENT: CASE REPORT

Gündüz, Gamze*, Aydinbelge, Mustafa
Erciyes University, Faculty of Dentistry
Pediatric Dentistry
Kayseri, Turkey

Purpose: Avulsion of permanent teeth is most serious of all dental injuries which maxillary incisors are most commonly involved. The success of reimplantation of an avulsed tooth depends on many factors as; elapsed time after avulsion, condition of the socket and the storage medium of the avulsed tooth. Other factors which may affect the success of reimplantation include the condition of the tooth, stage of root formation, type of cleansing procedure following contamination of the root surface, duration of splinting, and the use of antibiotics. Aim: In this case report, root resorption after stepwise treatment of an avulsed immature maxillary central incisor with extended period of dry storage and extrusive lateral incisor has been described.

Methods & Materials: 11-years-old healthy girl referred to the Erciyes University, Faculty of Dentistry, Department of Pediatric Dentistry with a complaint of missing permanent maxillary right central and lateral incisor and mobile left central incisor. The patient had reported more than three hours after the trauma with stored right central tooth in dry condition also could not find right lateral incisor. After the avulsed tooth was cleaned under running water to remove superficial debris on tooth surface, extraoral endodontic treatment was carried out on the tooth. The empty socket was debrided and thoroughly irrigated with normal saline solution before reimplanting. The lateral incisor tooth was then repositioned and teeth were splinted with composite and 0.4 mm hard stainless steel wire with support provided by adjacent teeth for a period of two weeks. A radiograph was taken to check the proper placement of the avulsed tooth. The patient was prescribed antibiotics and reviewed after two weeks.

Results: Clinical and radiographic examinations at one and three months recalls revealed a immobile tooth without any evidence of periapical pathology. But replacement root resorption observed at radiographs six months after reimplantation. However, the tooth was not mobile and there was not sensitivity at percussion.

Conclusion: Conclusion: Most conservative approach for managing the avulsed teeth is to replace them as soon as possible. Replacement root resorption is a common cause to lose affected teeth. But the tooth can be left in the mouth for a while under follow-up.

MULTIDISCIPLINARY TREATMENT APPROACH OF INTRUDED TEETH WITH CROWN FRACTURES

Güven Polat, Günseli*, Acar, Ozge; Akgun, Ozlem Marti; Yildirim, Ceren
Gulhane Medical Academy
Department of Pediatric Dentistry
Ankara, Turkey

Purpose: This case report describes clinical management of intruded maxillary central incisors with crown fractures.

Methods & Materials: A 14-year old male was referred to Pediatric Dentistry Department because of intrusion and crown fractures of both maxillary central incisors as a result of a bicycle accident 1 month before. The patient was asymptomatic, had no known allergies or systemic problems, and extraoral examination revealed no significant abnormalities. On clinical examination, labial sinus tract that traced to the apex of the right maxillary central incisor determined. His right and left permanent maxillary incisor teeth intruded and had crown fractures. A periapical radiograph showed the right and left maxillary central incisor had large radiolucencies. Parents were given detailed information about the treatment program, and their informed consent was obtained. Endodontic therapy was applied to maxillary central incisors. The root canals were irrigated with 2.5% NaOCl, dried with paper points and filled with a ciprofloxacin/ metronidazole/minocycline paste, as described by Hoshino et al. The access cavities were closed with glass ionomer cement. The patient was canalized to department of orthodontics for orthodontic extrusion of the teeth. Intracanal dressing was changed once a month for 6 months until periapical radiolucencies resolved. At the 6-month recall, the patient was asymptomatic, with no signs of the sinus tract. Conventional endodontic treatment was performed with guttapercha using the vertical condensation technique. The patient was followed-up for 1, 3 and 6 months postoperatively. Six months later, the teeth were restored with composite resin.

Results: At 1 year follow-up examination there were no periapical pathologies associated with the maxillary incisors.

Conclusion: The management of traumatically intruded permanent incisors is controversial. In this case orthodontic extrusion is preferred because it is more conservative and physiologic than surgical extrusion. Disinfection is achieved by irrigation followed by the placement of an intracanal medicament. A mixture of ciprofloxacin, metronidazole, and minocycline has been shown to be very effective in eliminating endodontic pathogens in vitro and in vivo. In present case triple antibiotic paste was used for disinfection of root canals.

DIFFERENT TREATMENT APPROACHES IN LATERAL LUXATION INJURIES: TWO CASE REPORTS

Guven, Yeliz*, Ulug, Dicle, Aktoren, Oya
Istanbul University
Department of Pediatric Dentistry
Istanbul, Turkey

Keywords: Dental Trauma, Lateral luxation

Purpose: Lateral luxation, the displacement of the tooth in a palatal or labial direction, is one of the most prevalent dental injuries among the general population. The purpose of this case report is to describe the management of two cases with palatally displaced incisors due to a lateral luxation injury.

Methods & Materials: The first case was a healthy 7-year-old boy who was referred to the clinics of Istanbul University, Faculty of Dentistry with a history of falling. Extraoral examination revealed abrasions, contusions, small lacerations on the facial skin and upper lips. Intraoral examination showed that right upper central incisor was displaced in palatal direction. A slight extrusion was also noted. The injured tooth was mobile and gave a negative response on pulp vitality tests. Radiographic examinations showed that right upper central incisor had a wide open apex and had no fractures on the root. The second case, an 8-year-old boy with Type 1 Diabetes Mellitus, was also referred to our clinics after a fall injury occurred 1 h earlier. Extraoral examination revealed abrasions on the skin of lower jaw region. Intraoral examination showed that lower central incisors were displaced in the palatal direction. The injured teeth were mobile and gave a positive response to pulp vitality tests. Radiographic examinations showed that lower central incisors had an open apex and no evidence of root fractures. Injured tooth of first case was unable to be repositioned by digital pressure. The tooth was stabilized and repositioned orthodontically. The treatment plan for the second case consisted of repositioning the injured teeth by digital pressure under local anesthesia. The teeth were then splinted to the adjacent laterals with composite resin and a flexible wire.

Results: The injured tooth of the first case was repositioned orthodontically into its proper place in the dental arch in 1 month. In the second case, the luxated teeth were repositioned on the same day by digital pressure. Affected teeth in both cases have been asymptomatic and pulp testing showed a vital pulp at 1-year follow-up.

Conclusion: Management and follow-up evaluation of the lateral luxation injuries are of importance considering the risk of further pulp necrosis. Therefore, the affected tooth should be monitored until a definitive pulp diagnosis can be obtained.

HORIZONTAL ROOT FRACTURES IN MAXILLARY CENTRAL INCISORS: 2 CASE REPORTS

Hatipoglu, Zeliha*, Akal Nese, Didinen Serhan
Gazi University, Faculty of Dentistry
Pediatric Dentistry
Ankara, Turkey

Keywords: horizontal root fracture, fracture line, trauma

Purpose: Root fractures in permanent teeth are uncommon injuries and represent complex healing patterns. Fractures occur most often in the middle third of a root and rarely at the apical third. The aim of these 2 case reports are to introduce the treatment of horizontal root fractures in 3 maxillary central incisors.

Methods & Materials: Case 1: 10 year-old patient was referred with complaint about his tooth fracture and sensibility after trauma to the anterior maxilla. Radiographic evaluation revealed horizontal fracture in the apical third of his maxillary right central incisor. Clinical evaluation exhibited grade two mobility of the coronal segment. The coronal segment was repositioned and stabilized by splinting to the neighboring teeth with orthodontic wire. After a week at first appointment pain, sensitivity to apical palpation and percussion were evident at the central incisor, and a decision was made to start endodontic therapy on this tooth. The splint was maintained in position for four weeks. Root canal treatment was finished until fracture line and tooth part in the apex was left such that position. 6 months in the control we noticed that the tooth color was changed. Discoloured maxillary right central incisor was treated with walking bleaching technique using %37 carbamide peroxide. Case 2: 10 year-old patient hit his two maxillary central incisors because of falling. He went a dental clinic for emergency treatment immediately after the trauma. They splinted the teeth with orthodontic wire and directed the patient to the Gazi University, Faculty of Dentistry, Department of Pediatric Dentistry. In our first examination 2 weeks after the trauma, it is diagnosed that 2 horizontal root fractures in central incisors and it was decided to remain the splint for 2 weeks more. At this control, it is diagnosed that maxillary left central incisor exhibited increased radiolucent area between the fragments. The root canal treatment was finished at the root apex.

Results: According to the 22 months in case 1 and 36 months in case 2 radiographic and clinical follow-ups, the teeth were asymptomatic with no discoloration and esthetic was maintained during this time.

Conclusion: Treatment of root fractures depends on a number of factors such as, position of fracture line, mobility of tooth and pulpal status. Both endodontically adequately treated teeth until root fracture and at the root apex have a good prognosis.

TRAUMATIC INJURIES DUE TO NATAL TEETH: REPORT OF THREE CASES

Haznedaroglu, Eda*, Duman, Canan; Mentés, Ali
Marmara University
Pediatric Dentistry
Istanbul, Turkey

Keywords: natal, neonatal teeth

Purpose: The purpose of this report is to point the possible complications related to natal and/or neonatal teeth and discuss their treatment. This report presents treatments and follow-ups of three cases with natal and neonatal teeth causing injuries to several oral tissues of the babies.

Methods & Materials: Case 1 was a 7-day old boy who was referred to our Department of Paediatric Dentistry, Marmara University with an anamnesis of an exfoliated tooth on mandibular anterior area. We thought it could be swallowed and fortunately it was not aspirated. Case 2 was a 3-day old boy referred to our department with natal tooth as lower incisor and in three weeks neonatal tooth was erupted in the same patient. Laceration of the mother's breasts and excessively luxation were detected. Because of these, natal and neonatal tooth were extracted with topical anesthesia. Case 3 was 5-day old boy referred to our department with natal tooth. Sublingual ulceration (Riga-Fede disease) and severe luxation were detected. Natal tooth were extracted with topical anesthesia to prevent baby from traumatic ulceration of sublingual area and more serious complications like aspiration of tooth.

Results: In case number 1, in nine months follow-up we observed incisors eruption at third and eighth months. On the other hand, in case number 2 and 3 in two years follow-up primary incisors were not erupted. In all cases the x-ray was not taken because of the age of the patients.

Conclusion: Most commonly involved natal and neonatal teeth are lower incisors. Nursing problem is the most common complaint from the mother. Periodic follow-up by pediatric dentist to provide preventive oral health care. And more studies are necessary to confirm the etiology, nature of natal/neonatal teeth and if they are deciduous or supernumerary teeth.

INTERDISCIPLINARY TREATMENT OF MISSING LEFT CENTRAL INCISOR DUE TO TRAUMA.

Hepdarcan, Sedef*, Acar, Abidin**, Tozlu, Murat*, Ulkur, Feyza*
*Yeditepe University, Faculty of Dentistry
Department of Orthodontics **Private Practice
Istanbul, Turkey

Purpose: This case report illustrates the interdisciplinary treatment for missing upper left central incisor -due to dental trauma- by means of orthodontic treatment and aesthetic dentistry approach.

Methods & Materials: A 17- year-old male patient was referred to our clinic with the chief complaint of the missing upper central incisor tooth. In dental history the patient mentioned about a traumatic accident which he had lost his left maxillary central incisor. At the time of the accident the tooth avulsed and it was not found. In the patient's intra and extra-oral examination a convex profile, circum-oral musculature strain on lip closure, moderate crowding and dental class II on both sides were observed. In the lateral cephalometric tracing the patient had skeletal Class II malocclusion with increased vertical facial dimension. As the treatment protocol the extraction of the right central incisor on the upper jaw and the lower first premolars on both sides were decided to achieve esthetic and functional objectives. The extractions were done with the approval of the parents. The orthodontic treatment took 21 months. After closing the extraction spaces with orthodontic treatment, periodontal and cosmetic procedures were performed to improve the patient's smile.

Results: The post-treatment and follow-up records were compatible.

Conclusion: The treatment was finalized in a good profile with stable occlusion. The patient was satisfied about his smile characteristics.

MANAGEMENT OF COMPLEX DENTOALVEOLAR TRAUMA IN A PEDIATRIC PATIENT

Hershkowitz, Evan*, Cho,Hyunbae, Hock, Christopher
Lincoln Medical Center Bronx, NY
Dentistry and Oral Maxillofacial Sugery
Bronx, NY, United States

Purpose: To show how timely management of severe pediatric dentoalveolar trauma resulting from blunt force trauma can result in a successful outcome by utilizing a multidisciplinary and multifaceted approach.

Methods & Materials: This case report shows a successful treatment of an 8 year old pediatric patient who had dental avulsion, intrusion, subluxation, and obliteration of the maxillary anterior buccal plate status post motor vehicle accident. Pre-operative diagnosis was confirmed using facial bone CT scans without contrast, as well as panoramic films. The radiographic exam revealed numerous buccal plate fractures, anterior and apical displacement of tooth #8, and complete intrusion of tooth #9, in close proximity to the floor of the maxillary sinus. Within 24 hours of the incident the patient was taken to the operating room for surgical exposure and retrieval of #9, as well as repositioning and stabilization of the entire maxillary segment.

Results: 24 hour, 1 month, and 2 month post-operative follow up was performed on patient with subsequent radiographs and clinical exams ,which revealed that teeth #8 and #9 are well reduced and repositioned back in to their proper original arch form. Patient also exhibited significant bone development in the affected segment and a stable and reproducible occlusion. Furthermore, severely luxated and intruded teeth #8, #9, and #10 have maintained vitality with continuous root development and proper closure of apex without any evidence of pulpal degeneration.

Conclusion: In conclusion, this case report shows how severely traumatized teeth and dentoalveolar fractures can be successfully managed when timely intervention, and proper clinical techniques are utilized.

MANAGEMENT OF ANTERIOR TOOTH ROOT FRACTURE: A CASE REPORT

Inan, Gizem*, Bozkaya,Süleyman , Odabas, Mesut Enes
Gazi University Faculty of Dentistry
Department of Pediatric Dentistry
Ankara, Turkey

Keywords: trauma, root fracture, apical resection

Purpose: Root fractures could be defined as fractures involving dentin, cementum and pulp. Root fractures are relatively uncommon among dental trauma patients, comprising 0.5-7 % of all injuries affecting permanent dentition . Root fractures occur mainly in upper central teeth (68%) and upper laterals (27%).Treatment approach for these fractures could be complex due to the prognostic considerations such as patient's age, stage of root growth,mobility of the coronal fragment, and diastasis of the fragments.

Methods & Materials: A 12-year-old boy was referred to the Department of Pediatric Dentistry, University of Gazi, just after a trauma to his maxillary anterior teeth. Radiographic examination showed a horizontal fracture in the middle third of tooth #11 and a diastasis greater than 1 mm was estimated in the fracture line. Semi-rigid splint was applied and endodontic treatment of tooth was initiated. The canal was prepared and irrigation was applied with 2% sodium hypochloride. Calcium hydroxide was applied and cavity was filled with Cavit (3M). Next visit, conventional root treatment was performed and canal was filled with a canal paste (AH Plus) and gutta percha(Pearl Endo). After one month, a fistula appeared at the vestibule mucosa of #11. The tooth was retreated and apical fragment together with granulation tissue had been removed. After root resection, retro cavite was prepared and filled with mineral trioxide aggregate. Because of the esthetic requirements of patient, splint was removed and tooth was restored with composite-resin. The mobility of tooth still existed because of shortened root. For this reason, the splint was applied to palatal surfaces of #11 and #21 teeth. After 7 months, splint was removed and tooth mobility returned to normal limits.

Results: No negative findings were encountered in throughout 2 years of follow-up process.

Conclusion: This case report describes the combination of root canal treatment and apical resection of complicated crown and root fractures of maxillary central incisor.

HEALING AFTER HORIZONTAL ROOT FRACTURE: A 9-YEAR FOLLOW-UP

Jeong, Yeonwook*, Lee, Hyoseol, Lee, Jae-Ho, Son, Heung-Kyu, Choi, Hyung-Jun
College of Dentistry, Yonsei University, Seoul, Korea
Department of Pediatric Dentistry
Seoul, Korea (South)

Purpose: Root fracture of permanent teeth is a relatively rare form of dental injuries and its occurrence has been reported to be 0.5 to 7% of cases. It occurs most commonly in the 11 to 20-year age group. Also, it most often occurs in the maxillary central incisors of male patients and is frequently seen in the middle third of the root followed by apical and coronal third fractures. The treatment strategy of root fracture depends on the position of the fracture, the degree of displacement of fractured fragment, patient's age, stage of root development, mobility of the coronal fragment and diastasis of the fragments.

Methods & Materials: A 10-year-old boy visited department of Pediatric dentistry of Yonsei University dental hospital for the treatment of a root fractured maxillary incisor the day after his injury. The patient visited other dental clinic the day before and he came in with a composite resin-orthodontic wire splint on his anterior teeth. Clinical and radiographic examination revealed that there was an incomplete horizontal root fracture on the maxillary left incisor in the middle third of the root. Splinting was carried out for 8 weeks. During the follow-up period, 2 years after the first trauma, the additional injury to his anterior tooth occurred unfortunately. The maxillary left incisor showed complete horizontal root fracture and the coronal fragment had excessive mobility. The anterior teeth were splinted again for 8 weeks. As the coronal fragment was considered to be necrotic and the apical segment remained vital, endodontic treatment of the coronal fragment was done with vitapex.

Results: The recall check-up was done annually for 9 years after the first trauma and the union of fragments with calcified tissue was observed without abnormal symptoms.

Conclusion: Pulp necrosis in root-fractured teeth is attributed to displacement of the coronal fragment and mature root development. Root fracture healing events can range from healing with calcified tissue, healing with connective tissue, healing with bone tissue, and interposition of granulation tissue without healing. Different types of healing may depend on the proximity, repositioning and the fixation of the fragments and the absence of infection. In this case, as the coronal fragment of the maxillary left incisor was considered necrotic after the second injury, we performed endodontic treatment on the coronal fragment only. 2 years after the second trauma, successful union of fragments with calcified tissue was observed and the patient showed no abnormal symptoms during 9 years follow-up.

SURGICAL LUXATION OF ANKYLOSIS TEETH: A 7-YEAR FOLLOW UP

Joo, Kihoon*, Je-Seon Song, Seong-Oh Kim, Byung-Jai Choi, Hyung-Jun Choi
Dental Hospital, Yonsei University
Pediatric Dentistry
Seoul, Korea (South)

Purpose: Ankylosis occurs most commonly following severe luxation injuries like avulsion or intrusion in which periodontal ligament (PDL) cells are destroyed. Especially in young patients, these incisors result in infraocclusion during adolescent growth. Surgical luxation of ankylosed teeth aimed to break the ankylosis has been used with considerably high rate success. This technique assumes that with a sufficient movement of the ankylosed tooth to disrupt the area of ankylosis but maintaining periapical blood supply, the subsequent inflammatory reaction could result in formation of a new fibrous ligament in the area of ankylosis.

Methods & Materials: A 7 years old patient visited dental clinic for tooth fracture of her incisors. Class II crown fracture of bilateral maxillary central incisors were found and restored by composite resin. After 8 months of trauma, different incisal levels between maxillary right central incisor (#11) and maxillary left central incisor (#21) were found and definite infraocclusion of #21 was observed at 15 months follow up. To avoid alveolar bone recession of #21 area during growth peak, coronectomy treatment in 2-3 years was planned. At the age of 10, surgical luxation was treated under parental agreement before coronectomy.

Results: Gradual eruption was found after 6 months of surgical luxation and clinical incisal level of the two teeth were approximately equal by 1 year post surgery. During follow up period, clinical signs of the tooth were in normal range until at age 14. The patient is scheduled for continuous follow-up.

Conclusion: This case report contains an ankylosis of maxillary left central incisor after trauma and successful re-eruption after surgical luxation, one of the treatment options which could be applied conservatively before coronectomy. Surgical luxation of ankylosis should be performed under thorough case selection and possible complications (re-ankylosis, alveolar bone and/or root resorption, etc.) should be notified to patient. After treatment, long-term periodic follow up including radiographic and clinical exam is required for early detection of the possible complications.

DESTINY OF AVULSIONS: THE GOOD, THE BAD AND THE UGLY

Kahraman, Kamil*, Borbay Akgul, Sevil; Bag, Irem; Gezgin, Onur; Osman, Fatma Bahar; Botsali, Murat Silem & Tosun, Gul & Yildirim, Sibel
Selcuk University, Faculty of Dentistry
Department of Pediatric Dentistry
Konya, Turkey

Purpose: Avulsion is described as the total displacement of the tooth out of its socket. Avulsion of permanent teeth is one of the most serious dental injuries, and a prompt and correct emergency management is very important for the prognosis. The aim of this study was to document the treatment outcomes of the replantation of 10 cases of avulsion in our clinic (Selcuk University, Faculty of Dentistry, Department of Pedodontics).

Methods & Materials: The study sample was created by using patient records from the last three years (2010-2013). The information about age, gender, time and cause of the injury, number of affected teeth, the root maturation level (mature/immature), vitality of the affected teeth, condition of supporting tissues, extra-oral time of avulsed teeth, storage media, time of replantation, type and duration of splinting, and healing process was collected and categorized from the records. The age of these patients ranged from 7 to 13 and the sample consisted of 10 traumatized children who had a total of 14 avulsed anterior permanent teeth. Five of them were stored in milk, other four were not stored in any media (dry). Five of the patients were applied to our clinic by their avulsed teeth were replanted before referral.

Results: A high rate of success can be obtained when the avulsed teeth are kept under wet conditions and brought to a dental clinic as soon as possible. On the other hand, if the avulsed teeth are stored in any media (dry) or brought to a dental clinic lately, replacement root resorption is observed. In our cases, the avulsed teeth which were stored in dry conditions and brought lately were showed replacement root resorption. Only one case which was brought in milk showed best healing result.

Conclusion: Conclusively, when avulsed teeth carried in an appropriate environment, the outcome of the routine avulsion treatments were satisfactory. Therefore such injuries should be recognised and treated expeditiously.

REPLANTATION OF UPPER LATERAL FOR AVULSED CENTRAL INCISOR: CASE REPORT

Kalyoncu, Isil Ozgul*, Kitiki, Burak Mentesh, Ali Tanboga, Ilknur
Marmara University
Pediatric Dentistry
Istanbul, Turkey

Purpose: Avulsion of permanent teeth is most serious of all dental injuries and accounts for 1-16% of all traumatic injuries, of which maxillary incisors are most commonly involved. Replantation of the avulsed tooth is considered the best aesthetic and functional solution. However, the decision to replant the teeth depends on several factors: periodontal damage, intact alveolar socket, extra-alveolar period, supporting teeth for dental splint and stage of root development. This case report presents the treatment of an avulsed central incisor by replantation of lateral incisor with lateral luxation.

Methods & Materials: In June 2012 a healthy 10 year-old boy was referred to the the Marmara University, Department of Pediatric Dentistry after a severe trauma to his upper front jaw. The clinical and radiological examinations revealed that there was gingival lacerations, avulsed upper right central incisor, blood clot in the alveolar socket of central incisor and the upper right lateral incisor was suffered from lateral luxation. The avulsed tooth has not been found after the accident. Also upper right primary canine had luxation. At the same session lateral incisor with the displacement was surgically removed and immediately replanted to the bone socket of the avulsed central incisor under local anesthesia. The reason for replantation was the lack of supporting teeth for splint at that side. Orthodontic splint was applied to the left lateral, central incisor and replanted right lateral incisor. One week later endodontic treatment was initiated before splint was removed. After a 4 week period, the splint was removed, the root canal treatment was finished and than tooth was restored by composite restorative material.

Results: The patient has been followed at the 3-month, 6-month,12-month. According to clinical and radiologic examinations the tooth was asymptomatic. For the final prosthetic restorations we are waiting eruption of the upper right permanent canine.

Conclusion: In trauma cases a pediatric dentist should always consider different treatment options for better result.

ROOT FRACTURES IN PERMANENT TEETH: CASE SERIES

Karahmetli, Ece*, Vural Simge, Özer Levent
University of Ankara
Department of Pediatric Dentistry
Ankara, Turkey

Keywords: trauma, root fracture, mta

Purpose: The aim of this case report was to present 9 month clinical and radiographical follow-up of four permanent central incisors with root fracture treated by root canal treatment with white mineral trioxide aggregate (MTA) or gutta percha.

Methods & Materials: Four children ages between 8-11, who had trauma before at least 1 day, were referred to our clinic. One of these cases had superficial root fracture, the other teeth fracture lines were not superficial. Except that case, other cases had treated with endodontic treatment down to fracture line. We made complete root canal treatment to the case who has superficial root fracture to maintain root-crown stability. And filled with gutta percha points. In other cases MTA was used as a apical barrier of coronal fragment and filled with gutta percha. All teeth were splinted for 1 month. Teeth were examined 1-3-6-9 months intervals.

Results: At the 9 month follow-up, teeth were clinically asymptomatic and no periapical radiolucency or abscess formation has seen till 9 month.

Conclusion: Root fractures are not seen frequently but tooth loss, periapical radiolucency and abscess formation could be seen. Because of these reasons routine controls and appropriate treatment plan is important.

MULTIPLE TRAUMA OF AN ANTERIOR CROSS-BITE PATIENT: A CASE REPORT

Karaalioglu, Esra*, Bani, Mehmet, Öztas, Nurhan
Gazi University Faculty of Dentistry
Pediatric Dentistry
Ankara, Turkey

Keywords: extrusion, intrusion, cross-bite

Purpose: Traumatic dental injury (TDI) is a common situation which can lead to serious injuries of dental and periodontal tissues. A multiple TDI that consist of both intrusive and extrusive luxation is a rare issue. The purpose of this case report is to present an 8-year-old female patient who had anterior cross-bite and suffered intrusion and extrusion of maxillary central incisors at the same time.

Methods & Materials: The patient was referred to Gazi University Faculty of Dentistry, Department of Pediatric Dentistry within 1 hour after trauma. During clinical examination intrusion of maxillary right central incisor tooth (#11) and extrusion of maxillary left central incisor tooth (#21) was detected. Injury of the periodontal tissues was also observed. Radiographic examination revealed that the apices of the both teeth were immature and only 1/3 of the roots were developed. After repositioning of #21, teeth were splinted. Three weeks later the splint was removed. At the 7-month follow-up, discoloration of #21 was detected. The loss of lamina dura could also be seen around the root of the tooth. In addition, the root development was ceased. Apexification treatment was indicated.

Results: It was observed that intruded #11, which was sited in cross-bite, was spontaneously rescued from malocclusion without additional treatment. The patient follow-ups have taken place for one years.

Conclusion: This report indicates that treatment options depends on the vitality of the teeth in trauma cases. Additionally, the dislodged teeth could come into its original position spontaneously.

CONSERVATIVE MANAGEMENT OF A UNILATERAL CONDYLAR FRACTURE IN A CHILD

Kasimoglu, Yelda*, Guven, Yeliz, Tuna-Ince, Elif Bahar, Aktoren, Oya, Gencay, Koray
Istanbul University Faculty of Dentistry
Department of Pedodontics
Istanbul, Turkey

Purpose: The management of mandibular condylar fractures in children remains challenging because of its adverse effects on growth process. The aim of this report is to evaluate the clinical and radiographic outcomes of a unilateral condylar fracture in a pediatric patient treated by conservative techniques.

Methods & Materials: A 7-year-old boy was referred to the Istanbul University Faculty of Dentistry Department of Pedodontics following a facial trauma caused by a fall at school. On clinical examination; sutured laceration on the lips, limited mouth opening and lateral deviation of the mandible toward the left side on mouth opening movements were noted. Radiographic examination by panoramic radiography and Cone Beam Computed Tomography revealed a unilateral displaced condylar fracture on the left side. Closed reduction technique (nonsurgical treatment) was chosen for the management of condylar fracture. Antibiotics and anti-inflammatory analgesics were prescribed and a soft diet was recommended at the initial visit. A mandibular occlusal splint with a 3 mm acrylic height on the side of fracture was applied for functional repositioning of the mandible.

Results: After two years of follow-up, clinical examination showed recovery of the limited mouth opening and the dental midline deviation. A stable and satisfactory occlusion and normal jaw movements were achieved. Radiological examination showed a remarkable remodeling of the fractured condyle.

Conclusion: Nonsurgical treatment of mandibular condylar fractures with a removable occlusal splint lead to acceptable remodeling of the condylar process, good clinical outcome, and minimal symptoms in growing children.

CLINICAL MANAGEMENT OF A COMPLICATED FRACTURED MAXILLARY CENTRAL INCISOR

Kaya, Emine*, Elbay, Mesut* Yaprak, Emre*
Kocaeli University
Pediatric Dentistry
Kocaeli, Turkey

Purpose: The aim of this case report is to describe an interdisciplinary approach for treatment of complicated crown root fractured maxillary central incisor with open apex, using a combination of endodontic, minor periodontal surgery and reattachment procedures.

Methods & Materials: A 10-year-old female patient applied to the Kocaeli University Department of Pediatric Dentistry, with a complicated crown root fracture of the right maxillary central incisor with wide open apex, 2 hours after the trauma occurred. After clinical and radiological examinations, the coronal fragment was removed and upheld in distilled water for reattachment. Endodontic treatment was performed with the chemical-mechanical preparation and calcium hydroxide paste was placed in root canals. The patient was called for 1 month regular follow-up to check the root formation. At the end of 10 months the root was obturated by gutta-percha as the apex was closed. After the periodontal tissue management, reinforced glass fibre was placed in the root and the fragment reattachment was performed using dual-cured composite resin cement.

Results: Examination 6 months after treatment revealed good periodontal health, esthetics and normal function.

Conclusion: Complicated fractures are common forms of traumatic dental injuries that mainly affect the maxillary central incisors, in children and teenagers. Since causing aesthetic, functional and physiological problems; these fractures especially in immature teeth require immediate treatment. When the tooth fragment is available and intact, reattachment is a preferable treatment choice because of its natural appearance. The reattachment procedure proved to be biologically superior in addition to its esthetic value and psychological advantage.

ORAL CAVITY FINDINGS AFTER THE RHABDOMYOSARCOMA TREATMENT: A CASE REPORT

Keskin, Gül*, Kizilci, Esra
Inonu University
Department of Pediatric Dentistry
Malatya, Turkey

Keywords: Rhabdomyosarcoma, Radiotherapy, Oral Cavity Findings

Purpose: Rhabdomyosarcoma (RMS) is a frequent malignant tumor of childhood originating from embryonic mesenchyma. It consists of 10-15% of all solid tumors and 50% of all soft tissue sarcomas of childhood. The common sites of occurrence are the head and neck region, genitourinary tract, retroperitoneum, and, to a lesser extent, the extremities. Treatment of the RMS is by a multidisciplinary approach. It consists of surgical removal of the tumor followed by multiagent chemotherapy with or without radiotherapy. Radiotherapy and chemotherapy in the head and neck region of young patients can lead to impaired dental and osseous development, a destructive form of dental caries, delayed eruption of the teeth, root stunting, microdontia, hypodontia, discoloration, incomplete calcification of the teeth.

Methods & Materials: A 9-year old boy was referred to our institution for the dental caries. On history taking, his parents reported that the disease had started as a painless swelling in February 2010. Then, disease was treated with surgical removal, radiotherapy and chemotherapy after being diagnosed with rhabdomyosarcoma. Radiotherapy and chemotherapy treatment was completed in January 2011. His parents reported that child's growth slowed after the treatment. Clinical examination showed that the boy had many deep caries and discoloration. After the radiographic examination, roots of the lower first molars were found to be shorter than usual and the upper first molars had taurodontism. The dental treatment included root canal treatment, composite restorations, extractions and removable prostheses.

Results: The treatment of the rhabdomyosarcoma and dental treatment of the patient were completed. The patient was called routine controls.

Conclusion: The head and neck region is the most common site for rhabdomyosarcoma. Radiotherapy for the treatment of rhabdomyosarcoma may affect teeth when they were applied during the tooth development. It should be noted that impaired dental and osseous development and root stunting after the radiotherapy can lead to an increase in bone and teeth fracture. Dentists must be careful because of traumatic forces in dental applications, especially tooth extractions.

MANAGEMENT OF A MULTIPLE TRAUMATIC INJURY: A CASE REPORT

Kinay, Pinar*, Alacam, Alev
Gazi University Faculty of Dentistry
Department of Pediatric Dentistry
Ankara, Turkey

Keywords: multiple dental trauma, avulsion, lateral luxation

Purpose: Luxation injuries are frequently seen among young population. The frequency of luxation injury in permanent dentition is 15 to 40 % of all dental injuries whereas avulsion rates were 0.5 to 3 %. Multiple traumatic cases are more complicated and difficult to treat for dentists. This report describes a case of a 13-year-old male who had traumatic injuries at his permanent maxillary incisors due to an accident while playing.

Methods & Materials: When the patient had come to the clinic 70 minutes after trauma, lateral luxation of tooth 11 and avulsion of teeth 12 and 21 were observed. Teeth of 12 and 21 were dry stored for the first 10 minutes, then put into milk for 60 minutes. The initial treatment was replantation and reposition with a semi-rigid splint. One week after replantation and splinting, all of the teeth were endodontically treated. Semi-rigid splint was removed 4 weeks after the initial treatment. However, 6 months follow-up results showed inflammatory resorption in all the teeth. The teeth were retreated and canals were obturated with mineral trioxide aggregate(MTA). At the 14 months follow-up, apical resection was decided for tooth 11 whereas no further treatment is needed for the other teeth.

Results: Clinical and radiographic follow-up was managed for 20 months and it represents regeneration of the periradicular tissues and re-establishment of the periodontal space as desired.

Conclusion: It could be concluded that if inflammatory resorption occurs due to multiple traumatic injuries, obturating the canals with MTA can be a good option.

DELAYED REPLANTATION OF AVULSED TOOTH: A CASE REPORT

Kirzioglu, Gozde*, Cantekin, Kenan ; Kolcakoglu, Kevser
Erciyes University
Pediatric Dentistry
Kayseri, Turkey

Purpose: Tooth avulsion constituting an emergency for children and adolescents. Avulsion of permanent teeth is most serious of all dental injuries and accounts for 1-16% of all traumatic injuries, of which maxillary incisors are most commonly involved. The aim of this report is to show how to manage a delayed avulsion case.

Methods & Materials: A healthy seven-year-old boy reported to the Erciyes University, Faculty of Dentistry, Department of Pediatric Dentistry with a complaint of missing immature permanent mandibular left central incisor. The patient had reported 3 days after the trauma with tooth stored in dry condition. Extraoral root canal treatment has been performed and it has been gently replanted. Occlusion has been evaluated and wire splinted with acid etch composite resin attached to adjacent teeth for a period of 2 weeks. We have been following up the patient for one year.

Results: The patient has been followed up regularly at 1,3,6,12th months to determine the ultimate fate of this tooth, replanted under unfavorable conditions. Any resorption hasn't been seen in radiographic examination yet. Any clinical symptom regarding to containing signs of failure hasn't been reported.

Conclusion: Reimplantation is the most appropriate approach for the treatment for avulsed teeth. Although, we reported favorable findings in this clinical report, long term and further clinical studies require in this area.

THE LATE-TERM TREATMENT OF AN UNTREATED CROWN-ROOT FRACTURE: CASE REPORT

Kitiki, Burak*, Kalyoncu I, Eren Giray F, Menten A, Tanboga I
Marmara University, Faculty of Dentistry
Department of Pediatric Dentistry
Istanbul, Turkey

Purpose: This study presents the treatment procedures of the aesthetic and functional problems seen in an untreated pediatric patient with a trauma to the upper anterior region that took place two years prior to the study.

Methods & Materials: A ten year old male patient attend to the Marmara University, Department of Pediatric Dentistry in January 2012 with a complaint about a repeating abscess formation in the upper right incisor region. The clinical and radiological examinations revealed that the upper right central incisor had been subject to a crown-root fracture at the cervical third of the root in year 2010. The crown of the tooth had been avulsed and the root submerged under the gingiva has been left untreated for two years and caused recurrent infection. In the first appointment the gingiva covering the root was removed by a diode laser on gingivectomy mode (800-810 nm) under local anaesthesia, at the same session the root was surgically extruded and orthodontic splint was applied and endodontic treatment was initiated by cleaning root canal and applying intra canal medicament CaOH. After a 4 week period, the splint was removed, apical infection healed and the apical third of the root was obturated with MTA (Angelus White). One day later the root canal treatment was finished by guttapercha and endomethasone and than root canal was prepared for die-cast post-core application. On the following week tooth was restored with a zirconium crown after a post-core application.

Results: The patient has been followed up at the 6-month,12-month and 24-month appointments. According to clinical and radiologic examinations the tooth was asymptomatic.

Conclusion: In trauma cases especially in young adults, treatment options must include keeping teeth or the roots in the mouth as much as possible rather than extracting them. Our case showed that the proper treatment of neglected traumatized teeth could be saved and bone loss in alveolar bone in developing young adults could be avoid.

HORIZONTAL ROOT FRACTURE IN MAXILLARY CENTRAL INCISOR: A CASE REPORT

Kolcakoglu, Kevser*, Dogan, Salih; Cantekin, Kenan; Kirzioglu, Gozde
Erciyes University, Faculty of Dentistry
Pediatrics Dentistry
Kayseri, Turkey

Purpose: Horizontal root fractures usually are characterized by a fracture line that is perpendicular to the long axis of the tooth's root. Assessing the three dimensional orientation of a fracture is correlated to treatment and outcome. Root fractures are diagnosed through clinical and radiographic examination. In this type of injury are seen healing calcified tissue, granulation tissue, connective tissue, bone and connective tissue. Aim of this study is to provide calcified tissue healing in maxillary left central incisor with horizontal root fracture.

Methods & Materials: Nine year old male without systemic diseases was admitted to Erciyes University, Faculty of Dentistry, Department of Pediatric Dentistry with tenderness to percussion and pain in maxillary left central incisor four days after the trauma. There was a horizontal root fracture in maxillary left central incisor. Injured maxillary left central incisor were splinted for six months; 0,5 mm full round wire. Patient was observed with 1, 3 and 6 month follow-up periods, clinically and radiographically.

Results: Clinically, traumatized tooth gave a positive response to vitality tests. Negative findings such as palpation, percussion and mobility was not observed. In addition, calcified tissue formation was observed between broken root parts at radiographic examination.

Conclusion: During the six month treatment of the injured tooth, calcified tissue healing observed around the fracture line and the tooth was vital end of this period. On the other hand, possible failures emerged from loose of vitality in long term period should not be ignored.

TREATMENT OF A SEVERE DENTAL TRAUMA CASE: TWO YEAR FOLLOW-UP

Kopac, Olcay*, Demiriz, Levent; Misir, Ahmet Ferhat
Bulent Ecevit University, Faculty of Dentistry
Department of Pediatrics; Department of Oral and Maxillofacial Surgery
Zonguldak, Turkey

Keywords: Calcium hydroxide, Dental trauma, Splinting

Purpose: The aim of this report is to present a severe dental trauma case which included all maxillary incisors and it's multidisciplinary treatment and long term clinical-radiological follow up.

Methods & Materials: An 11 year old girl patient referred to the clinic of Pedodontics with an occurred urgent situation after an accident. It is understood after a clinical and radiological examination that four maxillary incisors were badly affected in the accident because of a trauma on both jaws. Intrusion attended with rotation, only intrusion and lateral luxation situations were identified in four maxillary incisor teeth. First step of the treatment was completed by fixing all affected teeth in their normal occlusal position with surgical intervention and splinting. The other step was endodontic treatments of all maxillary incisors teeth to prevent probable infections. Before the permanent root canal fillings, periodical calcium hydroxide dressings were applied to all teeth to avoid ankylosis. Although this measure, an external root resorption was occurred in one tooth. However, the resorption was stopped by increasing number of the calcium hydroxide dressing of this tooth and the condition was taken under the control. The splint was removed after 4 weeks. Crown restorations were completed with composite-resin after the root canals were filled. Periodical follow-up was done with clinical and radiographic examinations.

Results: At the end of 24 months, no clinical or radiographic signs of pathology were observed in all teeth. In addition, there was not any complaint stated by the patient about the functions of the teeth.

Conclusion: Although the severity of the dental trauma is in high levels, there may be a chance to prevent the tooth loss and some important factors such as referring time, appropriate treatment option, cooperation of the patient and periodical follow-up may increase this chance.

ROOT RESORPTION DUE TO ABNORMAL PRESSURE HABIT: A CASE REPORT

Kucukyilmaz, Ebru*, Savas, Selcuk; Veli, Ilknur
Izmir Katip Celebi University Faculty of Dentistry
Department of Pediatric Dentistry
Izmir, Turkey

Keywords: Root Resorption, Abnormal Pressure Habit

Purpose: Pathological root resorption of permanent teeth is a multifactorial process. Various factors such as trauma, periapical or periodontal inflammation, tumors, cysts, orthodontic therapy, occlusal stresses, impacted teeth and abnormal pressure habits cause root resorption to different extents. Abnormal pressure habits are repetitive actions that are being done automatically and most of them start and finish spontaneously. Aim: The aim of this study was to present severe root resorption of maxillary permanent incisors caused by tongue-thrust and antero-posterior grinding habits.

Methods & Materials: Case Report: A 9-years-old girl was referred to Pediatric Dentistry clinic with the chief complaint of mobility in her upper central incisors. Patient history revealed tongue-thrust and antero-posterior grinding habits. In intraoral examination, Angle Class II Division 2 malocclusion, polidiastema between upper anterior teeth and Grade I mobility of upper central incisors were observed. Radiographic examination showed that maxillary central incisors had severe root resorption without any periapical infection. Preliminary treatment objectives included the elimination of abnormal habit, decrease the level of mobility and provide comparatively stabile central incisors. Because of the patient's mobility, a combination of preventive orthodontic treatment was proposed as a favorable treatment option. At the beginning of treatment, full-coverage thermoplastic retainers were placed to eliminate the pressure caused by occlusal contacts. Then splint therapy with 0.195 inch round twist-flex arch wires placed on the maxillary incisors were initiated and sustained for 4 months. During therapy, habit breakers constructed from 0.090 inch round stainless steel archwires were banded on maxillary first molars to prevent tongue-thrust and checked in each session.

Results: At the end of 4-month duration, the mobility of the teeth decreased and no further root shortening was observed.

Conclusion: Tongue thrust and antero-posterior grinding habits can result in damage to dentoalveolar structure. Therefore, dentists play a crucial role in the prevention of these habits, treatment of the pathologies and providing necessary information to the parents.

MANAGEMENT OF SEVERE TRAUMATIC DENTAL INJURY: A CASE REPORT

Kurt, Affan*, Bani, Mehmet , Ulusu, Tezer
Gazi University
Pediatric Dentistry Department
Ankara, Turkey, Turkey

Purpose: Traumatic dental injuries(TDI) of permanent teeth occur frequently in children. About 5% of all dental traumas are found to be associated with crown root fractures. Clinical considerations for the management of crown root fractures include extent and pattern of fracture, restorability of remaining tooth, availability of fractured fragment and damage to the periodontal attachment. In this report, the treatment of severely traumatized maxillary left central-lateral incisors with complicated crown and crown-root fractures was described.

Methods & Materials: A 12-year-old boy with dental trauma to anterior maxillary region as a result of a fall referred to Gazi University Department of Pediatric Dentistry clinic. Intraoral and radiographic examination presented left central incisor with complicated crown-root fracture and lateral luxation, left lateral incisor with complicated crown fracture and right central incisor with extrusion. Left central-lateral incisors both had single session root-canal-treatment. Following the extraction of fractured crown-root segment, left central incisor was extruded surgically. Teeth were splinted with wire-composite for 4 weeks. After removal of the splint, restoration of both teeth were done with fiber post and composite resin.

Results: The patient was called for follow ups regularly in first year. He presented normal clinical and radiographic findings at each visit.

Conclusion: Treatment of the severely traumatized anterior teeth with crown-root fractures can be complex and frustrating for the dentist but choosing the right treatment approach will help to save the teeth.

THE MANDIBULAR CONDYLAR FRACTURES IN PEDIATRIC PATIENTS: TWO CASES

Kuru, Sinem*, Guven, Yeliz , Yildirim, Mine , Sepet, Elif , Gencay, Koray
Istanbul University
Department of Pediatric Dentistry
Istanbul, Turkey

Keywords: condylar fractures, occlusal splint, children

Purpose: The mandibular condylar fractures in pediatric patients require special attention because of the possible effects of the chosen treatment on the future growth of the patient. The purpose of this report is to evaluate the clinical and radiographic outcomes of condylar fractures in two cases.

Methods & Materials: CASE 1: 6 year old girl was referred to the clinics of Istanbul University, Department of Pediatric Dentistry with mandibular condylar fracture following a facial trauma caused by a fall at home. Clinical examinations showed that lacerations on the chin and lips, limited mouth opening and lateral deviation of the mandible during mouth opening. Radiographic examinations by panoramic radiography and Cone Beam Computed Tomography showed that condylar fracture is on the right side. CASE 2: 10 year old girl with mandibular condylar fracture was referred to the clinics of Istanbul University, Department of Pediatric Dentistry following a facial trauma caused by a fall. Clinical examinations showed that lacerations on the chin and lips, limited mouth opening and lateral deviation of the mandible during mouth opening. Radiographic examinations by panoramic radiography and Cone Beam Computed Tomography showed that condylar fracture is on the left side. In both cases, the same treatment protocol was applied. Closed reduction technique was chosen for the management of condylar fractures. Antibiotics and anti-inflammatory analgesics were prescribed and a soft diet was recommended at the initial visit. A mandibular occlusal splint with a 3 mm acrylic height on the side of fracture was applied for functional repositioning of the mandible. After 1 year of follow-up, clinical examinations showed that lateral deviation of the mandible was improved and a stable and satisfactory occlusion was obtained. Radiographic examinations showed that remodeling of condylar fractures was acceptable.

Results: After 1 year of follow-up, clinical examinations showed that lateral deviation of the mandible was improved and a stable and satisfactory occlusion was obtained. Radiographic examinations showed that remodeling of condylar fractures was acceptable.

Conclusion: Positive healing potential and prognosis can be obtained with a removable occlusal splint after mandibular condylar fractures in children. Condylar fractures demand careful treatment and follow-up to prevent progressive disturbances in mandibular growth and facial development.

EXTRA-ORAL FISTULA AS A RESULT OF CHILDHOOD TRAUMA

Kurun, Merve*, Memis Özgül, Betül* Ulasan, Direnç** Kayıkçı, Berna *Tulga Öz, Firdevs*
Ankara University Faculty of Dentistry
*Department of Pedodontics **Department of Oral and Maxillofacial Surgery
Ankara, Turkey

Keywords: Extra Oral Fistula, Childhood Trauma

Purpose: The aim of this case presentation was to emphasize the importance of following examination after dental trauma.

Methods & Materials: A fourteen-year-old male patient was referred to our clinic after showing extra-oral swelling and pain on the mentum for five months which couldn't be diagnosed and treated by medical doctors. Patients extra-oral examination showed scar tissue related to fistula track and the previous interventions by medical doctors. In intra-oral examination, it was noted that the right first mandibular incisor was malformed. The crown was inclined toward the lingual side. The parents stated as the tooth had erupted in this form and with further questioning the patients stated that patient had a trauma history at an early age but there weren't any medical or dental aid given at the time of the trauma. Following the complete clinic and radiographic examination of the patient it was decided the radiolucent area was related to the periapical infection of the traumatized incisor.

Results: In treatment, as first step the right and left first mandibular incisors underwent root canal treatment. Following the root canal treatment the lesion and the sinus tract have been removed as surgically under local anesthesia. The follow-up appointments revealed that the clinical symptoms has pasted. The scar tissue of fistula started to heal but not completely.

Conclusion: We like to highlight the importance of dental examination following the trauma that happened in any age. With regular follow-ups it could be possible to prevent complex complications that may occur in the years to follow up as described in the previous case.

THE RESTORATION OF IMMATURE RIGHT UPPER TOOTH WITH COMBINATION INJURES

Liu, Yanli*, Chen, Yongjin, Zhang Min, Xiong, Xizhou
College of Stomatology, Fourth Military Medical University
Department of General Dentistry & Emergency
Xi'an, Shanxi, China

Purpose: The restoration of immature permanent tooth is an important public health problem, because it has severe physical or psychological impacts to children, and the restoration influences the alveolar bone development. This is a case about the treatment of an adolescent patient with a traumatically crown-root fracture, root fracture and intruded incisor.

Methods & Materials: The case involved operative evaluation with dental computed tomography and a multidisciplinary approach including surgical, endodontics, orthodontic, periodontal therapy, as well as strengthen postoperative observation and regular follow up. It took one year for the treatment (including orthodontic treatment for six months, endodontics treatment for one month, and periodontal treatment for three months).

Results: The imbedding crown piece was removed surgically. After orthodontic treatment of the tooth with a fixed appliance for one month, the dental pulp necrosis occurred and then the root canal therapies were carried out immediately. When orthodontic treatment was over, the tooth had no root resorption. Meanwhile, the tooth was restored with composite-resin restoration. In the follow up reviews, The tooth is stable in alveolar and the alveolar bone has no signs of inflammation and resorption.

Conclusion: Based on the information presented in this case, we conclude that exploring the restorative procedure about young permanent teeth for both doctors and patients is import. The comprehensive treatment options are important for the restorative for immature permanent teeth.

MULTIDISCIPLINARY MANAGEMENT OF FRACTURE COMPLICATION OF AN ANTERIOR-TOOTH UNDERGOING APEXIFICATION

Mese, Merve*, Akçay, Merve; Yasa, Bilal; Akçay, Hüseyin
Izmir Katip Çelebi University Faculty of Dentistry
Pediatric Dentistry
Izmir, Turkey

Keywords: trauma, fiber, post

Purpose: Long-term apexification procedures are required for endodontic treatments of immature teeth. The patients undergoing apexification treatment have high crown-root fracture risk because of the thin dentinal walls. The purpose of this case report was to present the multidisciplinary management of a subgingival crown-root fracture of an anterior tooth.

Methods & Materials: A 12-year-old male patient was referred to the pediatric dentistry clinic with an extensive tooth fracture of the right permanent maxillary lateral incisor. Clinical and radiographic examination revealed that the presence of a complicated crown-root fracture which elongate to buccal subgingival area. The dental history disclosed that apexification procedure had been started to perform after his first trauma experience and he neglected his appointment for months. There was a little calcium hydroxide paste left in the root canal and the coronal tooth fragment was mobile and attached to the gingiva. Removal of the fractured coronal fragment, root canal treatment and flap surgery were planned. Under local anesthesia, the coronal fragment was gently extracted. Because of the completion of calcification of apical root area, endodontic treatment was performed at the same appointment and retantion grooves were created on the coronal fragment. Subsequent to the canal obturation, flap surgery was performed to make the fracture line visible. After haemorrhage control, a thin adhesive system (Clearfil SE Bond, Kuraray) was applied to both coronal and root fragments. Coronal fragment was reattached to the root fragment by using dual-cure-luting-composite (Variolink N, Ivoclar Vivadent). Then, the flap was reapproximated to its original position and sutured. The root canal obturation was removed to place fiber post into the root canal for supporting the coronal fragment. The fiber post was stabilized into the root canal with dual-cure-luting composite. Endodontic access cavity of the tooth was restored with composite resin.

Results: At the end of 15-month follow-up, the clinical and radiological investigation of the tooth revealed that tooth was asymptomatic, functionally and esthetically acceptable, had no periapical pathology.

Conclusion: It is important for the patients undergoing apexification treatment to keep their appointments because of the fracture risk. But in the case of complications such as subgingival crown-root fracture, restoration of the fractured tooth by preparing retantion grooves and bonding fiber-reinforced post are effective and necessary approaches for a successful management.

TREATMENT OF CROWN-ROOT FRACTURE: A CASE REPORT

Ölmez, Aysegül*, Akdemir, Yasemin
Gazi University Faculty of Dentistry
Pediatric Dentistry
Ankara, Turkey

Keywords: crown-root fracture, fiber-post, traumatic injury

Purpose: Maxillary incisors are the most common teeth involved in dental trauma because of their exposed position in the dental arch. Traumatized anterior teeth require quick functional and aesthetic repair. This case report describes a complicated crown-root fracture with the necessity of endodontic treatment. Fiber-post was used to create a central support stump to restore the dental morphology.

Methods & Materials: A 11-year-old boy with a history of sports injury 18 hours ago referred to Department of Pediatric Dentistry. He had pain and mobility of upper anterior teeth. Clinique examination revealed oblique fracture line on maxillary right central incisor. The line was 1mm supragingivally on the labial surface and extending palatally towards the coronal third of root. The fractured coronal segment was mobile. There was a subluxation in the left central incisor. Radiographic examination confirmed the fracture line on right central incisor and the closed apex on both of the right and left central incisors. Stabilization of left central incisor was obtained using a composite splint and fractured mobile coronal fragment of left central incisor was removed under local anesthesia followed by a cauterization of palatal gingiva. Then endodontic therapy of right central incisor was started. At the 1-week follow up it was observed that the composite splint wasn't stable and the left central and lateral incisors were symptomatic. It was decided to renew the splint with a wire and composite and to start endodontic therapy of left central and lateral incisors. At the 3-week follow up endodontic therapy was completed and splint was removed. 1 week later fiber post was placed and the composite resin restoration of right central incisor was completed.

Results: The patient was called for 3 months, 6 months, 1 year and 2 year appointments and the teeth were asymptomatic.

Conclusion: In trauma cases if the injury involves the loss of extensive tooth structure, it alters the child's appearance and makes him the target for teasing and ridicule by other children. So it is important for children to achieve aesthetic restorations concerning psychological pressures. In this case the results were satisfactory clinically. The patient was followed up for 2 years.

ALVEOLAR FRACTURE TREATMENT: 3 CASE REPORTS

Osman, Fatma Bahar*, Borbay Akgül, Sevil Kahraman, Kamil Botsali, Murat Selim & Tosun, Gül & Yildirim, Sibel
Selçuk University Faculty of Dentistry
Pediatric Dentistry
Konya, Turkey

Purpose: Dentoalveolar injuries are the most common type of facial injury and are often associated with concomitant facial fractures. These injuries may initially be seen by surgeons who do not have formal dental training. The aim of this case report was to document the treatment of two mandibular and one maxillary alveolar fractures.

Methods & Materials: Three patients were referred to the Selçuk University, Faculty of Dentistry, Department of Pedodontics, with complaint of fall and bump. In all cases anterior segments were fractured. All fractures fixed with rigid splint for four weeks. In two cases teeth in fracture line maintained their vitality. Other case teeth in the fracture line lose their vitality and root canal treatments were performed.

Results: All patients have been followed up for 2 years and does not have any complaints.

Conclusion: When correct treatment procedure applied in dentoalveolar injury, fractured segment can provide maintain was original place in a healthy way.

MULTIPLE TRAUMATIC INJURIES:TREATMENT OUTCOME WITH 7-YEARS FOLLOW-UP

Özer, Levent*, Seberol, Erçin
Ankara University Faculty of Dentistry
Department of Pedodontics
Ankara, Turkey

Keywords: Multiple Trauma, Avulsion, Root Fracture

Purpose: Dental traumatic injuries range in severity from a simple enamel fracture to a complete avulsion. These injuries represent painful and distressing events and may result in complications like discoloration, root fracture, root resorption, ankylosis and tooth loss. In some of these cases only one tooth can be affected from dental trauma whereas in some others more than one tooth can be affected. This report describes a case of an 8-years-old girl who suffered multiple traumatic injuries to her permanent and primary incisors after falling from ladder.

Methods & Materials: Root fracture of tooth 11, extrusive luxation of tooth 21, avulsion of teeth 22, 32, 63 and 73 were observed at the emergency visit 30 minutes after the trauma. The treatment plan according to IADT guidelines was performed with the satisfaction of the dentists and the patient. Avulsed teeth 22 and 32 were replanted. Coronal fragment of tooth 11 with root fracture and extruded tooth 21 were repositioned. After that both arches were stabilized with flexible splint.

Results: Patient was called for follow-up sessions every 2 months for first year afterwards follow-up sessions was carried out every two years. After one-year follow-up tooth 32 was extracted due to the replacement resorption. Apical fragment of tooth 11 was surgically removed because of the separation of the fragments.

Conclusion: In conclusion, a favorable outcome like ideal occlusion was improved as a result of proper diagnosis, meticulous and careful follow-up and a successful treatment plan for each traumatized teeth.

EXTRUSIVE LUXATION OF IMMATURE INCISORS INVOLVING SEGMENTAL ALVEOLAR PROCESS FRACTURE

Ozgur, Beste*, Cehreli, Zafer
Hacettepe University
Pediatric Dentistry
Ankara, Turkey

Purpose: The aim of this report is to present a late-referral case of extrusive luxation trauma, associated with fracture of the maxillary buccal cortical bone; and the successful long-term outcome of a minimal intervention approach.

Methods & Materials: A 7-year-old boy was admitted to pediatric dentistry clinic 24 hours after a fall accident. The child presented with a sutured laceration and abrasions of an edematous upper lip. Intraoral findings included gingival and mucosal lacerations, extrusive luxation of both immature maxillary permanent central incisors and fracture of the maxillary buccal cortical bone. Following reduction of the segmental alveolar process, gingival lacerations were sutured and the extruded central incisors were splinted in their palatally-displaced position so as not to induce further tissue trauma by late repositioning. The splints were removed after 3 weeks.

Results: At 6 months, both clinical and radiographic findings indicated optimal healing along with continued development of the immature roots. Annual radiographic controls indicated gradual narrowing of root canals. At the 5th year, the child had a self-corrected occlusion with healthy maxillary central incisors.

Conclusion: In cases of late referral luxation injuries, stabilization and minimal intervention may offer a good, long-term treatment outcome in selected cases.

RESULTS OF AN UNHEEDED PRIMARY TOOTH INJURY- A CASE REPORT

Özkul Öno1, Seda*, Kirzioglu, Zuh1*, Kömerik, Nurgül**

Suleyman Demirel University

*Department of Paediatric Dentistry, **Department of Oral and Maxillofacial Surgery
Isparta, Turkey

Keywords: Dental Trauma, Sequele, Fibroma

Purpose: Traumatic luxation injuries occurred before 3-years-old in primary dentition can cause sequele in permanent dentition.

Methods & Materials: A 11-year-old young boy referred to our pediatric dentistry clinic due to his swelled upper lip. Besides absence of any systemic health problems, when his dental history examined, his parents reported that he had orthodontic treatment for about 8 months. Parents stated that patients right upper central permanent tooth was tried to be repositioned, but remained unsuccessful. It's announced that after leaving the treatment undone, his upper lip was swelled and the patient was depressed because of this asymmetry. When the patients history was deepened, it has been learnt that the patient was fell down to the roof when he was 2-years-old and in consequence of the injury, his right upper central primary tooth was presumably intruded. Our patient had not been taken to any physician or dentist after this trauma. On clinical examination, it was seen that right upper central permanent tooth was located horizontally and its incisal edge was towards to the labial mucosa. Also, a fibrotic non-bleeding soft tissue growth approximately 1cm wide was seen at the level of the incisal edge. On the palatal surface of upper lateral incisor teeth, decalcified areas were exist. On the radiographic examination, root dilaceration of the tooth was seen because of the previously occurred trauma. The tooth was completed the root development so as to fall short, with an 90 °angle towards to the crown's labial surface at the coronal 1/3 level of the root. According to the clinical and radiographic evaluation, under local anesthesia, patient's tooth and fibrotic tissue was taken. After one-week at the control appointment, swelling of the lip was gone and the injury in the mouth was healed uneventfully. A fiber-reinforced space maintainer with tooth was placed.

Results: Parent's lack of awareness about this issue and their disregarding to this early age trauma, revealed an inadequate anamnesis. Parent's deemed the physicians responsible because of their inability of making this connection. On the other hand, determining an appropriate treatment regimen necessity of an adequate clinical and radiographic evaluation has been demonstrated once again.

Conclusion: As a result of inadequate assessment, an unsatisfactory orthodontic treatment was planned and this results with family's and patient's complaints. In addition, irritation fibroma (traumatic fibroma), a reaction to chronic irritation, is a benign lesion. However the possibility of precancerous transformation should not be overlooked.

TWO CASE REPORTS ABOUT THE PROGNOSIS OF DELAYED-REPLANTATION

Oztas, Nurhan*, Didem Sakaryali, Nagehan Duygu, Alev Alacam
Gazi University, Faculty of Dentistry
Pediatric Dentistry
Ankara, Turkey

Keywords: Avulsion, Delayed Replantation, Root Resorption

Purpose: The avulsion of anterior teeth of young children is a complicated trauma type and may incur several complications. This report describes two cases who was referred to Paediatric Dentistry Department of Gazi University with the complaint of dislodgment of teeth and the treatments according to delayed replantation procedures.

Methods & Materials: Case 1: This case report describes treatment procedures for 11-year-old male patient. According to the history, after the avulsion, patient appealed within 60 minutes but tooth was kept in improper conditions so, replantation had done according to delayed replantation procedure. The tooth was reimplanted, rigid splint was done and root canal treatment was started the next day. Ledermix and calcium hydroxide had used as dressing materials respectively and at the second week root canal treatment was finished and the splint was removed. Case 2: This report describes a clinical case of a 10-year-old boy, who underwent an avulsion of the upper left central incisor. The avulsed tooth was kept in the dry condition for 60 minutes from the moment of trauma until its replantation. Tooth replantation and composite splint was done at emergency department one day before referral to our clinic. Root canal treatment was started in first week because the teeth was mature. Calcium hydroxide had used as dressing material and root canal treatment was finished in 3 months.

Results: During two year follow up no clinical symptoms and radiographic findings were seen in both cases. Unfortunately, at the end of two year discoloration was diagnosed and root resorption was seen at the middle third of root in both teeth. It is planned to make retreatment however, the prognosis of both cases was so poor that extraction was inevitable.

Conclusion: The success of delayed replantation could be discussed for these cases but, the avulsed teeth that was replanted conserved their aesthetic appearance and functionality for three years after replantation. Therefore, delayed replantation must be preferred during the period of growth and development to save time.

COMPLICATED CROWN-ROOT FRACTURES TREATED USING REATTACHMENT PROCEDURE: A CASE REPORT

Özveren, Neslihan*, Sari, Mustafa Erhan; Taskan, Mehmet Murat; Koyutürk, Alp Erdin
Bezmialem Vakif University, University of Ondokuz Mayıs
Department of Pediatric Dentistry, Department of Periodontology
Istanbul, Turkey

Keywords: crown-root fracture, maxillary central incisor, reattachment

Purpose: Anterior teeth trauma of a young patient requires immediate attention not only because of damage to dentition but also because of its psychological impact on patient and parents. Primary goal of the treatment remains esthetic and functional rehabilitation. Several therapeutic procedures are available for fractured anterior teeth. However, reattachment of the fractured fragment is an excellent biological approach for restoration, when the fragment is available. Tooth fragment reattachment (biological restoration) offers the advantage of being simple, less time consuming, esthetically pleasing result and conservative technique. This report describes the management of complicated crown-root fractures by reattachment procedure in a young patient, with 1.5-year of follow-up.

Methods & Materials: 12-year-old boy was referred to Department of Pediatric Dentistry, University of Ondokuz Mayıs, Samsun, Turkey, 2 hours after having fallen from bicycle and suffering a traumatic injury of maxillary central incisors. The parents brought two fractured crown fragments of central incisors. Firstly bleeding was taken under control. Then fracture type and fragment-fracture line consistency were evaluated. Subgingival oblique crown-root fracture was detected in both maxillary central incisors. After endodontic treatment, because of inadequate angle of sight of the fracture line and isolation difficulties apically repositioned flap surgery was performed. During surgery the fragments were reattached with fiber post and dual-cured resin luting agent. Clinical examination was conducted at 1-, 6-, 12- and 18-month for follow-up, and it was observed that both endodontic treatment and biological restoration remained clinically acceptable for the entire time. 1.5 year follow-up showed satisfying anatomic and functional success.

Results: The alternative treatment modalities of crown-root fractures are fragment reattachment, composite resin restoration and full crown coverage. Literature reports considered the fragment reattachment as a conservative alternative to composite build-up and full crown coverage.

Conclusion: High incidence of trauma to dental tissues entail having proper knowledge of the techniques available and their indications, along with risk benefit ratio. The reattachment technique is a simple, less time consuming, and conservative technique but is possible only when the tooth fragment is available. The main concern is to educate the population to preserve the fractured fragment and seek immediate dental care.

SURGICAL REPOSITION OF IMPACTED DILACERATED INCISOR IN A PEDIATRIC PATIENT

Pekel, Barhan*, Cekmegeli, Ezgi; Menten, Ali
Marmara University
Department of Pediatric Dentistry
Istanbul, Turkey

Keywords: reimplantation, forced eruption, trauma

Purpose: A pediatric dentist is frequently confronted with disturbance in developing occlusion as soon as first permanent teeth erupt in the mouth. This case presents an early treatment approach for mixed dentition with a history of dental trauma.

Methods & Materials: 9 year-old-male patient referred to our Department of Pediatric Dentistry at Marmara University due to disturbed eruption of maxillary incisor teeth as a his main complaint. His dental history revealed a severe fall a few years ago including facial and dental trauma. He was in mixed dentition with Angle Class I malocclusion. Maxillary incisors were erupted and left central incisor was positioned towards vestibular side. Both maxillary lateral incisors were not erupted. Panoramic and periapical radiographs revealed that maxillary right lateral incisor was below gingiva and maxillary left lateral incisor was positioned parallel to horizontal plane. 3D volumetric tomography was used in order to see detailed tooth positions and a severe dilaceration and malformation on the root of maxillary left lateral incisor was noticed.

Results: In first step two central incisors were repositioned using an auxiliary archwire. Diode laser was applied to remove the gingiva covering maxillary right lateral incisor for the aid of the eruption. After full repositioning of 3 incisors, maxillary left lateral incisor was surgically reached, extracted, replanted in the right position and splinted to adjacent central incisor using composite resin. Root canal treatment was performed 3 weeks after the surgery together with the composite splint removal. Fixed appliance was placed on all the incisors as a splint. Light forces were applied and successful alignment was reached in 6 months. Fixed appliance was kept on the incisors until maxillary canines erupted naturally.

Conclusion: There were no symptoms during 12 months follow-up after alignment. 3D volumetric tomography showed adequate alveolar bone formation around maxillary left lateral incisor. Our case shows that dilacerated tooth can be treated in pediatric patients with fixed appliances to prevent further problems.

TREATMENT OF A TRAUMATIZED TOOTH WITH ENDODONTIC AND PERIODONTAL APPROACH

Pilak, Sema*, Kusgöz, Adem, Ercan, Esra, Uzun, Bilge Cansu
Karadeniz Technical University, Faculty of Dentistry
Department of Pediatric Dentistry
Trabzon, Turkey

Purpose: Dental trauma frequently occurs in children from 6-13 years old. About 5% of all dental traumas are found to be associated with crown root fractures. Treatment of these teeth are very complicated and difficult. This case report describes treatment of a crown – root fractured tooth with multidisciplinary treatment approach.

Methods & Materials: A 9 - year - old boy was referred to the Department of Pediatric Dentistry in the Dental Faculty of Karadeniz Technical University with a complaint of dental trauma. According to clinical and radiographical examination were detected vertical crown – root fracture occurred along the middle 1/3 of the root of maxillary left central tooth and intrabony defect. It was decided to apply revascularization treatment for apexogenesis and bone augmentation. Firstly, tooth was irrigated with NaOCl, applied the combination of antibiotic drugs (metranidazole, ciprofloxacin and minocycline) and covered with glass ionomer cement. After two days this procedure, full thickness flap was elevated and fracture part of tooth was removed. Root surface was repaired with resin modified glass ionomer cement. Allograft and collagen membrane were applied for bone regeneration. Three weeks later, patient had any complication, supuration, discoloration and pain. Then, MTA was applied to root canal and crown restored with resin composite. The patient was recalled every three months. There were no complication during healing process.

Results: Bone and clinical attachment gain and apexogenesis were observed in the 15-month follow-up.

Conclusion: When crown – root fracture occurs, it is generally associated with pulpal and periodontal damage. Therefore; multidisciplinary treatment approach is important in treating crown – root fractures for long term clinical success.

MANAGEMENT OF SEQUELAE TO AVULSION OF THE PRIMARY INCISORS: 8-YEARS FOLLOW-UP

Pinar-Erdem, Arzu*, Mucuk, Goksen, Yaman, Duygu, Baca, Emrah, Gençay, Koray
Istanbul University, Faculty of Dentistry
Department of Pedodontics, Department of Periodontology, Department of Prosthodontics
Istanbul, Turkey

Purpose: This case report describes the management of developmental dental alterations, crown-root malformation and malposition in permanent dentition as a consequence of avulsion of the primary incisors with alveolar process, in a child of 2 years.

Methods & Materials: At 10 years of age, this patient was referred to Istanbul University, Faculty of Dentistry, Department of Pedodontics for consultation. After clinical and radiographic examinations; hypoplasia, crown-root malformation and malposition of the left permanent maxillary central and lateral incisors, anterior dental crossbite were observed.

Results: Maxillary left lateral incisor was extracted due to its severe mobility. Anterior dental crossbite was corrected with a removable acrylic appliance with a posterior bite-opening platform. After 3 months, the maxillary and mandibular incisors displayed an edge-to-edge bite relationship, and the crossbite was corrected in an additional 3 months. Nance and lingual arch appliances were applied to prevent the space loss and to keep the first permanent molar relationship till the permanent canines and the premolars erupt. Extraction of the right maxillary first permanent premolar was decided to accelerate the eruption of the right permanent canine and gain space for its localization. Balanced extraction of the mandibular first premolars were planned in the mandibular arch. Orthodontic management was performed for levelling and correct alignment of the maxillary left central incisor. Endodontic treatment was applied after orthodontic treatment due to spontaneous pain. The patient exhibited unsatisfactory esthetic appearance in anterior maxilla because of the hypoplastic crown. It has been decided to perform gingival levelling using crown lengthening including all teeth between number 13-23. Prosthetic procedure was initiated after 3 weeks of healing period. For satisfactory aesthetic and functional occlusion, IPS e.max (Ivoclar, Vivadent AG) ceramic system was used for crown fabrication. This patient was followed-up for 8 years and routine clinical controls are going on.

Conclusion: Diagnosis, early intervention by a multidisciplinary team and clinical and radiographic examination of patients who suffer trauma to primary teeth are of importance to minimize or avoid damage to successor teeth.

MTA USAGE ON APEXIFICATION OF AVULSED IMMATURE PERMANENT TEETH

Sahin Unsal, Gulcan*, Ozmekik Atikler, Ozge (1), Ulukapi, Isin (2)

1)Istanbul University, Faculty of Dentistry 2)Okan University, Faculty of Dentistry

Pediatric Dentistry

Istanbul, Turkey

Purpose: Avulsion of permanent teeth is one of the most serious dental injuries, and extra-oral dry time and storage media are very important for the prognosis. The aim of this report was to present two cases with late replanted, avulsed immature permanent maxillary central teeth and their apexification treatments.

Methods & Materials: Case 1: A 9-year old boy referred to the Pediatric Dentistry clinics of Istanbul University Faculty of Dentistry 1 week after an impact trauma to the maxillary right central incisor that caused avulsion. The emergency care was provided 3 hours after the trauma in an other clinic. It was reported that the tooth was kept dry and was splinted rigidly with composite. Radiologic examination revealed that the tooth was immature with open apex. We removed the old splint and resplinted the tooth semiflexibly for 4 weeks. The calcium hydroxide dressing was periodically replaced for 8 months. After that the radiologic control revealed a mineralized bridge formation, the root canal was filled with mineral trioxide aggregate (MTA).

Case 2: An 8-year old girl referred to our clinics 4 days after the avulsion of the maxillary right and left central incisors. It was reported that the teeth were stored dry and replanted and splinted with fishing line 2 hours after the trauma in an other clinic. In our clinics, calcium hydroxide was placed as a temporary root canal filling material every 3 months until the apex was closed. 6 months later; the radiographic control revealed the bridge formation, the root canal was filled with mineral trioxide aggregate (MTA).

Results: The clinical examination 18 months after the treatment showed that both patient's teeth remained functional and the radiographic examination indicated a slight alteration at the apical part of the roots; however, the patients did not have any complaints.

Conclusion: It is generally advised that all teeth should be replanted, whether storage media was wet or dry. If extra-oral dry time was more than 60 min or the storage medium was non-physiologic, the prognosis of the tooth may be poor. Our cases showed 18months clinically acceptable success after late replantation and the patients are under control.

CONSERVATIVE MANAGEMENT OF ROOT FRACTURED TEETH: A CASE REPORT

Sara Eryuruk, Ayse Sezgi*, Uysal, Serdar, Gungor, H. Cem
Hacettepe University
Faculty of Dentistry Department of Pediatric Dentistry
Ankara, Turkey

Keywords: root fracture, conservative management, healing

Purpose: This case report presents the conservative management of a root fracture injury in a permanent incisor.

Methods & Materials: A 9-year-old girl referred to our clinic after a fall accident occurring 7 days earlier. Clinically, the tooth was slightly mobile and extruded. However, radiographic examination revealed a root fracture of tooth 11 which ruled out an extrusive injury. Due to the elapsed time, a semi-rigid splint was applied between teeth 53 and 63. Along with regular oral hygiene instructions, the patient was recommended a soft diet and rinsing with 0.12% chlorhexidine solution for 10 days. She was also prescribed antibiotics, anti-inflammatory drugs. The splint was removed at the end of the 4th week. The patient was dismissed after scheduling the follow-up visits.

Results: At 24-month visit, the tooth mobility was in normal limits. The tooth crown had normal color and no associated pain was observed in horizontal and vertical percussion tests. The tooth responded positively to the electrical pulp and cold tests. Radiographically, the apical fragment showed continued root development and pulp canal obliteration was evident along the pulp canal in the coronal fragment. The tooth was also assessed by Cone-beam Computed Tomography. As revealed by the Hounsfield units obtained on the scans, the nature of healing between fragments was calcified and connective tissue.

Conclusion: The conservative treatment approach utilizing splinting only lead to uneventful healing in horizontal root fracture.

A RARE CASE OF ROOT FRACTURE IN AN IMMATURE INCISOR

Saroglu Sönmez, Isil*, Erkmen Almaz, Merve, Akbay Oba, Aylin
Adnan Menderes University Faculty of Dentistry, Kirikkale University Faculty of Dentistry
Pediatric Dentistry
Aydin, Turkey

Keywords: root fracture, immature incisor, spontaneous healing

Purpose: Dental trauma resulting root fracture is a rare condition that affects up to 7% of permanent teeth, and injury to immature teeth is even rarer. This case report aimed to show the prognosis of an immature maxillary incisor with horizontal root fracture traumatized at the time of eruption.

Methods & Materials: A 6-year-old boy was referred to our clinic following a fall from a bicycle resulting trauma to the anterior maxilla. In clinical and radiographic examination, it was observed that maxillary left central tooth was displaced and had horizontal root fracture. After local anaesthesia, coronal segment was gently repositioned and dental splint was applied for 7 weeks. The patient was recalled under a regular follow-up regime.

Results: After 15 months, clinical examination showed normal tooth color with a positive response to the pulp test and continuation of root development was observed radiographically. The patient is still being followed up.

Conclusion: It is concluded that fixation of teeth with a splint is a conservative treatment for immature teeth with horizontal root fractures, resulting the pulp vital and spontaneous healing with no treatment.

DELAYED REPLANTATION OF AVULSED TEETH: TWO CASE REPORTS

Savas, Selcuk*, Kucukyilmaz, Ebru; Akcay, Merve; Koseoglu, Serhat
Izmir Katip Celebi University Faculty of Dentistry
Department of Pediatric Dentistry
Izmir, Turkey

Keywords: Tooth Avulsion, Delayed Replantation

Purpose: Tooth avulsion is the complete displacement of a tooth from its socket and its relatively rare (0.5–16%) in the permanent dentition among all dental injuries. Avulsion of teeth most frequently occurs in children aged 7–9 years and the most commonly affected teeth are the maxillary central incisors. The primary goal in treating an avulsed tooth is to preserve and treat the supporting tooth tissues and reimplantation of avulsed teeth. The success of replantation directly depends on extra-oral time, which is a direct correlation of the status of the periodontal ligament cells. Aim: The aim of this report was to present two cases of delayed replantation of avulsed maxillary central incisors after an extended dry extra-alveolar period.

Methods & Materials: Case Report In Case I, an 8 years-old boy presented with an avulsed immature maxillary central incisor due to a trauma occurred 27 hours earlier. The root canal therapy was completed extra orally prior to the placement of the tooth in the socket, because of the extra oral time was more than 27 hours. The socket rinsed with saline and the tooth was replanted slowly with slight digital pressure. The position of the replanted tooth was verified both clinically and radiographically, and stabilized the tooth for 4 weeks using a flexible splint. Prophylactic antibiotic therapy had been prescribed for one week. Clinical and radiographic controls were done after 1, 3, 6, 12 and 18 months. In Case II, a 10 years-old boy had traumatic avulsion of his maxillary central incisor because of falling down accident 7 hours earlier. Treatment guidelines for avulsed permanent teeth with close apex with prolonged extra-oral time were carried out for the tooth and the extra-oral endodontic treatment was completed. The socket was irrigated with sterile physiologic saline, aimed at removing the coagulum present within the alveolus and the tooth was replanted using light pressure. After having been repositioned, the tooth stabilized for 4 weeks using a flexible splint and prophylactic antibiotic had been prescribed. Clinical and radiographic controls were done after 1, 3, 6 and 12 months.

Results: During the follow-up periods the teeth reported in these cases have remained in a stable, functional position but revealed clinical initial replacement resorption and ankylosis.

Conclusion: Despite the extended extra-alveolar dry storage time, the teeth with delayed replantation might be retained for a very long time in a stable and functional position in the dental arch.

MANAGEMENT OF CERVICAL ROOT FRACTURE IN AN IMMATURE PERMANENT TOOTH

Selvi-Kuvvetli, Senem*, Sandalli, Nuket, Bal Kucuk, Burcu
Yeditepe University, Faculty of Dentistry
Department of Pedodontics and Department of Prosthodontics
Istanbul, Turkey

Purpose: The purpose of this case report is to present the treatment of an immature permanent central incisor with a cervical root fracture and the findings of 18 months follow up.

Methods & Materials: An 8 year old boy referred to Yeditepe University Faculty of Dentistry Department of Pedodontics 24 hours after a dental trauma caused by an accidental fall at school. The emergency treatment was carried out in a private office. The medical history of the patient was insignificant. The extraoral examination showed no signs of orofacial injuries. In the intraoral examination the maxillary left central incisor revealed excessive mobility and there was bruising on the interdental papilla. The right central incisor was slightly tender to percussion but did not show any mobility or displacement. The periapical radiograph revealed an oblique root fracture in the cervical one third of the root. The growth and development of the root were uncompleted. A splint with a 7 inch twisted stainless steel wire and composite resin was applied. The pulp sensitivity was tested every four weeks and the splint was removed after 16 weeks. Periapical radiographs were taken 1, 3, 4, 6, 8, 12 and 18 months after the trauma. The root canal showed signs of calcification with a narrowing compared to the adjacent central incisor. The tooth preserved its vitality, however the mobility continued. The patient had a Class II Division 2 occlusion revealing a deep bite. Gnatologic examination showed signs of bruxism. An acrylic occlusal splint with anterior freedom was applied for 3 months, in order to decrease the occlusal forces on the tooth with the root fracture.

Results: The tooth will be periodically followed regarding vitality and root development; however the main criteria for the success of the treatment will be considered as the preservation of the vertical height of the alveolar bone.

Conclusion: Treatment of immature permanent teeth with cervical root fractures is challenging, nevertheless it enables clinicians to maintain pulp vitality and preserve alveolar bone in young patients.

DIAGNOSTIC IMAGING: ERUPTIVE AND MORPHOLOGIC DISTURBANCES IN PERMANENT INCISORS

Sharma, Deepak*
Maharishi Markandeshwar University, M. M. College of Dental Sciences and Research
Pediatric and Preventive Dentistry
Mullana (Ambala), Haryana, India

Purpose: A traumatic dental injury (TDI) to the primary dentition remains one of the common problems affecting children. Two cases of morphological alterations of underlying permanent successors as a consequence of primary tooth trauma are presented. The role of 3-dimensional imaging with conventional diagnostic methods for more definitive diagnosis and treatment planning is highlighted.

Methods & Materials: The patients attended the Out Patient Department of Pediatric and Preventive Dentistry, M. M. College of Dental Sciences and Research, Maharishi Markandeshwar University, Mullana (Ambala) Haryana, India with a chief complaint of an un-erupted upper front tooth. One of the patient was diagnosed by conventional diagnostic methods and the other by 3-D imaging with 128-slice CT scanner (Ingenuity, Phillips, Netherlands) at 120 KV and 100 mAs.

Results: With the advent of multislice computed tomography (CT) and cone beam CT (CBCT) as diagnostic tools, 3-D imaging enabled an accurate, more detailed and faster diagnosis which was helpful for treatment planning in and around the trauma affected developing tooth germ. Disturbance during crown development of underlying permanent successors changed the physical and metabolic environment around the tooth germ and resulted in morphologic alterations and eruption malformations.

Conclusion: With access to advanced imaging, a correct diagnosis was facilitated for implementation of appropriate treatment on the malformed successors. CT showed the location of the defects and the effect on the surrounding tissues and the data acquired during imaging was reformatted to show sequential slices through the permanent successors in axial, coronal and sagittal planes. The same data can further be manipulated to produce 3D reconstruction of the area of trauma giving the dentist a clearer picture of the exact location and behavior of the teeth in question.

TRAUMATIC DISPLACEMENT OF TOOTH INTO NOSE DETECTED TWO YEARS LATER!

**Sockalingam, Ganasalingam
Ministry of Health Malaysia
Johor Bahru, Johor, Malaysia**

Purpose: Introduction Traumatic injuries to teeth are very common in children. When a tooth is avulsed following trauma there is danger that it may be displaced or dislodged into adjacent body spaces. Cases have been reported of teeth being displaced into the lips, nasal cavity, the maxillary antrum, the gut and the lungs. The most serious displacement is if the tooth is aspirated into the lungs.

Methods & Materials: Case report A 12 year old Malay girl was referred by the school dental service to the Paediatric dental department Hospital Sultanah Aminah Johor Bahru for evaluation and management of missing tooth 21. General examination revealed girl was of normal built. She had no medical history of relevance. She however claimed to have occasional foul smelling discharge from left nostril. She had not sought medical attention for this condition. She gave a history of trauma 2 years earlier. She had a bicycle fall and was treated for soft tissue laceration wound on face at a medical clinic. She had been referred to dental clinic but she failed to attend. Extraoral examination revealed symmetrical face. Temporomandibular-joint functions were within normal range. There was a well healed scar on her nose. Intraoral examination revealed clinically missing tooth 21. There was partial closure of space due to drifting of adjacent teeth. Tooth 22 was noted to be rotated 180 degrees with palatal surface facing labially. CBCT examination revealed tooth 21 within nasal cavity. Tooth was horizontal in position anterior –posteriorly with crown being anterior and root lodged between inferior nasal cocha and floor of nose. .

Results: Treatment Treatment plan was to remove displaced 21 and to refer patient for orthodontic alignment to recreate space for prosthetic replacement. Palatal surface of 22 would be built- up with composite to resemble labial surface. Patient was taken to operation theatre and under oral intubation displaced tooth removed with aid using ENT scope. Post- operative recovery was uneventful.

Conclusion: Conclusion This case is unique in that the displaced tooth within the nose was undetected for 2 years. The patient was unaware of its presence. It is important for all health care personnel involved in emergency management of traumatic injuries in the maxillofacial region to carry out thorough examination of teeth. Any missing teeth should be accounted for. If this is not possible it is recommended to take plain radiographs ie OPG and a chest radiograph to rule out displacement of teeth into adjacent anatomical spaces

DELAYED REPLANTATION OF AN AVULSED TOOTH: A CASE REPORT

**Tanyeri, Aliye Tugce*, Tuna-Ince, Elif Bahar ; Gencay, Koray ; Seymen, Figen
Istanbul University, Faculty of Dentistry
Department of Pedodontics
Istanbul, Turkey**

Purpose: Avulsion is one of the common dental injuries that occurs after falling down or traumatic accidents. It is seen mostly in maxillary incisors. Studies have pointed the replantation of avulsed teeth occurs most frequently between 1-4 hours after avulsion and in dry/inadequately wet storage. The aim of this presentation is to report a successful replantation of an avulsed central incisor, which was kept in the milk for 2 ½ hours from the time of trauma until its replantation.

Methods & Materials: 12-year-old male patient was referred to Istanbul University, Faculty of Dentistry, Clinics of Pedodontics after falling down at school. In the intraoral examination, it was noted that, right maxillary central incisor was avulsed and left maxillary central incisor had enamel-dentin fracture. The avulsed tooth was kept in milk and extra-oral time was 2 ½ hours after the accident. Radiographic evaluation showed that, there was no root fracture of the avulsed tooth and bone fracture of the affected region. Socket of avulsed tooth was irrigated with saline and fluoride application was carried out. The position of tooth was controlled and replanted. Subsequently, the tooth was splinted using wire and acid-etch composite resin technique. Gingival lacerations were sutured. Systemic antibiotic was recommended and advices were given to patient and his family. Calcium hydroxide was used as intra canal dressing and 2 weeks later before removal of the splint root canal treatment completed with using with gutta percha points and a resin based sealer. Patient called for routine controls and radiographic findings were recorded.

Results: One-year follow-up showed the intact periodontal ligament and lack of resorption on left central incisor. On radiographic evaluation, it was noted that beginning of replacement resorption has observed on replanted tooth. The tooth was kept in the mouth aesthetically and functionally.

Conclusion: Despite the long extra-oral period of avulsed tooth, a delayed replantation should be considering that when the avulsed tooth was preserved in appropriate storage solution.

CONSERVATIVE MANAGEMENT OF ROOT FRACTURE IN PRIMARY DENTITION

Tekcicek, Meryem*, Erbas Unverdi, Gizem; Turgut, Melek D
Hacettepe University
Pediatric Dentistry
Ankara, Turkey

Keywords: root fracture, primary dentition, splint

Purpose: The case reports describe the clinical management of two root fractured primary incisors.

Methods & Materials: In the first case, a 3-year-old girl was referred to the pediatric dentistry clinic with pain after a fall accident. Radiographic examination revealed a horizontal root fracture on the left primary maxillary central incisor. The tooth was fixed with a semi-rigid splint for four weeks and the patient was scheduled for future recalls. In the second case, a 3.5-year-old boy was referred to the pediatric dentistry clinic after a fall accident. Radiographically, horizontal root fractures in both of the primary maxillary central incisors were detected. The teeth were fixed with a semi-rigid splint for five weeks and the patient was scheduled for future recalls.

Results: After 2 years, no clinical or radiographical pathology were detected in both cases. The mobility of the teeth were in physiologic levels and they uneventfully remained in function.

Conclusion: Maintaining root-fractured primary teeth by splinting may be regarded as a conservative approach in young children as it may eliminate the need for extraction.

MANAGEMENT OF MAXILLARY ALVEOLAR BONE FRACTURE: A CASE REPORT

Tolgay, Ceren Güney*, Çankaya, Abdülkadir Burak, Dogan, Ibrahim, Aren, Gamze
Istanbul University, Faculty of Dentistry
Department of Pediatric Dentistry, Department of Oral and Maxillofacial Surgery, Department of
Prosthodontics
Istanbul, Turkey

Keywords: alveolar fracture, primary incisors, dento-alveolar trauma

Purpose: Alveolar process fractures are particularly complicated by the developing jaws, the presence of tooth germs and the eruption of permanent teeth. This case report describes the management and 24-month follow up of a maxillary alveolar process fracture involving primary incisors.

Methods & Materials: A 4-year-old girl was referred to the clinics of Department of Pediatric Dentistry, Istanbul University, 3 days after a traumatic injury at home. Intraoral and radiographic examination showed fracture and displacement of the maxillary alveolar segment involving right primary incisors. Displaced segment was repositioned manually under local anesthesia and a wire-composite splint was applied for 4 weeks. For the stabilisation of repositioned bone, a vacuum-formed splint was also used for 1 week. Instructions were given on oral hygiene maintenance and nutrition. 18 months later, discoloration and periapical abscess was observed on maxillary right primary central incisor and root canal treatment was performed. Few weeks after the treatment, the girl suffered another dental trauma resulting in a complicated crown fracture of the maxillary right primary central incisor and extraction of the incisor was performed.

Results: At 24-month-follow-up no symptoms were observed based on clinical and radiographic findings.

Conclusion: Injuries to the primary dentition involving alveolar fracture are especially important because of the potential complications related to eruption of the permanent incisors and alveolar development.

MULTIDISCIPLINARY MANAGEMENT OF A CERVICAL ROOT FRACTURE: A CASE REPORT

Tonguc Altin, Kubra*, Nur, Rahime Burcu, Duygu, Gonca, Canpolat, Ceyhun, Sungurtekin Ekci, Elif, Sandalli Nuket

Yeditepe University, Faculty of Dentistry

Department of Pediatric Dentistry, Orthodontics, Oral and Maxillofacial Surgery, Prosthodontics
Istanbul, Turkey

Purpose: The aim of this case report was to present the multidisciplinary management of a subgingivally fractured permanent maxillary left central incisor including endodontic treatment, surgical exposure, orthodontic extrusion and prosthetic rehabilitation.

Methods & Materials: A 13-year-old boy was referred to the Pediatric Dentistry Department of Yeditepe University, Faculty of Dentistry, Istanbul, Turkey, with a chief complaint of a subgingivally fractured permanent maxillary left central incisor as a result of a swimming pool accident one week before admission. A local dentist had eliminated the coronal fragment and made a wire splint to the adjacent teeth. Following a thorough clinical and radiological examination, a multidisciplinary intervention involving pediatric dentistry, orthodontics, surgery and prosthodontics was planned. Accordingly, the tooth was extruded orthodontically with the help of surgical exposure followed by the root canal treatment. Then a glass fiber post retained prosthetic crown was fabricated. The patient was scheduled for follow up.

Results: The follow-up course was uneventful. There was no radiographical evidence of periapical pathology, and the tooth presented satisfactory esthetic and functional outcomes.

Conclusion: Multidisciplinary approach to the management of cervical root fractures may improve prognosis as well as functional (mastication and speech) and esthetic aspects in a growing child.

ALVEOLAR PROCESS FRACTURE IN MANDIBULAR IMMATURE PERMANENT INCISORS REGION

Tüzüner, Tamer*, Yahyaoglu, Gorkem Tosun, Emre Taskesen, Fatih Kusgoz, Adem
Karadeniz Technical University
Pediatric Dentistry
Trabzon, Turkey

Purpose: Alveolar process fractures are particularly complicated by the developing jaws, the presence of tooth germs and the eruption of permanent teeth. This case report describes the treatment of alveolar fracture associated with mandibular immature lower permanent incisors.

Methods & Materials: An eight year-old girl with mandibular fracture associated with lower immature permanent incisor teeth was referred to Karadeniz Technical University, Faculty of Dentistry, Department of Pediatric Dentistry after the 3 hours of trauma. Splinting of alveolar fracture was achieved for 4 weeks with arch bars and followed up 24 months.

Results: After 24 months followed up period, the mandibular permanent incisors were observed as vital with the apical closures.

Conclusion: Treatment of alveolar fractures in growing population with immature teeth may provide beneficial healing pattern with careful splinting and follow up procedures.

LOCALISED GINGIVAL RECESSION CAUSED BY TRAUMATIC CROSSBITE: A CASE REPORT

Tzifa, Vasiliki*, Duman, Canan Menten, Ali
Marmara University
Pediatric Dentistry
Istanbul, Turkey

Purpose: Gingival recession is displacement of the soft tissue margin apically leading to root surface exposure. Occlusal trauma is defined as injury resulting in tissue changes within the attachment apparatus as a result of occlusal forces by moving of the incisors out of the osseous envelope. Malocclusion and abnormal tooth position are vastly recognized as potential contributors to the disease process when they cause occlusal traumatism. In the following case we present the clinical and radiological findings and the correction with orthodontic treatment of a severe gingival recession in a case with traumatic occlusion.

Methods & Materials: This case report presents the case of a 9-year-old female patient that was referred to Marmara University Faculty of Dentistry, with the chief complain of pain and sensitivity at the area of lower incisors and of the position of the left lower central incisor. The clinical evaluation revealed extensive gingival recession on the vestibule of left mandibular lateral incisor, not adequate oral hygiene, anterior dental crossbite between the central left upper and lower incisor and proclination of the lower incisor. The treatment of choice was to intervent orthodontically in order to improve the anatomic and functional environment both for correct the malocclusion and limit the periodontal recession. A removable Hawley appliance with posterior bite plane and finger springs was designed and used by the patient until the total correction of the malocclusion and regaining the loss in the gingival attachment .

Results: The malocclusion was corrected within two months and after 6 months the gingival attachment was regained at acceptable clinical levels. After 8 months the appliance was discarded. Overall, the patient was motivated to maintain good oral hygiene and recalled frequently for evaluate the treatment progress and periodontal health of the anterior teeth. After one year the result was the total correction of the malocclusion with an acceptable correction of the depth of the gingival margin of the lower incisor.

Conclusion: In conclusion, at present, there is a consensus that trauma from occlusion may be a co-destructive factor in periodontal destruction, especially affecting the supporting alveolar bone. Nevertheless, opinions are divided on its role in affecting the periodontal attachment, i.e., marginal gingival tissues. The early orthodontic intervention is of great importance in order to avoid a more complicated orthodontic and periodontal treatment at later phases. Further studies are warranted to explore the role of trauma from occlusion on the development of gingival recession.

MANAGEMENT OF A COMPLEX DENTAL TRAUMA IN A PAEDIATRIC PATIENT

Ulug, Sermin Dicle*, Guven Yeliz, Gencay Koray, Aktoren Oya
Istanbul University
Pediatric Dentistry
Istanbul, Turkey

Keywords: dental trauma, paediatric patient

Purpose: This case report describes the management and 24-month follow-up of a paediatric trauma patient presented with a complex dentoalveolar trauma involving avulsion, intrusion, root fracture, lateral luxation and subluxation injuries of multiple teeth.

Methods & Materials: A 9-year-old boy was referred to the Department of Pediatric Dentistry, Istanbul University with a history of bicycle accident. The patient was physically healthy and had no remarkable medical history. Intraoral examination displayed avulsion of teeth 21 and 63, complete intrusion of tooth 22, subluxation of tooth 41 and 42, lateral luxation of teeth 31 and 32 and root fracture of tooth 33 with the coronal part missing. The avulsed central incisor could not be found by the parents. The treatment included orthodontic extrusion of the intruded maxillary lateral incisor and orthodontic repositioning of lingually displaced mandibular incisors. The apical part of the root fractured mandibular canine was restored with fiber post and strip crown after gingivectomy procedure and apexification with MTA. A maxillary Hawley-type retainer with a pontic to replace the missing tooth 21 was inserted for space maintenance and esthetics during transition of the dentition.

Results: 24 month follow-up of the patient revealed no pathological clinical and radiographic signs.

Conclusion: Optimal interdisciplinary treatments in the management of a complex dental trauma in mixed dentition has great importance for maintaining the functional, esthetic, phonetic and psychological rehabilitation. Furthermore, orthodontic splinting should to be considered as a choice for managing severe dental trauma in paediatric patients.

A CONSERVATIVE TREATMENT APPROACH TO SUBCONDYLAR FRACTURE

Uyanlar, Ayhan*, Ulkur F
Yeditepe University, Faculty of Dentistry
Orthodontics Department
Istanbul, Turkey

Purpose: The aim of this case report is to show occlusal splint therapy as a treatment option for subcondylar fracture.

Methods & Materials: A 22 year old male patient with history of trauma on his left condyle was referred to our clinic. His chin was deviated 2 mm to left side and there was an openbite on the right side due to the lateral shift of mandible. The purpose of the treatment was to release the head of condyle from compression and achieve a symmetric condyle position. Upper and lower dental arches were bonded with special consideration of not changing the original position of the teeth. The left condyle was repositioned to fabricate interocclusal splint at the same time bite registration was taken with the blue wax when the upper and lower midlines were coincident. During this process, panoramic radiographs were used to control the position of the fractured segment. Rigid intermaxillary fixation along with intermaxillary elastics was applied for 6 weeks.

Results: After splint therapy, a good occlusal relationship and satisfactory mouth opening were achieved. Panoramic radiograph analysis demonstrated that the symmetry of condylar position is restored. However, the mandible shifted lightly towards the affected site during wide opening of the mouth.

Conclusion: Due to close proximity of the fracture site to the parotid gland and facial nerves, conservative method as rigid inter-maxillary fixation can be considered as a treatment option of top priority in subcondylar mandibular fracture cases.

AVULSION INJURIES IN THE PERMANENT DENTITION: SEQUELAE AND MANAGEMENT

Wong, Susan Su Ee*, King, Nigel; Anthonappa, Robert
University of Western Australia
Paediatric Dentistry
Perth, Australia

Keywords: Avulsion, Permanent teeth, Management

Purpose: To report the sequelae and management of avulsion injuries to the permanent dentition in two patients.

Methods & Materials: Case 1: An 8 year old girl presented with an avulsed 11 which had an extra-oral dry time of 30 minutes and then stored in milk (70 minutes) and Hanks balanced salt solution (30 minutes) prior to reimplantation. No endodontic treatment was initiated and the tooth was splinted with a 018 Stainless Steel (SS) for three weeks.

Subsequently tooth 11 exhibited severe external inflammatory root resorption and exfoliated five months post trauma. A resin bonded bridge was cemented as an interim measure and the patient is to undergo a premolar autotransplantation in due course. Case 2: A 12 year old girl presented with an avulsed tooth 11. Tooth 11 was first stored immediately in milk and then in hanks balanced salt solution for a total of six hours prior to reimplantation. Endodontic treatment was initiated with ledermix as an intracanal medicament on tooth 11. It was then splinted with a 016SS wire for four weeks. Two weeks after splint removal, tooth 11 exhibited an increase in mobility, hence it was re-splinted with a 016SS wire for an additional six weeks. Nevertheless tooth 11 did not stabilise, therefore the tooth was extracted. Subsequently, a suspension bridge was fabricated as an interim measure.

Results: Despite the efforts to maintain the tooth in the oral cavity, the reported cases exhibited unfavourable outcomes.

Conclusion: The treatment outcomes for avulsion injuries in the permanent dentition are not always favourable despite following published trauma management guidelines. Therefore, clinicians should be aware of the potential complications and its appropriate management both in the short- and long- term.

DECORONATION OF AN UPPER CENTRAL TOOTH IN A GROWING PATIENT

Yahyaoglu, Gorkem*, Baygin, Ozgul Korkmaz, Yavuz Tolga Tüzüner, Tamer
Karadeniz Technical University
Pediatric Dentistry
Trabzon, Turkey

Purpose: Decoronation is a surgical method for treating ankylosed incisors in children and adolescents. This method can be applied prior to prosthetic treatment for preserving the alveolar bone wide and height. The aim of this case is to present the preservation of the alveolar ridge for implant rehabilitation by utilizing decoronation technique for replanted tooth which exhibited replacement resorption and ankylosis.

Methods & Materials: Fifteen year-old boy was referred to Karadeniz Technical University, Faculty of Dentistry, Department of Pediatric Dentistry with complaints of the pain. The clinical and radiographic examination, revealed replacement resorption and ankylosis in avulsed right upper central incisor tooth which was reimplanted 3 years ago. This case report is presented a 24 month follow-up of decoronation technique for providing the alveolar width and height patient who can become candidate for implant at 18 years old.

Results: Twenty four months follow-up period of decoronation technique didn't show any infection by managing the alveolar bone ridge wide and height.

Conclusion: We conclude that the treatment of replacement resorption and ankylosed young permanent incisor by decoronation technique may manage the alveolar bone ridge width, height and continuity, and facilitate future rehabilitation with minimal, if any, ridge augmentation procedures for growing patients.

REVASCULARIZATION OF IMMATURE NECROTIC PERMANENT MAXILLARY INCISORS: FIVE CASE REPORTS

Yaman-Dosdogru, Elif *, Gorken, Feyza Nur; Erdem, Arzu Pinar; Sepet, Elif; Aytepe, Zeynep
Istanbul University, Faculty of Dentistry
Department of Pediatric Dentistry
Istanbul, Turkey

Purpose: Traumatic injuries to an immature permanent tooth may result in cessation of dentin deposition and root maturation. Endodontic treatment is often complicated in premature tooth with an uncertain prognosis. The present case series demonstrates the follow-up of revascularization treatment in immature necrotic maxillary central incisors prior to trauma.

Methods & Materials: The radiographic examinations showed immature roots with radiolucent lesions adjacent to the central incisors. Immature necrotic permanent maxillary incisors (n = 5) of patients 7-9 years old were treated by a revascularization protocol that used 20 ml NaOCl and 10 ml chlorhexidine irrigation, medication with a creamy mixture of equal proportions of ciprofloxacin, metronidazole and minocycline, as described by Hoshino et al. Antimicrobial therapy was repeated, if clinical symptoms were present. Induction of apical bleeding was performed with overinstrumentation. A blood clot formed in the canals and white mineral trioxide aggregate was applied over the blood clot. The access cavities were sealed with glass-ionomer cement followed by an adhesive composite-resin filling. These immature permanent teeth were followed up from 1, 3, 12 and 18 months for three patients and 22 months for one patient.

Results: Among the treated teeth, three incisors had regained vitality. No pain, mobility, swelling and sensitivity to percussion were detected in the treated teeth. Discoloration was observed in three teeth. After a follow-up period of 18-22 months, all teeth demonstrated radiographic evidence of complete periapical healing. Slight thickening of dentinal walls were seen in the radiographic controls. A hard tissue barrier formed in the canal below the coronal MTA plug in one teeth.

Conclusion: On the basis of a follow-up period, the present cases demonstrate resolution of the symptoms and regaining vitality in three teeth. Although the radiographic controls don't demonstrate a favorable outcome, long term follow-ups should be organised to observe apical developments and to propose revascularization as a treatment alternative.

TREATMENTS OF AVULSED AND INTRUDED TEETH

Yildirim, Ceren*, Akgun, Ozlem Marti; Acar, Ozge; Guven Polat, Günseli; Basak, Feridun
Gülhane Medical Academy
Department of Pediatric Dentistry
Ankara, Turkey

Purpose: The purpose of this case report is to present the treatment of 8-year-old male patient with avulsion, intrusion and crown fracture.

Methods & Materials: A 8-year-old male patient presented to the Pediatric Dentistry Department with a history of dental trauma to the maxillary anterior teeth owing to a bicycle accident 1 month earlier. His right permanent maxillary incisor was avulsed and left permanent incisor was intruded. After the accident the patient had admitted to a dental clinic immediately and avulsed tooth was splinted with a non-suitable rigid splint. Findings of radiographic examination revealed the teeth had open apices and the avulsed tooth was not inserted in its socket correctly. The teeth were re-splinted with semi-rigid splint, the crown fracture of avulsed tooth was restored and the patient was followed for 18 months. During a follow-up examination at 18 months the left permanent incisor totally erupted, there were no periapical lesions around the roots of the teeth and the root developments were continuing. At 2 years follow-up examination a periapical lesion was determined around the root of right permanent incisor. Triple antibiotic paste was inserted to the canal and after one month the root was filled with plasma rich protein and MTA.

Results: The patient was followed-up for 6 and 12 months postoperatively. Six months after endodontic treatment, radiographic examination revealed healed periapical lesion.

Conclusion: Long-term follow-up of patients with dental trauma is essential for the success of clinical treatment. In addition, pathological changes may occur several years following the accident. In the present case, a periapical lesion was observed around the root of avulsed tooth after 2 years.

TREATMENT OF HORIZONTAL ROOT FRACTURE USING FIBER-REINFORCED POST

Yildirim, Sinem*, Elbay Sermet, Ülkü* Tak, Öñjen*
Kocaeli University
Pediatric Dentistry
Istanbul, Turkey

Purpose: The purpose of this presentation is to report a case that shows the multidisciplinary approach required to successfully manage the rehabilitation of a maxillary central incisor with a crown fracture and a horizontal root fracture.

Methods & Materials: In this case presentation, a 12 years old boy with no contributing medical history was referred to Kocaeli University's Faculty of Dentistry Department of Pediatric Dentistry clinic one year after a traumatic injury. After clinical and radiological examination, a crown fracture and a horizontal radicular fracture located in the middle-third of an upper right central incisors was observed. It is determined that the upper right incisor completed root development. An intentional root treatment was carried out for placement of an intra-radicular fiber post, nearly 3 mm beyond the fracture line. The tooth was restored with bonding system and composite resin.

Results: Patient was recalled after a month and six months. On examination, upper right central incisors was found to be asymptomatic with satisfactory aesthetics. Periodontal status was good. No pain symptoms, color changes, mobility or periradicular pathology were observed on the restored teeth.

Conclusion: Root fractures in permanent teeth are uncommon injuries among dental traumas, being only 0.5-7% of the cases. Fracture occurs often in the middle-third of the root and rarely at the apical-third. The prognosis of root fractures depends on the extent of the fracture line, the pulp tissue situation, occlusion, dislocation of fragments and the general health of the patient. A functional and aesthetic outcome following treatment is achieved by a combined therapy, including restorative, endodontic, prosthodontic, periodontal and orthodontic therapies. A regular follow-up of teeth is required to evaluate the success of treatment and to do the necessary alterations in the suggested treatment protocol, if indicated.

PROGNOSIS OF LUXATIVE TRAUMATISED IMMATURE TEETH- 20 MONTHS FOLLOW-UP

Yılmaz, Duygu*, Ünsal, Gülcan* ; Ulukapi, Isin**
University of Istanbul* University of Okan**
Pediatric Dentistry
Istanbul, Turkey

Keywords: Dental trauma, lateral luxation, extrusive luxation

Purpose: Extrusive tooth luxation is a type of dental injury that involves displacement of the tooth out of the alveolar socket, tear apart some part of periodontal ligament and show some cracks of alveolar socket. Lateral luxation is displacement of tooth through palatal or buccal direction that affects periodontal tissues and pulpal blood circulation. Despite high risk of pulp necrosis of the teeth confronted with severe lateral or extrusive luxation, some case reports show that there is a possibility that immature teeth with open apexes has a chance to stay vital. This case report presents treatment of luxative traumatized two immature maxillary central incisors.

Methods & Materials: An 6-year-old girl was referred to Istanbul University, Department of Pediatric Dentistry for dental trauma as a result of fall at the school after 5 days of the trauma. She went to a general dentist 2 hours after the trauma, any treatment could have got cause of lack of cooperation. She did not have any systemic medical problem. Clinical and radiographic examinations revealed severe extrusion of immature right maxillary central incisor with mobility and mild lateral luxation of left maxillary central incisor. Teeth were replaced as possible under the local anesthesia and were stabilized with semi-rigid splint for 3 weeks.

Results: Despite of negative response to ice test and EPT (electricity pulp test), she had got any root canal treatment because traumatized teeth were immature and they had no fistulas or pathological luxation symptom. It was observed that after 5 months of the trauma teeth had positive response to vitality tests and after 2 years of observation period they kept continue to their root developments.

Conclusion: This case report shows that traumatized immature teeth which had lateral luxation or extrusive luxation and reposed in late phase of trauma have a possibility of keeping vitality after a long term observation period.

DECORONATION OF A TOOTH WITH ROOT FRACTURE: A CASE REPORT

Yoldas, Selen Esin*, Küçükkurt, Sercan, Bodur, Haluk
Gazi University Faculty of Dentistry
Pediatric Dentistry
Ankara, Turkey

Keywords: decoronation, root fracture, dental trauma

Purpose: Dental trauma can seriously affect a patient's life by causing early loss of permanent teeth. In such cases, replacement of missing teeth could be possible with traditional approaches. However traditional approaches would lead to loss of alveolar ridge which would reduce the chance of the patient to receive an aesthetic and consistent treatment. To avoid this situation decoronation procedure would be a good alternative which includes the removal of the crown and leaving the root fragment in the alveolar socket following the closure of the area with a mucoperiosteal flap.

Methods & Materials: A 10 year old patient with a horizontal fracture in the cervical third of #11, and an oblique fracture in the middle third of #21 referred to Gazi University Department of Pediatric Dentistry. The completion of the root canal treatment following fiber post and composite-resin restoration were performed for #11. Furthermore, apical resection of the apical fragment of #21 and decoronation procedure for the coronal fragment of the root carried out subsequent to the application of a removable denture for replacement of the crown.

Results: At the 18th month follow up, the teeth were clinically asymptomatic. Radiographic evaluation revealed that alveolar bone level of #21 was satisfactory.

Conclusion: It can be concluded that, decoronation procedure would be a good option for appropriate trauma cases in order to avoid undesired alveolar bone loss.

Research Posters- Pediatrics and Orthodontics**DENTAL TREATMENT EVALUATION PERFORMED UNDER GENERAL ANESTHESIA IN CHILDREN**

Al-Alloush, Abdulaziz*, Moussa, Shady
Zagazig University
Zagazig, Sharkia, Egypt

Purpose: This retrospective study evaluated different dental treatment modalities operated under general anesthesia and compared the performed treatments in normal and special needs children.

Methods & Materials: The data was collected from Pediatric Dentistry Unit at King Saud Hospital, Onaizah. All patients less than 15 years old who were operated for dental treatments under general anesthesia (G.A) from September, 2008 to December, 2013 were divided into 2 groups. The normal patients were assigned to group (μ) and special needs patients who had any type of mental, physical or medical disability were assigned to group (β) The treatment modalities such as teeth restoration, pulp therapy, stainless steel crowns capping, fissure sealant application and extraction were compared and statically analyzed by t-test, using (SPSS22,program).

Results: A total of 756 patients were treated under G.A, 641 patients were included in group μ and 115 patients were assigned to group β . Most patients in group β were mentally disabled. The major underlying problems were diabetic 13%, renal failure 3.5%, and cardiac 6%, mental retardation, 38.3%, autism 7.8%, cerebral palsy 20%, developmental delays 2.6% and epilepsy 8.7%. There were insignificant differences in ages, sex and total number of treated teeth in both groups, $p > 0.001$. 59% of group μ and 40.9% of group β were younger than 6 years old their mean of extracted teeth was significantly greater in group β and there was a significant increase of restored teeth and sealant procedures in group μ , there also were significant increases in using crowns and pulp therapies performed in group β , $P < 0.05$ where the children less than 6 years old. However, 41% of group μ and 59.1% of group β were larger than 6 years old showed a significant increase in teeth extraction in group β . On the other side, there were insignificant differences in teeth restoration and sealant procedures between two groups $P > 0.05$ where the children larger than 6 years but there were more stainless steel crowns reconstruction and pulp therapies performed in group μ .

Conclusion: Dental treatment for special needs and very young children under G.A was essential as well as safe and efficient. Also, performed treatment modalities were affected specially by mental, medical and physical disability conditions who needed simple procedure with minimal complication, as the greater number of permanent teeth that needed to be treated, the more complicated it was to complete one session in G.A, therefore, extraction was chosen as an alternative treatment.

REATTACHMENT OF CORONAL FRACTURES: THE NATURAL RESTORATION

Çiftçi, Zülfikar Zahit*, Kirzioglu, Zuhai
Süleyman Demirel University, Faculty of Dentistry
Department of Pedodontics
Isparta, Turkey

Purpose: It was aimed to evaluate the restoration of fractured teeth by reattaching the tooth fragment to its own tooth remnant according to age and dentition in a group of children and young adults clinically.

Methods & Materials: This study was conducted on 50 patients who were referred to our clinic with complaint of crown fracture due to trauma and with their own fractured fragment. The teeth and its surrounding tissues were evaluated clinically and radiographically. The broken incisal part was reattached directly or after the necessary treatments according to simple or complicated crown fracture. After the treatment period the teeth were evaluated clinically and radiographically. In the current study; children's and their parents' opinions on pre- and post-treatment period were evaluated.

Results: The current study was consisted of 55 restored teeth of 50 traumatized children, between 7-16 (mean 10.5±2.3) years old. All of the traumatized teeth were maxillary central incisor. 71.8% of children were at mixed dentition and 44.4% of teeth had incomplete root formation. No significant relationship was found between in this respect and simple or complicated crown fracture with gender ($p>0.05$). 22% of teeth were treated with cvek pulpotomy due to pulpal exposure. Teeth could evaluate for 2.7±1.82 years (min=1, max=8 year). At control examinations, all of the teeth were vital, had closed root apex, which had incomplete root formation during the trauma and no color disharmony was observed. It was detected that, 10,3% of reattached tooth fragment had fallen during the follow up time. As one of the factors in restoration failure is re-exposure of the patients to trauma two or more times (33,3%). 29,9 % of patient didn't come for control, thus it was observed that long-term follow-up is quite difficult. During the 8 years follow up, proportion of patients who came the routine control trials decreased two years intervals; 94.8%, 35.8%, 17.9% and 5.1% respectively.

Conclusion: It was determined that, success rates of restored teeth with own tooth fragment and the degree of satisfaction were high. The majority of patients were in mixed dentition phase and about half of traumatized teeth had incomplete root formation. It was observed that, patient follow-up was difficult in trauma cases and the number of patients who were controlled have decreased in time. 1/3 of these traumatized children have undergone trauma again, thus restoration of teeth by reattaching own tooth fragment is suitable treatment option for this age group.

WHAT SHOULD BE DO OR NOT DO IN ROOTS FRACTURE

Kirzioglu, Zuhai*, Gök, Begüm; Tasa, Tugba
Faculty of Dentistry, University of Süleyman Demirel
Department of Pediatric Dentistry
Isparta, Turkey

Keywords: Root Fracture, Canal treatment, Periradicular Healing

Purpose: Children and young patients with roots fracture caused by trauma and patient-related factors that are applied to the type of treatment and the healing relationship is important. The purpose of this study is to try to find an answer if all children and young patients with root fractures are need to be treated or should be followed by a retrospective analysis.

Methods & Materials: The study was conducted using records and radiographs of 63 patients with root fractured teeth. This study assessed gender, cause of injury and duration of application, number of teeth affected, fracture type, affected adjacent teeth, splinting periods and various treatment methods on periradicular healing of root fractures in a group of patients.

Results: There were 73 root-fractured teeth in 63 patients (73% male and 27 % female) aged between 7-17 years. The commonest cause of injury was a fall at home or school (52%), followed by bicycle and traffic accidents, and motorcycle accidents. Only 13% of patients were seen on the day of the trauma. One root-fracture occurred in 86 % of patients and 14% of patients had two root-fractured teeth; trauma was seen in the upper jaw of 95% of patients. The most affected teeth were central, followed by lateral incisors. 73% of all root-fractured teeth had completed the development of the root. Root fractures were classified radiologically as; coronal 22%, 44% middle and 34% apical according to location. The most common type of fracture was transverse (92%). 16% of patients had no follow up treatment. 17% of patients had root canal treatment, 24% of treated patients had teeth extracted.

Conclusion: Compared to the other form of interventions, splinting and root canal treatment is significantly more succesful for the healing of root fractures. A delay in treatment and granulation formation between fragments lead to failure in treatment. Followed up of the patients with no intervention may be considered in the presence of factors including development of the roots, the position of the fragments and timing of the treatment.

DETERMINATION OF WORKING LENGTH FOR PRIMARY TEETH WITH DIFFERENT METHODS

Kizilci, Esra*, Gorgen, Veli Alper* Gulsum, Duruk* Yologlu, Saim**

*Inonu University

*Department of Pediatric Dentistry **Medical Informatic Department
Malatya, Turkey

Keywords: primary teeth, root resorption, visual and tactile method

Purpose: The determination of root canal working length is a critical step during root canal treatment in primary teeth due to possible damage to the permanent successor tooth germ. The aim of this in vitro study was to determine the working length of root canals with 3 different methods in primary incisor and molar teeth with or without resorption.

Methods & Materials: Thirty four extracted primary teeth with 64 root canals were used in this study. Teeth divided into four groups; Group A: primary incisors with resorption, Group B: primary incisors without resorption, Group C: primary molars with resorption; Group D: primary molars without resorption. Root canal lengths were measured with visual, tactile sense, digital radiographic method and an electronic apex locator (Root ZX mini). The Pearson Chi – Square test was applied for statistical analysis.

Results: The mean values were recorded according to ± 0.5 and ± 1 mm tolerance ranges. The results showed that no statistically significant difference were found between canal lengths obtained by digital radiographic method and electronic apex locator compared with the visual method, when the tolerance ranges was 0.5 and 1mm ($p > 0.05$). For the two methods compared with the visual method, no significant differences were found between group A, B, C, D ($p > 0.05$). Statistically significant differences were found between the visual method and tactile sense ($p < 0.05$).

Conclusion: Digital radiographic method and electronic apex locators are an accurate methods and that tooth type, canal, and apex with or without resorption did not alter the methods accuracy. But the tactile sense were not accurate for determining the working length in primary teeth.

CURRENT TRENDS IN PRIMARY TOOTH PULPOTOMY AMONGST DENTISTS IN KARACHI

Lone, Maham*, Khan, Farhan Raza; Lone, Muneeb Ahmed

Aga Khan University Hospital

Section of Operative Dentistry; Department of Surgery
Karachi, Sindh, Pakistan

Keywords: Pediatric dentistry, pulpotomy, dental practice

Purpose: 1. To assess practice regarding pulpotomy of primary teeth among dentists of Karachi, Pakistan. 2. To compare the difference in pulpotomy techniques of primary teeth between private practitioners and teaching dentists.

Methods & Materials: A questionnaire was distributed to dentists working in private clinics and teaching hospitals of Karachi, who were involved in treating primary teeth of children. The questions gained information on aspects like: use of radiographs for pretreatment evaluation, use of anesthesia and rubber dam, choice of material for pulpotomy procedures, restorative material of choice after pulpotomy in pediatric patients etc. Descriptive statistics & frequency distribution were computed. Chi-square test was applied to compare difference between dentists working in teaching hospitals versus those working in private practices. Level of significance was kept at 0.05.

Results: • Majority of dentists routinely used preoperative radiograph for assessment of carious teeth before pulpotomy procedure. • Formocresol- preferred material for pulpotomy by dentists in both groups. • A very high percentage of practitioners in both groups never used a rubber dam. • A very small number of dentists used stainless steel crown for definitive restoration of primary molar after pulpotomy of the tooth. • There is a statistically significant difference between dentists in their use of local anesthesia before a pulpotomy procedure and in their choice of restoration of anterior teeth post pulpotomy.

Conclusion: • Majority of dentists use the preferred medicament for pulpotomy i.e. formocresol, • Only 23-26% dentists placed stainless steel crown after pulpotomy which falls far below standard of care set in academics. • A large proportion of teaching dentists used local anesthesia (53.8%) for pulpotomy compared to private practitioners (33.3%).

EVALUATION OF DIFFERENT ROOT CANAL FILLING METHODS IN PRIMARY TEETH

Ozer, Sezin*, Sen Tunc, Emine; Kalyoncuoglu, Elif; Gulcan, Banu
Ondokuz Mayıs University
Pediatric Dentistry
Samsun, Turkey

Purpose: To compare the efficacy of five different root canal filling methods in primary anterior teeth via digital radiography.

Methods & Materials: A total of 50 extracted primary anterior teeth were prepared using Mtwo rotary instruments to a standard apical file size. Teeth were randomly divided into 5 groups and filled with metapex (Meta Dental Corp Ltd., Elmburt) by using its own syringe (Group 1); own syringe and endoactivator (Group 2); own syringe and ultrasonic activation (Group 3); endodontic syringe (Group 4) and lentulo spiral (Group 5). The canals were evaluated in photostimulated phosphor radiographs for the length of filling (underfilled, optimally filled, and overfilled) and the presence, localization and the sum of void sizes. Data were statistically analysed using Kruskal-Wallis and Bonferroni corrected Mann-Whitney U tests.

Results: There were statistically significant differences between the length of filling and sum of void sizes for all groups and the worst results were seen in endodontic syringe group ($p < 0,001$).

Conclusion: Based on the results of this in vitro study it can be concluded that all of the methods have similar performance when using metapex as root canal sealer in primary teeth except endodontic syringe method. So, endodontic syringe method may not be suitable for primary teeth root canal filling.

DENTAL DESENSITIZATION PROTOCOL IN AUTISTIC CHILDREN OF PUERTO RICO

Pagan, Elaine*, Aymat, Noel* Martinez-Godas, Natalia*
University of Puerto Rico School of Dental Medicine
Pediatric Dentistry Program
San Juan, Puerto Rico

Keywords: dental, desensitization, autism

Purpose: This is a case series study that was intended to evaluate if a dental desensitization protocol increases the cooperation level of children with autism in the dental clinic setting.

Methods & Materials: Ten participants with Autism disorder participated and were referred by their psychologist. Desensitization sessions were conducted at the University of Puerto Rico, School of Dental Medicine. The protocol consisted of four stages, a first stage before the dental visit and three other stages in the dental scenario. The period for this procedure was from two to four visits: a minimum of two visits (one visit with the psychologist of 1 hour and another visit in the dental clinic of 1.5 hours). Every patient had to complete the four stages in order to successfully finish the desensitization protocol. Scoring of behavior using the Frankl Behavior Rating Scale from 0 being definitely negative to 3 being definitely positive was done. Statistical analysis was based on descriptive statistics.

Results: A group of 9 females and 1 male, age range 5-13 years old were treated. 7 patients completed the dental stage of the protocol in one visit, 0 in two visits, 1 in three visits and 2 did not complete the protocol. Scores ranged from 1.78 to 2.94 with an average of 2.29. 8 of 10 patients completed the protocol successfully.

Conclusion: The study suggests that the dental desensitization protocol worked successfully for autistic children independently of having previous negative dental experiences. The importance of having a structured plan and adequate approach by professionals to work the resistance of children during initial exposition and participation stages was established. Further studies will be needed to represent a larger portion of the Autistic population in Puerto Rico.

THE APPLICATION PERIOD ACCORDING TO THE TYPE OF PRIMARY DENTITION

Ulu Guzel, K. Görkem*, Kirzioglu, Zuhul, Gok, Begüm
Faculty of Dentistry, University of Adnan Menderes
Department of Pediatric Dentistry
Aydin, Turkey

Purpose: Trauma to the primary dentition is a common dental health problem in childhood, producing a substantial impact on children's quality of life. The prognosis of dental trauma cases varies depending on the time elapsed after the trauma before treatment started. The aim of this study was to investigate the epidemiological and dental data from traumatic injuries to primary teeth.

Methods & Materials: The records of 281 children were examined registered for traumatic primary teeth injuries at a pediatric dental clinic of Süleyman Demirel University, Faculty of Dentistry during thirteen year period (January 2001-December 2013). The information about age, sex distributions, time, causes of the injury, the time elapsed between injury and treatment recorded on standardized questionnaire forms.

Results: The dental trauma records of patients with an average age of 3,3 years and the 1 and 3 year old age groups were the most affected to the dental injury. 177 boys (62.9%) and 104 girls (37.1%), were evaluated on standardized questionnaire forms. The period elapsed between trauma and time of seeking dental care ranged from the same day to over a year. The most patients [146 patients (51.9%)] were referred to the clinic within same day following the injury and the most referred reason in the patients was luxation. The main cause of injury was falls (33.09%).

Conclusion: The immediate treatment after dental trauma is an important factor that affects the prognosis of traumatized teeth. It is important to inform the parents about dental trauma and the importance of bringing their children fast to a dentist in trauma cases.

Case Posters- Prevention and Sports Dentistry

TEMPOROMANDIBULAR DISORDERS IN BOXING ATHLETES

Montero Parrilla, José Miguel*, Pichardo Pérez, Jorge Ernesto. Valdés Reyes, José Manuel

Faculty of Dentistry Havana, Cuba

Prosthodontics

Havana, Cuba

Purpose: Boxing is a combat sport and amateur boxers have the potential to suffer significant traumatic injuries in the Temporomandibular Joint. Sports Dentistry is one of the most recent and upcoming field in dentistry, and has the responsibility of offering all boxers a comprehensive care. The purpose of this study was to identify the presence of Temporomandibular Disorders in boxing athletes.

Methods & Materials: An observational-descriptive, cross-sectional study was accomplished in 30 athletes of the Boxing Cuban High Performance School "Manuel Permuiz", in the period understood from March to July of 2013. To identify de clinic signs and sintoms of Temporomandibular Disorders the Krogh-Paulsen Test was employed.

Results: Joint sounds (30%) and sideslip during occlusion (26.6%) were the most common signs and symptoms identified. Boxers that had been practicing the sport during 6 to 10 years had bigger affectations. All of them used mouthguard during both competitions and practices, but only two had a custom-made mouthguard. 56.6% of the boxers were diagnosed with dysfunction according to the Krogh-Paulsen Test. Both morphologic and functional occlusal alterations predominated in boxers with dysfunction.

Conclusion: Temporomandibular Disorders were very frequent in boxers. Morphologic and functional alterations of the occlusion were common in this group of athletes. The provision of custom-made mouthguard should be actively encouraged by dental care workers.

Thursday, June 19th

Session 1- Award Nominees

Room: Victory Hall (14:00-15:00)

CLINICAL AND RADIOGRAPHIC OUTCOMES OF ROOT END CLOSURE

Albadri, Sondos*, Ivanova, Monika; Zaitoun, Halla; Gartshore, Laura; Coyle Kate
University of Liverpool Charles Clifford Dental Hospital/Sheffield Manchester Dental Hospital
Liverpool, United Kingdom

Purpose: To evaluate the clinical and radiographic outcomes of root end closure treatment provided for traumatised non-vital immature incisors at three paediatric dentistry centres. Furthermore, to investigate the treatment modality used, time taken to complete root end closure and evaluate patients' satisfaction following completion of treatment.

Methods & Materials: Data were collected prospectively for 60 patients (20 at each centre) with a traumatised, non-vital immature incisor, at completion of root end closure and 6 months follow-up. A piloted data collection form was used to capture information including clinical and radiographic outcomes and treatment modality; including root end closure with Mineral trioxide aggregate (MTA) or Calcium hydroxide apexification Ca(OH)₂. The service evaluation was registered with each centres clinical effectiveness unit. Data were entered into Statistical Package for Social Sciences (SPSS, v20) software for analysis.

Results: A total of 60 patient clinical records and radiographs were analysed. The mean age of the patients was 8.79 years, (range 6-15; SD=1.6). One patient was excluded as they received treatment with the revascularisation technique. Crown fractures were the most common presenting injury (61%) followed by luxation injuries (29%). Overall thirty-five teeth (59%) had root end closure with MTA and 41% had Ca(OH)₂. However there was substantial variation between the centers with Liverpool and Sheffield using MTA in 95% and 70% respectively compared to 2% in Manchester where Ca(OH)₂ apexification was the most common mode of treatment. This resulted in mean treatment duration of 5.7 (range=0.5-24), 6.1 (range=0.9-14) and 13.8 (range=6.9-30) months for Liverpool, Sheffield and Manchester respectively. The majority of obturations (93%) were reported as satisfactory according to the radiographic criteria set out by the multi-regional audit group. Eighty three per cent of patients were happy with their treatment. Concerns regarding tooth colour were reported by 9 patients (15%). Of those reviewed at 6 months, 74% were clinically asymptomatic with 13% showing signs of tooth discolouration and one tooth 2% a recurrent sinus.

Conclusion: Root end closure using MTA as opposed to Ca(OH)₂, is an effective technique that can reduce the treatment duration for non-vital immature incisors. Furthermore, reduced use of calcium hydroxide in root canals could potentially decrease the likelihood of fractures in these heavily compromised teeth. The majority of patients were happy with their treatment, although tooth discolouration was identified as an unsatisfactory outcome for some who had received treatment with MTA.

DENTINAL TUBULAR DISINFECTION OF TRI-ANTIBIOTIC AND CALCIUM HYDROXIDE PASTES

Andrade, Flaviana*, Oliveira TC, Vasconcelos LRM, Brandeleiro Jr S, Scaraficci AC, Duarte MAH, Bramante CM
Bauru School of Dentistry - University of São Paulo
Endodontics
Bauru, São Paulo, Brazil

Purpose: The pulp revascularization has been regarded as an alternative treatment in teeth with necrotic pulps and open apex, using the decontamination of tooth structure for subsequent stimulation of revascularization. The tri-antibiotic paste comprising metronidazole, ciprofloxacin and minocycline has been used for this decontamination, but the indiscriminate use of antibiotics can lead to the selection of resistant bacterial species. The dentinal tubular decontamination by calcium hydroxide and tri-antibiotic paste in bovine teeth infected was compared.

Methods & Materials: Twenty four roots of single-rooted teeth were standardized at 12mm length, instrumented up to file K120 and externally sealed with nail polish. Suspensions of *Enterococcus faecalis* (ATCC 29212) were standardized using a spectrophotometer (3x10⁸ CFU/mL) and inserted into microtubes with BHI broth and teeth samples. The contamination protocol followed a method recently developed (Andrade et al., 2014). After five days of contamination, the samples were fixed in a sterile device and the triantibiotic or calcium hydroxide pastes were placed into the root canals, remaining for 15 days. The samples were evaluated by microbiological culture through collecting dentine debris with Largo burs numbers 5 and 6, to verify the deep of decontamination. Controls were made to attest bacterial viability (positive control) and sterility of the procedure (negative control). The dentine debris were diluted and seeded in agar plates in order to subsequent counting of colonies.

Results: The tri-antibiotic paste had greater antimicrobial effect, however there was no statistical difference between the groups ($p < 0.05$).

Conclusion: It was concluded that the tri-antibiotic paste was slightly more antimicrobial into dentinal tubules, however, the calcium hydroxide paste can be used to decontaminate dentine, performing the same clinic function.

TOOTH SPLINTING AND MAINTENANCE OF VITALITY IN TRAUMATIZED PERMANENT TEETH

Belcheva, Ani*, Vladimirov Boyan, Shindova Maria
Medical University, Faculty of Dental Medicine
Pediatric Dentistry, Oral and Maxillofacial Surgery
Plovdiv, Bulgaria

Purpose: Dental injuries with displacement are normally splinted. The splinting methods should support periodontal healing. Different type of splinting has been described in the literature. The duration of splinting should be considered according to the injury. Aim: To evaluate pulp and periodontal healing of traumatized permanent teeth fixated with three methods of tooth splinting

Methods & Materials: Patients who suffer trauma to the permanent teeth were included in the study. Teeth with subluxation, lateral luxation and root fracture were repositioned and splinted with 3 kinds of splints – arch bar and wire, orthodontic wire and composite resin and Ribbond- modification splint. Reexaminations were performed at 1,3,6,12 and 48 month. A total number of 52 traumatized teeth (6 subluxated, 25 luxated and 14 root fractured teeth) were treated with a splint and observed for 2 years. The traumatized teeth were from 30 children aged 7-14 years (Mean age 9,33±2,073).

Results: All the subluxated teeth remain vital during the examined period. Teeth maintain their vitality were 78, 85%. Internal resorption was not found. External root resorption was found in 3 laterally luxated teeth. None of the teeth with open apex showed complications.

Conclusion: The methods proposed for traumatized teeth splinting positively affect healing after traumatic injuries. The number of complications remains low after 2 years of follow-up.

THREE-DIMENSIONAL (3D) ANALYSIS OF REGENERATIVE ENDODONTIC TREATMENT OUTCOME

Ezeldeen, Mostafa*, Van Gorp, Gertrude. Jacobs, Reinhilde
KU Leuven

OIC, OMFS IMPATH Research Group, Department of Imaging & Pathology, Faculty of Medicine, KU Leuven & Oral and Maxillofacial Surgery, University Hospitals Leuven Department of Oral Health Sciences, KU Leuven & Paediatric Dentistry and Special Dental Care University Hospitals Leuven
Leuven, Belgium

Purpose: A growing body of evidence supports the regeneration potential of dental tissues and continued root development after Regenerative Endodontic Treatment (RET). Nevertheless, a standard quantitative method for the evaluation of RET outcome is lacking. The aim of this study was to develop and validate a standardized quantitative method for RET outcome analysis based on CBCT volumetric measurements.

Methods & Materials: Five human-teeth embedded in mandibular bone samples were scanned using both an Accuitomo 170® Cone Beam CT (Morita, Kyoto, Japan) (80µm and 160µm) and a SkyScan 1174® µCT system (SkyScan, Antwerp, Belgium) (30µm). For subsequent clinical validation, clinical data and low dose CBCT scans (pre-operatively and >12-months follow-up) from 5 immature permanent teeth treated with RET were retrieved. In vitro and clinical 3D image datasets were imported into a dedicated software tool. Two segmentation steps were applied to extract the teeth of interest from the surrounding tissue (bone) (interactive live-wire boundary extraction) and further to separate tooth hard tissue and root canal space (semi-automatic user guided 3D active contour segmentation using level-set methods). Root canal diameter (thickness) was measured and color coded, then the hard-tissue thickness measurement was expressed as a color coded map showing the calculated minimal distances from the canal surface to the external root surface. Differences between CBCT and µCT-based volumetric measurements were assessed using Wilcoxon matched pairs test. Pearson correlation analysis and Bland and Altman plots were used to evaluate the relation and agreement between the segmented CBCT and µCT volumes. Clinically, volumetric changes after RET were evaluated by comparing root hard-tissue volume starting from the cemento-enamel junction up to the apex using the Wilcoxon matched pairs test.

Results: Results showed no statistical differences ($p > 0.05$) and strong correlation [(hard-tissue $r = 0.99$, $p < 0.0001$) (root-canal $r = 0.99$, $p < 0.001$)] between CBCT and µCT volumetric measurements. Volumetric comparison of the root hard tissue showed significant hard tissue formation [mean volume of newly formed hard tissue was 27.9 (±10.5) mm³, ($p < 0.05$)]. 3D analysis showed a non-uniform nature of hard tissue formation on the internal walls of the root canal that was unique for each tooth.

Conclusion: Analysis of 3D data for teeth treated with RET offers valuable insights into the treatment outcome and patterns of hard-tissue formation.

THE ROLE OF TIME-ELAPSED ON PROGNOSIS OF CROWN-RELATED FRACTURES

Atabek, Didem*, Alaçam, Alev; Aydintug Itir; Baldag A. Ilknur
Gazi University Faculty of Dentistry,
Department of Pedodontics,
Ankara, Turkey

Keywords: Trauma, crown fracture, prognosis

Purpose: The time elapsed after trauma is one of the important factors that affects the prognosis of the cases. The aim of this study was to examine the prognosis of crown-related fractures according to the arrival time to the clinic for treatment, accompanying trauma types, symptoms and treatment.

Methods & Materials: This retrospective study was carried out on 37 complicated and 69 uncomplicated crown fractured teeth in 76 patients referred to the Department of Pedodontics of Gazi University in Ankara. The records of cases were examined for the following: age, sex, teeth number, trauma type, time elapsed following injury, accompanying trauma type, treatment and prognosis. The data were analyzed using the Chi-squared or binomial tests and a $p < 0.05$ was considered statistically significant.

Results: The dental trauma records of patients with an average age of 10 years, including 76 patients with 37 complicated (34.9%) and 69 uncomplicated crown fractured teeth (65.1%) were evaluated. The most commonly affected teeth were the maxillary right central incisors (46.2%). Only 16 patients (43.2%) with complicated crown fractures were referred to the clinic within the same day following the injury whereas the number for uncomplicated crown fractures was 24 patients (34.7%) For uncomplicated crown fractures that referred to the clinic after 1 week, increased vitality loss was seen. Depending on the accompanying trauma type and time elapsed after trauma the prognosis of the cases (even uncomplicated crown fractures) was affected negatively.

Conclusion: This study focused on the importance of elapsed time after the trauma and its effects on treatment type and prognosis. It was concluded that even simple crown fractures ended up with inflammation or pulp necrosis because of late referral besides accompanying trauma.

RELIABILITY OF A DENTAL TRAUMA RECORD TO IDENTIFY CHILD ABUSE / NEGLECT

Flores, Marie Therese*, Salum, Sara (2), Salum, Elena (2), Onetto, Juan Eduardo (1), Uribe, Sergio (3)
(1) Faculty of Dentistry, (2) Faculty of Law and Social Sciences, Universidad De Valparaiso, Chile,
(3) School of Dentistry, Universidad Austral De Chile Valparaiso, V Region, Chile

Keywords: diagnosis, primary teeth injuries, child abuse/neglect

Purpose: To identify if the information provided by a dental trauma record allows differentiating an accidental injury from a possible physical child abuse or neglect.

Methods & Materials: This is a reliability study. 470 records from a coded database of injuries affecting the primary dentition of children aged 0-5 years, from 1994 to 2012 were analyzed. The emergency record for acute dental trauma has been adapted from the one suggested by Andreasen JO (in. Essentials of Traumatic Dental Injuries, 1990) which includes questions such as how, where, when did the injury occur as well as information of previous injuries to the teeth. A criminology expert (SS) registered the information in order to obtain data from three scopes: - Classification: accidental, neglect, intentional-related injury or no information provided. - Place of injury occurrence: Private or public. Private place of injury refers to the home, the backyards of the child's home, the caregiver or the guardian of the child. Public place of injury refers to the street, playgrounds, childcare center, the shopping mall and all other outdoor areas. - Possible indicators of child abuse or neglect, such as multiple tooth injuries, recurrent episodes of tooth injury, conflicting/inconsistent histories given by caregivers and delay in seeking dental care. Three months later, the same criminology expert assessed 67 randomly selected records. The data were analyzed using SPSS v19. A reliability test was applied through Cronbach' alfa for each scope. A score =0.75 was considered reliable.

Results: Data from the first analysis of scope Classification were used for selecting the records for the second data analysis. One of the researchers (JO) performed randomly selection for each variable: accidental 33/311 (10%); neglect 24/115 (20%); intentional 2/7 (30%); no information provided 8/37 (20%). Thus, 67 records were selected. The score obtained for classification was 0.531; place of injury: 0.685; possible indicators of child abuse or neglect: 0.733, respectively.

Conclusion: In spite of a carefully review of coded information, data from acute dental trauma records were not reliable to identify physical child abuse or neglect-related dental injuries. New criteria or indicators should be included for allowing a discrimination analysis in order to recommend a child abuse and neglect-related dental injury classification.

Thursday, June 19th

Session 2- Award Nominees

Room: Victory Hall (15:00-16:00)

PREVALENCE OF TRAUMATIC DENTAL INJURY AND COMPLICATIONS FROM LATE PRESENTATION

Enabulele, Joan Emien*, Oginni, Adeleke: Sede, Matthew: Oginni, Fadekemi
University of Benin
Restorative Dentistry
Benin City, Edo State, Nigeria

Keywords: Traumatic Dental Injury, complications

Purpose: The objectives of this study were to determine the prevalence and pattern of traumatic dental injury (TDI) among adults presenting in a tertiary health care facility in Nigeria, the time interval between injury and presentation in the hospital, the reasons for seeking treatment, and the complications arising due to late presentation.

Methods & Materials: Information obtained from history taking and clinical examination included Patient's demographics, the when, where, and how of the injury, previous history of trauma, time elapsed between injury and presentation at the hospital, reason for seeking treatment, tooth/teeth involved, sensibility, tenderness to percussion, mobility, presence of discolouration, swelling, sinus tract, and mobility. Radiographic findings such as periapical radiolucency, pulp canal obliteration, and internal/external resorption were also documented. TDI was classified using the Andreasen's classification. A retrospective diagnosis of concussion was made from patient's history of trauma to the tooth without abnormal loosening, while subluxation was made from patient's history of trauma to the tooth with abnormal loosening. Pulp canal obliteration was the diagnosis when pulp chamber and root canal were not discernible on radiograph.

Results: Out of the 2,645 adult patients that attended the outpatient clinic, 184 Presented with TDI giving a prevalence of 6.96%. Their age range and mean age were 17 to 69 years and 30.6 ± 11.2 years respectively. Falls accounted for most (26.4%) of the trauma to anterior teeth followed by motor cycle accidents (18.4%) and domestic accidents (12.9%), while opening bottle cork accounted for 1.2%. The most common type of injury was enamel-dentine fracture accounting for 28.8%, followed by complicated crown fracture 18.6%, and avulsion 11.7%. The maxillary central incisors were the most commonly affected followed by the maxillary lateral incisors and canines. More than half (51.5%) of the patients presented in the hospital more than 1 year after injury. Majority of patients in the age groups = 20 and 51 – 60 sought treatment because of pain, while more of those in the age groups 21 - 30 and 31 – 40 sought treatment because of aesthetic considerations. Seventy three (45.3%) of the patients presented with complications involving 138 teeth. Majority of the complications were in teeth with enamel-dentine fracture (93.4%), followed by concussion injury (55.6%).

Conclusion: The prevalence of TDI in this study falls within previously reported figures. However, the high number of teeth developing complications may have resulted from late presentation for care.

CHARACTERIZATION OF TRAUMATIC DENTAL INJURIES CAUSED BY INTERPERSONAL PHYSICAL VIOLENCE

Ortiz, Maria Eugenia*, Mac-Lean, Barbara; Hernández, Mónica; Rodríguez, Carolina
Universidad Austral De Chile
Instituto De Odontostomatología
Valdivia, Region De Los Rios, Chile

Purpose: Orofacial injuries are among the most common types of injury found as a consequence of interpersonal physical violence. The face is a common target due to its anatomic vulnerability which makes it liable to suffer serious injuries. The aim of the present study was to describe the pattern of traumatic dental injuries which result from interpersonal physical violence (IPV) in the city of Valdivia, Chile; assessed between January 2007 and May 2013.

Methods & Materials: A descriptive study with a 5 years retrospective analysis (2007/2013) was conducted in dental trauma records from patients admitted to Dental Service of Valdivia's General Hospital, Chile. The 77 eligible records were those that presented IPV as the cause of injuries. The variables analyzed were: gender, age, type of injury, most affected teeth, time elapsed before emergency treatment and follow-up controls. Descriptive statistical analysis: SPSS 19.

Results: A total of 77 patients (51 male, 26 female) with 124 teeth presenting hard and supporting tissues injuries affected by IPV, with a mean of 3 affected teeth per patient. In relation to age, 54 patients (70%) were older than 18 years, and 23 patients (30%) were younger. The most common injured teeth were the upper incisors and the most common injuries were: lateral luxation 32 (26%), enamel-dentine crown fracture 26 (21%), enamel-dentine-pulp crown fracture 23 (19%), subluxation 15 (12%), dental avulsion 8 (7%), root fracture 8 (7%), extrusive luxation 6 (5%), crown-root fracture 4 (3%) and concussion 2 (1%). The most frequently injured teeth were the left central incisor 36 (29%), right central incisor 33 (27%), left lateral incisor 21 (17%), right lateral incisor 9 (7%). With respect to time elapsed before treatment 42 (55%) patients received their first emergency attention after 24 h., and 35 (45%) patients sought dental emergency care before 24 h. Patients that continued with their follow-up controls were 51 (66%).

Conclusion: This study showed that IPV injuries are more frequent in male adults and affect hard and supporting tissues in an average of 3 maxillary incisors. These affected teeth have an important role in occlusion and directly influence the smile and face aesthetics of the patient, also being important in a psychological aspect. It is necessary that education & prevention programs focused in adolescent groups consider this dental trauma topics.

TREATMENT OUTCOME OF MID-ROOT FRACTURES IN PRIMARY TEETH

Siyi Li, Lei Gao, Lian Wu*, Xiaojing Wang, Jingyi Li, Yanan Sun, Lei Yan
Xi'an, China

Keywords: mid-root fracture, primary teeth, splinting

Purpose: It is widely acknowledged that root fracture of primary teeth is more common in elderly children who had completed the development of roots, although it is relatively uncommon among dental trauma. Besides, the most frequently type was mid-root fracture and the involved teeth were the maxillary incisors. The conventional idea for practitioners was extracting the affected primary teeth because of the difficulty of achieving a stable reunion of fracture fragments. However, conservation of the affected primary teeth may be good to the permanent successors. What's more, it favors the children in functional and esthetic aspects. The aim of this clinical study was to evaluate the treatment outcome of mid-root fractures of primary incisors in children who suffered from dental trauma.

Methods & Materials: This study comprised of 27 children among the age of 3 to 5 with 44 mid-root fractured teeth, who came to our department during the period 2006 - 2013. The data was collected according to the history of trauma, clinical examination and radiographic examination. All of the eligible teeth were repositioned and splinted. Periodic check-up is essential, we instructed patients to remain good oral hygiene and review the fracture teeth two weeks after the treatment, 1 month, and then 3-monthly to evaluate the splint treatment outcome. Proper diagnostic tests such as dental periapical film should be done to get correct diagnosis and evaluations. Normal mobility, resorption of apical fractured root fragment and normal development of permanent successors are positive outcomes.

Results: It can be concluded that delayed management of root fracture and severity of displacement affect the treatment outcome. Furthermore, mid-root fractures in primary teeth can obtain good result as high as 90.9% thanks to good reposition and splinting. In addition, the control of inflammation plays a crucial role in the treatment process, while inflammatory root resorption and pulp necrosis are common complications.

Conclusion: We can conserve mid-root fracture teeth instead of extraction. Root resorption and pulp necrosis are common complications. The delayed management affected the treatment outcome. This study may lead practitioners forming a new thinking style to develop more reasonable and evidence-based treatment modalities for mid-root fractures in primary teeth.

EFFECT OF TOPICAL TREATMENT WITH DOXYCYCLINE ON REPLANTED PERMANENT INCISORS

Malmgren, Barbro*, Tsilingaridis, Georgios, Malmgren, Olle*, Skutberg, Catharina
Karolinska Institutet
Department of Dental Medicine
Huddinge, Sweden

Purpose: Tooth avulsion in young growing individuals is an uncommon but very severe dental trauma. The aim of this study was to evaluate the effect of topical treatment with Doxycycline on avulsed permanent incisors compared to treatment with only saline regarding pulp survival and periodontal healing.

Methods & Materials: The material consisted of 66 avulsed teeth in 50 patients (34 boys and 16 girls) with a mean age of 11 years (range 6.5-18 years). Before replantation, 30 teeth were treated topically with Doxycycline and 36 teeth with saline. The mean observation time was 48 months. Root development was categorized with respect to root formation and development of the apex into three groups, ¼-root formation to full root formation with open apex, full root formation with half-closed apex and full root formation with closed apex.

Results: In the Doxycycline group 27 were diagnosed with pulp necrosis, 15 with replacement resorption and 9 were extracted during the observation period. In the saline group, 30 were diagnosed with pulp necrosis, 23 with replacement resorption and 11 were extracted during the observation period. No significant differences were found between the two groups. Teeth with immature root development show significantly less pulp necrosis ($p=0.002$) compared to teeth with full root formation regardless if treated topically with Doxycycline or not.

Conclusion: Our findings suggests that topical Doxycycline treatment of avulsed permanent teeth have no beneficial effect on pulp survival and periodontal healing regardless of root development, storage and extra oral time.

TRAUMATIC DENTAL INJURIES AMONG CHILDREN: WHO, WHEN AND WHERE?

Oldin, Anna*, Lundgren, Jesper; Nilsson, Marita; Norén, Jörgen G; Robertson, Agneta
University of Gothenburg, Institute of Odontology
Department of Pediatric Dentistry
Gothenburg, Sweden

Purpose: The aim of the study was to investigate traumatic dental injuries (TDI) in Swedish children aged 0-17 years with focus on prevalence, incidence, change in prevalence over time and etiology in relation to age and/or gender and further, to investigate variations in prevalence related to seasons.

Methods & Materials: The study included 2363 children in four different age cohorts at 12 different Public Dental Service clinics in Sweden. The design was a 5-year longitudinal study including yearly clinical examinations, retrospective and prospective data compiled from dental records and interviews regarding TDI.

Results: A total of 889 children had suffered from TDI with no difference between the genders and no differences were found in frequencies between the seasons. The prevalence for TDI was 37.6% with an incidence of 2.8%. The incidence varied between the age groups where preschool children had the highest incidence. No changes in prevalence for TDI were found for the years included in the study. The most common reason for TDI was Falling (42.1%), Blow by a moving object (12.9%) and Play (11.8%). The frequencies for the different etiological factors varied between the ages where Falls and Blow by a moving object were most common between 2-3 years, Play between 4-5 years, Sports between 8-9 and 12-13 years and Biting on hard objects between 16-17 years.

Conclusion: The prevalence for TDI has not changed in recent years and is stable on high levels. The incidence for TDI was higher among the preschool children and decreased with increased age. The children injured their teeth evenly spread throughout the year and both boys and girls injured their teeth just as often. The frequencies for the different etiological factors varied between the ages.

A NEW STORAGE MEDIUM FOR AN AVULSED TOOTH

Parisay, Iman*, Talebi, Maryam-Tavakol Afshari, Jalil - Shajiei, Arezoo- Sofiani Ghadim, Mostafa
Associate Professor Pediatric Dentistry, Dental Material Research Center, School of Dentistry,
Mashhad University of Medical Science, Mashhad, Iran
Pediatric Dentistry
Mashhad, Iran

Keywords: Avulsed teeth, Ham's F-10 cell culture medium, HBSS

Purpose: The purpose of the present study was to evaluate the efficacy of Ham's F-10 cell culture medium in maintaining the viability and reproducibility of PDL cells on avulsed teeth.

Methods & Materials: In this in vitro experiment, 60 mature healthy extracted premolar teeth were used. The experimental media for the viability test were: Ham's F-10, Hank's balanced salt solution (HBSS), skim milk and tap water. The experiment was done at four different storage times: 1, 3, 6, and 24 h. In addition, the reproducibility of the cells was done by Methylthiazol Tetrazolium test (MTT) assay in 1, 3 and 6 h for Ham's F-10, HBSS and tap water.

Results: In all experimental storage times, the viability of the PDL cells in Ham's F-10 and HBSS was significantly higher than milk and tap water ($p < 0.001$). The cell viability difference between Ham's F-10 and HBSS was not significant except in the 6-h storage time ($p = 0.04$). According to MTT assay results, Ham's F-10 and HBSS were significantly better than tap water ($p < 0.001$), and the difference between Ham's F-10 and HBSS was significant only in the 3 h storage time ($p < 0.001$).

Conclusion: Ham's F-10 cell culture medium could be a suitable alternative storage medium for avulsed teeth.

Thursday, June 19th

Session 3

Room: Victory Hall (16:30-17:30)

APICAL MICROLEAKAGE OF DIFFERENT MATERIALS IN CORONAL ROOT FRAGMENTS

Akbay Oba, Aylin*, Arikan, Volkan*, Karatas, Merve*
Kirikkale University
Pediatric Dentistry
Kirikkale, Turkey

Keywords: Root Fractures, MTA, Biodentine

Purpose: In root fractures at the apical third, if pulp necrosis develops in the coronal root fragment, endodontic treatment of the fragment can be considered as a treatment option. This invitro study evaluated and compared the apical microleakage of ProRoot MTA(Dentsply), DiaRoot BioAggregate (DiaDent) and Biodentin (Septodont) in endodontic treatment of coronal root fragments.

Methods & Materials: Forty-eight bovine maxillary incisors roots were fractured at the apical third by using a hammer and randomly divided into three groups (n=16). Coronal fragments were prepared and obturated with; Group I: ProRoot MTA; Group II: DiaRoot BioAggregate (DiaDent); Group III: Biodentin(Septodont). Apical microleakage was assessed using dye penetration technique. The linear dye penetration was measured at X30 magnification and the data were analyzed with Kruskal Wallis H test.

Results: While Group II showed the highest leakage with a mean dye penetration of 3.72 mm and the leakage was the lowest in Group I with a mean dye penetration of 2.50 mm, the differences between groups were not statistically significant (p>0.05).

Conclusion: The findings of the present study suggest that the three materials evaluated may present similar results when used for the endodontic treatment of coronal fragments in intra-alveolar root fractures and can be considered as alternative options.

EVALUATION OF IRRIGANT EXTRUSION IN SIMULATED IMMATURE PERMANENT TEETH

Aksel, Hacer*, Askerbeyli, Sevinc; Canbazoglu, Cigdem; Serper, Ahmet
Hacettepe University, Faculty of Dentistry
Endodontics
Ankara, Turkey

Purpose: Inadvertent irrigant extrusion toward the periapical tissues has been described in a number of case reports. Sequelae such as severe pain, inflammation, and delayed healing may develop. In addition, for immature permanent teeth, the preservation of the remaining stem cells is an important prerequisite in root canal revascularization and root maturation. However, root canal disinfection materials can be detrimental to stem cells. To date, the irrigant extrusion in immature permanent teeth has not been thoroughly investigated in the literature. For this reason, the purpose of this study is to evaluate irrigant extrusion in the simulated immature permanent teeth in regards to different apical diameter and needle insertion depth.

Methods & Materials: Thirty human-single-rooted-maxillary-incisors were selected. The root length was standardized to the length of 9 mm as measured from the facial CEJ. For simulation of teeth with immature apices, peeso reamers were used for the root apex enlargement. In one group, peeso reamers between #1 and #3 were introduced in the root canals by allowing to protrude 1 mm beyond the apex while in the other group, the root apex of the specimens was enlarged up to the size of #6 peeso reamers. In each experimental groups, the irrigation solutions will be applied 2 or 4 mm short of root apex(n = 15). Glass vial model was used for collection of extruded irrigant.

Results: The statistical analysis using two way repeated measures analysis for variance test revealed no significant difference between different needle positions (2 and 4 mm short from the WL (working length) with the apical diameter of #6 peeso reamer(p>0.05). In the group with apical diameter of #3 peeso reamer, 31% increase in the irrigant extrusion was observed when the needle positioned at 2 mm short from the WL (p<0.05). In regards to the effect of apical diameter, the group with the size of #6 peeso reamer showed more apical extrusion of irrigant than the group with the size of #3 peeso reamer (34% increase for the needle positioned at 2 mm short of the WL and 68% increase for the needle positioned at 4 mm short of the WL; p<0.05).

Conclusion: Needle insertion depth had a significant effect on irrigant extrusion in simulated immature permanent teeth depending on the apical diameter. There was a tendency to extrude apically more irrigant through the periapical area as the apical diameter increased.

EFFECT OF QMIX ON REMOVING CALCIUM HYDROXIDE FROM ROOT CANALS

Aktemur Türker, Sevinç*, Uzunoglu, Emel**, Özçelik, Bahar**

*Bülent Ecevit University Faculty of Dentistry, Department of Endodontics **Hacettepe University Faculty of Dentistry, Department Of Endodontics
Ankara, Turkey

Keywords: Calcium hydroxide removal, QMix, irrigation solutions

Purpose: This study evaluated the efficiencies of different irrigation solutions in the removal of calcium hydroxide (Ca(OH)₂).

Methods & Materials: Fifty mandibular incisor teeth were used. Root canals were prepared with the ProTaper system (Dentsply Maillefer, Baillagues, Switzerland). Five milliliters 2.5% NaOCl, 5 mL 17% EDTA, and 10 mL saline were used for final irrigation. Then canals were filled Ca(OH)₂ paste. After 7 days teeth were divided into 4 experimental groups (n = 11) and the remaining teeth served as positive and negative controls (n=3). Irrigation procedures were performed as following: Group 1; 2.5 ml 17% EDTA, Group 2; 2.5 ml QMix, Group 3; 2.5ml 2.5% NaOCl+ 2.5 ml 17% EDTA, Group 4; 2.5 ml 2.5%NaOCl + 2.5 ml QMix. The roots were grooved longitudinally and split into halves. Digital photographs were taken and were imported into image analyzer software (Comef 4.3; OEG Messtechnik, Frankfurt, Germany). The amount of residual Ca(OH)₂ on the canal walls was measured mm² and recorded as a percentage of the overall canal surface area. The results were statistically analyzed with Kruskal-Wallis and Conover Dunn tests with the null hypothesis set as 5%.

Results: The positive control group had complete coverage of the canal walls with Ca(OH)₂ in contrast to the negative control (P < 0.05). Group 3 (2.5% NaOCl +17% EDTA) showed the least effect in removing Ca(OH)₂. QMix (Group 2) and its combination with NaOCl (Group 4) showed better results than the combination of 17 % EDTA and 2.5% NaOCl.

Conclusion: Results showed that QMix is an effective agent in removing Ca(OH)₂. None of the irrigants nor their combinations with NaOCl were able to completely remove the Ca(OH)₂. The type of the irrigant was more effective in Ca(OH)₂ removal than the amount of irrigant.

EFFECT OF DIFFERENT IRRIGANT ACTIVATION PROTOCOLS ON PUSH-OUT BOND STRENGTH

Akyüz Ekim, Sefika Nur*, Erdemir Ali
Faculty of Dentistry, Kirikkale University.
Endodontics
Kirikkale, Turkey

Keywords: Diode Laser, Er:YAG laser, Irrigation activation

Purpose: To evaluate the effect of various final irrigant activation protocols on push-out bond strength of fibre post.

Methods & Materials: Thirty two single-rooted human maxillar central teeth were sectioned below the cemento-enamel junction, instrumented and obturated. Post space preparation was performed and roots were randomly divided into eight groups (n =4) according to the final irrigant activation protocols; distilled water was used as an irrigant in Group1. The other groups were treated with 2.5% NaOCl and 17% EDTA, respectively. Conventional Syringe Irrigation (CSI, no activation) was used in Group2. Irrigation solutions were activated using Passive Ultrasonic Irrigation (PUI, Group3), EndoVac-Apical Negative Pressure (ANP, Group4), Diode laser (Group5), Nd:YAG laser (Group6), Er:YAG laser (Group7) and Er:YAG laser using with Photon Induced Photoacoustic Streaming (PIPS™) technique (Group8). In all groups, fibre posts (White Post DC, FGM) were luted using Panavia F 2.0 (Kuraray, Osaka, Japan). The specimens were transversally sectioned and all slices from coronal and apical regions were subjected to push-out tests. The data were calculated as megapascals and analyzed by using Two-way Analyses of Variance (ANOVA) followed by post hoc Tukey HSD tests.

Results: Removing the smear layer was increased the bond strength to dentin when compared with the control group (p<0.05). Coronal root region presented significantly higher bond strength than the apical region (p<0.05). Highest bond strength was obtained in the PIPS laser-activated irrigation group (P<0.05).

Conclusion: PIPS laser-activated irrigation showed considerable performance as a final irrigant activation protocol on push-out bond strength of fiber post.

EFFECT OF PREPARATION FOR POST ON THE REMAINING DENTINE THICKNESS

Alomari, Qasem*, Barrieshi, Kefah and Al-Awadi, Sundus
Kuwait University
Restorative Sciences
Kuwait, Kuwait

Purpose: To investigate the effect of post-space preparation on the remaining dentine thickness in the apical region of maxillary central and lateral incisors.

Methods & Materials: Fifty extracted maxillary incisors (25 centrals and 25 laterals) were mounted and then sectioned at two levels: 5 and 7 mm from the apex. Computerized images were obtained and a digital image analysis system was used to measure dentine thickness for each section at 8 sites: labial, mesial, distal, palatal, mesio-labial, disto-labial, mesio-palatal and disto-palatal. Measurements were repeated at baseline and after post-space preparation. Central and lateral incisors were divided into 5 groups each (n=5) according to the drill used for post-space preparation: Groups 1 through 4 were prepared using Parapost drills sizes 4.5, 5, 5.5 and 6 respectively. For group 5, size 4 Gates Glidden was used.

Results: For both teeth, and at the two levels there was a significant difference ($p < 0.001$) between the baseline dentine thickness and that remaining after post-space preparation at all sites. There was statistically significant difference ($p = 0.007$) between the remaining dentine thickness at 5 and 7 mm at all sites. The average amount of dentine removed ranged from 0.20 to 0.52 mm. In all groups, and for both teeth, some specimens had less than 1 mm of remaining dentine thickness.

Conclusion: The usage of posts is accompanied with loss of tooth structure material and that might weaken the involved tooth. This study showed that substantial amount of tooth structure is lost during placement of the post in a root canal treated tooth. Therefore, posts should be used carefully in managing root filled maxillary incisors.

REVASCULARIZATION OF PERMANENT IMMATURE NECROTIC TEETH

Bakhtiar, Hengameh*, Azimi, Shahram. Vatan Pour Mehdi
Faculty of Dentistry, Islamic Azad University, Tehran, Iran
Endodontic Department,
Tehran, Iran

Keywords: PRGF; triple antibiotic paste; apex formation; regenerative endodontics

Purpose: The aim of this report is to describe the positive effect of plasma-rich in growth factor (PRGF) on pulp regeneration and apex formation of cases with necrotic pulps and open apices.

Methods & Materials: After access cavity preparation and cleaning of the canal, triple antibiotic paste was inserted in canals for the purpose of disinfection. After two weeks, apical bleeding was mechanically created by insertion of a #80 file through the apex. PRGF obtained from the patient was centrifuged and injected into the canals up to the level of the cemento-enamel junction and teeth were temporarily restored. The patients returned for review two weeks later. If there were an absence of pain, swelling, fistula, or any other complication, the teeth were sealed with MTA and composite.

Results: At 22 months follow up, complete apex closure in two teeth and apical closure and continued increase of dentinal wall thickness in two other cases was evident.

Conclusion: Although the number of cases presented here is small, it may seem that pulp regeneration in teeth with necrotic pulps and open apices is predictable if the suggested protocol able to be achieved. In these circumstances, PRGF may be a suitable scaffold for pulp regeneration.

Thursday, June 19th

Session 4

Room: Victory Hall (17:30-19:00)

EVALUATION OF MINERAL TRIOXIDE AGGREGATE AND BIOAGGREGATE AS APICAL BARRIER

Bayrak, Sule*, Tuloglu, Nuray
University of Eskisehir Osmangazi,
Department of Pediatric Dentistry
Eskisehir, Turkey

Purpose: This randomized controlled study aimed to provide a comparative evaluation of the clinical and radiographic success of Mineral Trioxide Aggregate and BioAggregate as an apical barrier in children with traumatized non-vital, immature permanent maxillary incisors.

Methods & Materials: The study population consisted of healthy and cooperative children applying for treatment at the Department of Pediatric Dentistry. This randomized controlled trial was approved by the Ondokuz Mayıs University Clinical Research Ethics Council (2009/3), and informed consent was obtained from the parents of all study participants. A total of 26 maxillary incisor teeth in 20 children aged 7-11 were selected for the study. Teeth were randomly divided into two groups according to the material to be applied, and apical barrier was performed. Following treatment, teeth were clinically and radiographically evaluated once every three months for 24 months.

Results: All teeth treated with Mineral Trioxide Aggregate and BioAggregate were clinically and radiographically successful throughout the 24-month follow-up period. Coronal discoloration was observed in two teeth in the Mineral Trioxide Aggregate group, but in no teeth in the BioAggregate group.

Conclusion: Similar success was achieved in apical barrier that using BioAggregate and Mineral Trioxide Aggregate. However, given that Mineral Trioxide Aggregate resulted in coronal discoloration, whereas BioAggregate caused no coronal discoloration. In conclusion, BioAggregate can be considered suitable materials for apical barrier and can be used as an alternative to Mineral Trioxide Aggregate in apical barrier formation.

COMPARISON OF CORONAL FRACTURE RESISTANCE RESTORED WITH INTRACANAL REINFORCEMENT MATERIAL

Carikcioglu, Burak*, Yanar, Esra; Celis, Pelin; Simsek, Sera; Yilmaz, Yucel
Ataturk University
Pediatric Dentistry
Erzurum, Turkey

Purpose: The aim of this study was to compare the effects of different restorative materials such as short-post fiber (SPF; GrandTEC®, Voco), prefabricated fiber post (PFP; Rebilda®, Voco), high viscosity flowable resin composite (HVC; GrandioSO Heavy Flow®, Voco), flowable base resin composite (FBC; X-tra Base®, Voco), self-adhesive flowable composite (SAFC; Fusio Liquid Dentin, Pentron Clinical), glass ionomer cement (GIC; Ionofil Molar®, Voco) and calcium silicate cement (CSC; Biodentin, Septodont) on the coronal fracture resistances of endodontically treated incisors.

Methods & Materials: 64 human unrestored and non-carious maxillary permanent central incisors that were extracted due to periodontal reasons were used for this study. 8 teeth were selected as control group. Endodontic entry cavities were prepared for 56 teeth. Root canals were shaped with step-back method, irrigated with saline solution 0.9% and then filled with polymeric calcium hydroxide root canal sealer. 56 teeth were divided into 7 treatment groups. While 3mm-deep root canal filling materials were removed from the samples in the groups 2,3,4,5,6 and 7; 7mm-deep materials were removed from the specimens in the group 8. After these procedures, root canals were irrigated and dried. Group-1: Virgin tooth (Control). Group-2: 25% polyacrylic acid (the root canal was etched)+GIC. Group-3: 34.5% phosphoric acid (the root canal was etched)+dentin bonding agent+HVC. Group-4: 34.5% phosphoric acid (the root canal was etched)+dentin bonding agent+FBC. Group-5: SAFC. Group-6: CSC. Group-7: 34.5% phosphoric acid (the root canal was etched)+dentin bonding agent+SPF. Group-8: 34.5% phosphoric acid (the root canal was etched)+dentin bonding agent+PFP. In addition, all endodontic access cavities were filled with HVC. The endodontically treated teeth were subjected to thermocycling procedures and soaked in the 0.5% basic-fuchsin dye for 24 hours. A force was applied on the palatal surface at 135° angle, with a cross-head speed of 0.5mm/minute until fracture. Failures occurred under fracture resistance force (repairable/non-repairable) and the occurrence microleakage (presence/absence) were recorded. The results were analyzed with ANOVA Tukey test and Duncan test. (P<0,05)

Results: There was statistically significant difference among the groups for fracture resistance force test. Duncan post-hoc test showed statistically difference between Group-1, Groups-3 and Group-6, but none between the others. On the other hand, no significant difference was found for both failures occurred under fracture resistance force testing and microleakage scores.

Conclusion: On the basis of the current best available evidence, hard tissues of the incisors treated endodontically with latest the marketed materials might be better protected.

EVALUATION OF DENTIN DISINFECTION BY USING MTA WITH DIFFERENT EXTRACTS

Cavenago, Bruno Cavalini*, Duarte, Marco Antonio; Ordinola-Zapata, Ronald; Amoroso-Silva, Pablo; Fernandes, Samuel; Midena, Raquel; De Andrade, Flaviana.

Bauru School of Dentistry, University of São Paulo
Department of Operative Dentistry, Endodontics and Dental Materials
Bauru, São Paulo, Brazil

Keywords: MTA, bacterial viability, confocal laser scanning microscopy.

Purpose: This study aimed to evaluate the effectiveness of dentin disinfection promoted by white MTA mixed with extracts of *Arctium lappa* L. (AL) and propolis, using a bovine dentin infection model and confocal laser scanning microscopy (CLSM).

Methods & Materials: Fifty single-rooted bovine teeth were used to obtain root segments of 3mm of length from the apical third. The root canals were prepared until a size 120 K-file and dentinal tubules were infected with *Enterococcus faecalis*. Bacterial suspensions were standardized using a spectrophotometer (3x10⁸ CFU/mL) and delivered into the tubules by a centrifugation protocol. After five days the root canals were filled with experimental cements using a MTA carrier device. Four groups (n=10) were prepared mixing white MTA-Angelus with different vehicles in a 3:1 powder-to-liquid ratio, as follows: group 1: 100% distilled water (DW); group 2: 100% aqueous extract of AL; group 3: 80% DW + 20% propylene glycol extract of AL; group 4: 80% DW + 20% propylene glycol extract of propolis. Inoculated specimens with empty root canals (n=10) were used as control group. After 24 and 168 hours the samples were sectioned and semicylindrical dentin specimens were evaluated by CLSM, and viability staining was used to quantitatively analyze the proportions of dead and live bacteria inside the dentin. Statistical analysis was performed using the Kruskal-Wallis and Dunn tests (P < 0.05).

Results: The use of propolis extract showed more effectiveness on the reducing bacterial viability in comparison to distilled water (P < 0.05) after 24 hours. The control group showed more live bacteria than groups 2, 3 and 4 (P < 0.05). No statistically significant differences were found among experimental groups after 168 hours.

Conclusion: The addition of propolis extract to white MTA increased its disinfecting potential in dentin after 24 hours.

INJURIES TO THE GINGIVA RESULTING FROM DENTO-ALVEOLAR TRAUMA

Ebeleseder, Kurt*
University Dental Clinic
Department of Conservative Dentistry
Graz, Austria

Purpose: The aim of the study was to describe the situation of the gingiva after dento-alveolar trauma.

Methods & Materials: Dental trauma records were recruited from the dental trauma ambulance at the University Clinic of Graz in which since 1993 all traumatic dental injuries and following treatments have been recorded prospectively. For all injured teeth, separate recordings exist for dental hard tissue, pulp, periodontal ligament, alveolar bone and gingiva. By random the injuries of the year 2004 were chosen. The sample comprised 219 patients with 463 injured teeth.

Results: 33% of all patients / 32% of all injured teeth were free from gingival injuries. 44 % / 41 % showed gingival injuries without displacement (enlargement of the gingival sulcus or excoriation). 23 % / 27 % showed gingival injuries with displacement (GDis). The main injury types of GDis were „Laceration of the papilla“ (54%), „Bruising“ (16%), „vertical laceration of the attached gingiva“ (13%) and „flap displacement“ (10%). The highest percentage of GDis was found in avulsions (60% of all avulsed teeth), Intrusions (57%) and fractures of the alveolar process (46%).

Conclusion: As gingival attachment plays a critical role in periodontal healing, increased attention should be payed to the situation of the gingiva after dento-alveolar trauma.

EFFECT OF VEHICLE AND REMOVAL TECHNIQUE ON CALCIUM HYDROXIDE REMOVAL

Eymirli, Ayhan*, Uyanik, M. Ozgur; Calt Tarhan, Semra
Hacettepe University, Faculty of Dentistry
Endodontics
Ankara, Turkey

Keywords: Calcium hydroxide vehicles, calcium hydroxide removal techniques, stereomicroscope

Purpose: In traumatic injuries prior to root canal treatment, placement of calcium hydroxide is mandatory for inhibition of osteoclastic activity. However, calcium hydroxide must be removed from root canal before obturation, since, calcium hydroxide residue prevents sealer penetration to dentine tubules. The aim of this study was to compare the effects of different vehicles and removal techniques on calcium hydroxide removal.

Methods & Materials: 48 single rooted human teeth were used. After removal of crowns, root canals were prepared by using Protaper rotary nickel titanium system. The teeth were divided into two groups and root canals were filled with Calasept and Surepaste(n=24). After 7 days, calcium hydroxide was removed with %17 EDTA+Protaper F3 rotary file, %17 EDTA+Protaper F3 hand file and %17 EDTA (n=8). Then teeth were sectioned longitudinally, divided into two pairs and photographed by stereomicroscope(n=16). The ratio between calcium hydroxide to root canal surface was calculated. Data was analysed by multivariate analysis of variance.

Results: Results showed that, there was no differences between vehicles on calcium hydroxide removal($p>0,05$). When examining the removal techniques, %17 EDTA left significantly larger amount of residue. There was no differences between other two groups. Considering canal thirds, there was no differences between cervical and middle third, whereas larger amount of residue was found in apical third ($p<0,05$).

Conclusion: Type of vehicles do not effect calcium hydroxide removal whereas mechanical instrumentation with chemical irrigation remove calcium hydroxide better than irrigant only techniques.

VERTICAL-FRACTURE RESISTANCE OF ROOTS OBTURATED WITH NOVEL CALCIUM-SILICATE-BASED SEALERS

Güneser, Mehmet Burak*, Eldeniz, Ayce Unverdi**, Akman, Melek**, Baser-Kolcu, Inci**
*Bezmialem Vakif University **Selcuk University
Department of Endodontics
Istanbul, Turkey

Purpose: The aim of this study was to compare the fracture resistance of roots filled with the matched-taper single-cone or lateral condensation technique and different contemporary calcium-silicate based root canal sealers.

Methods & Materials: Eighty-two single-rooted extracted mandibular premolars were decoronated to obtain 13-mm root segments and randomly divided into 6 test-groups (n=12) and 2 control-groups (n=5). The buccolingual and mesiodistal diameters were measured. No statistically significant differences were found between the groups in terms of diameters. In positive-control group, roots were instrumented but not filled and in negative-control group roots were neither instrumented nor filled. The canals were instrumented using ProTaper System (Dentsply Maillefer, Ballaigues, Switzerland) up to a master apical size of F3. In Group1; MTA Fillapex (Angelus, Londrina, Brasil)+Single-cone Gutta-percha (GP), Group2; MTA Fillapex+Lateral condensation (LC), Group3; iRoot SP (Innovative Bioceramics, Vancouver, Canada)+Single-cone GP, Group4; iRoot SP+LC, Group5; BioRoot RCS (a new experimental root canal sealer, Septodont, France)+Single-cone GP and Group6; BioRoot RCS+LC. All root samples were incubated at 37°C and 100% humidity for 2 weeks for complete setting of the sealers. The roots within each group were embedded in acrylic molds and subjected to a vertical loading force (1mm/min) until fracture. The force required to fracture each sample was recorded and data were statistically (Kruskal-Wallis and Mann-Whitney U) analyzed.

Results: Highest fracture resistance was recorded for the negative-control group ($771.5\pm 269.3N$), Group3 ($629.9\pm 165.9N$), Group6 ($624.9\pm 153.7N$) and Group5 ($621.3\pm 145.0N$) with no significant difference between them ($p>0.05$), whereas the significantly lowest value was observed in positive-control group ($341.3\pm 110.1N$), Group1 ($455.4\pm 135.6N$) and Group2 ($499.7\pm 149.5N$) ($p<0.05$).

Conclusion: New calcium-silicate based sealer (BioRoot RCS) showed more potential to strengthen endodontically-treated teeth to a level comparable to that of intact teeth. Acknowledgements: The authors thank Septodont for their support with the supply of BioRoot RCS sealer

REVASCULARIZATION TREATMENT IN VARIOUS TRAUMA TYPE

Herdem, Güldag*, Cantekin, Kenan
Erciyes University
Pediatric Dentistry
Kayseri, Turkey

Keywords: immature teeth, revascularization, trauma

Purpose: Mainly pulp necrosis as a result of trauma is common in immature teeth, and the ideal treatment method for immature and necrotic teeth has not yet been determined. Therefore, the aim of this report was to present a case of pulp revascularization in an injured with various trauma type immature teeth.

Methods & Materials: In this study have been presented six children nine teeth with injured iatrogenic causes, intrusive luxation, extrusive luxation, related to deciduous tooth injured with trauma and affected permanent teeth. After clinical and radiographic examination, the teeth were defined as necrotic. Revascularization therapy was performed over multiple appointments. At the first appointment, the root canals were mechanically instrumented to the apices with a large apical size by using the step-back technique and irrigated copiously with antimicrobial solution. At the following appointment, the root canals were irrigated with antimicrobial solution, and bleeding was induced into the root canals by passing hand files beyond apices. Blood clot were placed cementum enamel junction. MTA was placed on the blood clot. Composite was used to restore the teeth. The resolution of apical radiolucency and regression of clinical signs and symptoms were observed at recall appointments.

Results: After long term control appointments, some cases showed healing of the periapical area and apical closure were seen to be complete. However, some cases have been failed. Apical closure were not seen to be completed. The teeth were treated with root canal.

Conclusion: Although revascularization can promote continued root development and root dentin apposition, long-term root canal treatment may be required due to treatment results with periapical inflammation in injured teeth with open apices.

INTENTIONAL REPLANTATION OF ADHESIVELY REATTACHED VERTICALLY FRACTURED MAXILLARY SINGLE-ROOTED TEETH

Kaval, Mehmet Emin*, Nizam Nejat; Kaval, Mehmet Emin; Gurlek, Önder; Atilla, Anil; Çaliskan Mehmet Kemal
School of Dentistry, Ege University, Izmir, Turkey
Endodontology
Izmir, Turkey

Keywords: vertical root fracture, intentional replantation

Purpose: To evaluate the clinical outcomes of intentionally replanted maxillary single rooted teeth with vertical root fractures (VRFs) after repaired extraorally using 4-Methacryloxyethyl trimellitate anhydride/ methacrylate-tri-n-butyl borane (4-META/MMA-TBB) resin cement.

Methods & Materials: Twenty one endodontically treated maxillary single rooted teeth with VRF were included in the study. After atraumatic extraction, fractured fragments were adhesively cemented and the teeth were then replanted. Plaque index (PI), gingival index (GI), probing depth (PD) and clinical attachment level (CAL) were assessed at 1, 6 and 12th months, and radiographic evaluations were made using PAI scoring system at baseline and 12th months. Mobility was evaluated using periotest values (PTVs) at baseline, 1, 3, 6 and 12th months. Clinical parameters of contralateral teeth were used as the control teeth in the statistical analyses.

Results: Two teeth were extracted by the end of 12th month. PI, GI, CAL and PD scores were significantly lower at all evaluation time points compared to baseline, without significant difference between the groups. PTV in test teeth were significantly increased after the intervention and decreased to baseline levels by 12th month. PTVs were significantly higher in test teeth ($p < 0.05$) during the follow up, except 12th month observation. PAI scores significantly decreased ($p < 0.05$) at 12th month compared to baseline.

Conclusion: Adhesive cementation of vertically fractured teeth together with intentional replantation seems to be an effective treatment strategy for endodontically treated maxillary single rooted teeth. Clinical parameters seem to be stable after 6th month, and tooth mobility is likely to decrease after replantation reaching to physiological limits by 12th month.

Thursday, June 19th

Session 5

Room: Malazgirt A (14:00-15:00)

EFFECT OF VARIOUS-IRRIGATION-PROTOCOLS ON DEBRIDEMENT AND APICAL-EXTRUSION IN REVASCULARIZATION PROCEDURES

Mese, Merve*, Arslan, Hakan; Akçay, Merve; Mese, Merve; Çapar, Ismail Davut; Karadede, Süeda
Izmir Katip Celebi University, Faculty of Dentistry
Pediatric Dentistry
Izmir, Turkey

Keywords: apical-extrusion, endovac, pips

Purpose: The aims of this study were to determine (i) the effect of various irrigation protocols on the quantity of residual debris, apically extruded irrigating solution and apically extruded debris, and (ii) the correlations among the predictor variables (amounts of residual debris, apically extruded irrigating solution, and debris) in teeth with immature apices.

Methods & Materials: Forty-eight mandibular premolars were apically and coronally sectioned 10 mm below the facial cemento-enamel junction (CEJ) and 5 mm above the facial CEJ to obtain a standardized length. The root canals were enlarged up to size 140 to simulate immature root apices. Radiopaque contrast medium (Metapex; Meta Biomed Co. Ltd, Cheongju, Korea) was placed into the root canals to simulate of intra-canal debris, and the specimens were irrigated with one of the following irrigation methods: a) 20 mL of physiologic saline irrigation with a 27-gauge notched-tip needle for 120 s, b) EndoVac (Discus Dental, Culver City, CA, USA), c) photon-induced photoacoustic streaming (PIPS), or d) a combination of PIPS and EndoVac. The quantities of the apical extrusion of irrigating solution and debris were evaluated using a microbalance (TW423L; Shimadzu, Tokyo, Japan) with a modified model, and the net weight of the extruded debris and irrigating solution was determined for each group. The residual debris was also calculated by measurement of radiopaque area. The resulting data were analysed statistically with one-way analysis of variance (ANOVA) and Pearson correlation analysis at a 95% confidence level ($P = .05$).

Results: PIPS and PIPS + EndoVac were found to be superior to EndoVac alone in terms of debridement efficacy ($P < .001$). A larger quantity of extruded debris and irrigating solution occurred in the needle irrigation group than in the EndoVac ($P < .05$). However, there were no statistically significant differences between the EndoVac, PIPS, and PIPS + EndoVac groups ($P > .05$). A moderately strong correlation was determined between the quantities of apically extruded irrigating solution and apically extruded debris ($r = .585$, $P < .001$).

Conclusion: The needle irrigation technique resulted in the highest quantity of extruded debris and irrigating solution. The PIPS technique appears advantageous for revascularization in terms of debridement efficacy and safety in respect of the possibility of apical extrusion.

PULP SURVIVAL RATE FOLLOWING COMPLICATED CROWN FRACTURES

Onetto, Juan*, Lopez, Carolina (1), Flores, Marie Therese (1), Uribe, Sergio (2)
(1) Faculty of Dentistry, Universidad De Valparaíso, Chile (2) School of Dentistry, Universidad Austral De Chile
Valparaíso, V Region, Chile

Keywords: Complicated crown fracture, pulp survival rate, prognosis

Purpose: To determine the pulp survival rate of permanent teeth with complicated crown fracture (CCF) after pulp capping or partial pulpotomy and the influence of root development, associated luxation injury, time elapsed to treatment and restorative procedures on the long-term pulp prognosis.

Methods & Materials: Retrospective cohort study. Information from a database of 199 records of patients with CCF who sought treatment or were referred for follow up to Children's Dental Traumatology Service, Universidad de Valparaíso, between 1991 and 2011 were analyzed. Root development, associated luxation injury (concussion or subluxation), time elapsed to treatment and restorative procedures (fragment reattachment or composite) was assessed. A minimum follow-up of 100 days and complete clinical and radiographical records were considered. Data were analyzed with MedCalc® v 10.2. Non-parametric univariate analysis (Fisher's exact test or chi square), logistic regression and Kaplan Meier survival analysis were applied. Level of significance was set as $p < 0.05$.

Results: Forty two patients aged 7-23 years with 47 teeth with CCF and vital pulp completed the inclusion criteria. 20 teeth with open apex and 27 with closed apex were included. 13 teeth had associated luxation injury. The follow-up period ranged from 4 to 214 months, with a median of 34 months. 34 teeth remain pulp vitality, 18 with open apex (4/18 associated luxation injury) and 16 with closed apex (4/16 associated luxation injury). 13 teeth development pulp necrosis, 2 with open apex (without associated luxation injury) and 11 with closed apex (5/11 with associated luxation injury). 3 vital teeth (all with associated luxation injury) exhibited pulp canal obliteration (PCO). Root development was the only variable significantly related to pulp vitality prognosis: $p = 0.02$ (exact Fisher's test); $p = 0.03$ (logistic regression; OR 0.16 (95% CI 0.03-0.86)). The median survival observed after applying Kaplan Meier analysis was 117 months (95% CI: 69-117) for the whole sample. None of the variables was significant for pulp survival rate.

Conclusion: Stage of root development affected pulp survival prognosis. Incomplete root development was considered a protective factor. PCO was not observed after CCF without associated luxation injury.

EFFECT OF VARIOUS IKI CONCENTRATIONS ON THE MTA ANTIMICROBIAL PROPERTIES

Saatchi, Masoud*, Hosseini, Hananeh Sadat) Farhad, Ali Reza) Narimany, Tahmineh)
School of Dentistry, Isfahan University of Medical Sciences, Isfahan, Iran
Endodontics
Isfahan, Iran

Purpose: Mineral trioxide aggregate (MTA) is a multi-purpose dental material with various uses in dentistry. Iodine potassium iodide (IKI) is the most commonly used iodine compound in endodontics. We aimed to assess the antimicrobial activity of tooth-colored ProRoot MTA combined with IKI.

Methods & Materials: The antimicrobial activity of IKI was assessed at three concentrations (1%, 2%, and 4%) as the mixing agents combined with MTA against *Enterococcus faecalis*, *Escherichia coli*, *Staphylococcus aureus*, *Pseudomonas aeruginosa*, and *Candida albicans*. For each microorganism, three plates were inoculated with 100 μ L of a microbial suspension (McFarland 0.5). Four wells were prepared in each plate. MTA (70 mg) was mixed with either of the three concentrations of IKI (25 μ L) or sterile distilled water (25 μ L) and placed in each well. The plates were incubated for 24 hours at 37°C. Zones of inhibition (ZOI) were measured in millimeters by a blinded observer. Data were analyzed using analysis of variance and the Dunnett t test.

Results: All MTA mixtures with water or IKI solutions showed inhibitory zones. The mean ZOI of each MTA/IKI mixture was not significantly different from MTA/water mixture ($P > 0.05$). MTA/1% IKI had smaller ZOI than MTA/water against *E. coli*, *E. faecalis*, and *C. albicans*. MTA/2% IKI showed larger ZOI only against *P. aeruginosa*. MTA/4% IKI showed larger ZOI against *P. aeruginosa* and *E. coli* ($P < 0.05$).

Conclusion: Substitution of IKI solutions (1%, 2%, and 4%) for water did not significantly increase the antimicrobial activity of MTA.

LATE REPLANTATION: A BIOLOGICAL CHOICE IN EXTREME SITUATIONS

Sievers, Denise*, Flores, Marie Therese (1); Onetto, Juan Eduardo (1); Mansilla, Julio (1); Uribe, Sergio (2)
(1) Universidad De Valparaíso, Chile (2) Universidad Austral De Chile
Pediatric Dentistry Department
Valparaíso, Región De Valparaíso, Chile

Keywords: avulsion, late replantation

Purpose: To analyze the survival rate of avulsed permanent teeth that had been replanted after one hour of extraoral dry time and to relate the variables that influence their prognosis.

Methods & Materials: Records from thirty-one patients with thirty-eight avulsed permanent teeth replanted after one hour of extraoral dry time registered at the Dental Traumatology Service, Universidad de Valparaíso database, were selected and analyzed. All patients -except one- were referred from diverse dental care settings at different times after replantation. The period considered was January 1990 to November 2013. Only teeth that had been remained dry for one hour or more before replantation and had complete information were considered for this study. Variables such as age, root development in Moorrees scale, time until replantation and type of endodontic procedure performed (no pulp extirpation-calcium hydroxide-endodontics) were analyzed. The outcome studied was the radiographic root resorption index (RRRi) according to Andersson et al (1989). A survival analysis was performed with Kaplan Meier method. It was applied considering the radiographic detection of inflammatory resorption (IR) or replacement resorption (RR) as endpoint. Level of significance was set as $p < 0.05$.

Results: Age range was 6 to 21 years old, with an average of 10 years. Fifteen teeth had root development =5 according to Moorrees. Four teeth did not exhibit IR nor RR; two of them showed bone ingrowth and one of them arrested root development. The radiographic detection of IR or RR ranged from 1 to 180 months, with a median survival time of 24 months. Stage of root development; use of antibiotics; type of endodontic procedure performed and RRRi as factor codes were not significantly associated.

Conclusion: Late replantation in young permanent teeth can be considered for the patient's best interest when early replantation was not performed. This study shows evidence of reasonable outcomes of late replantation as a first choice of treatment. It returned in a quick way the patient's esthetics and function. It is well-known that those teeth will develop infra-position and/or root resorption in the long term. However, this is a chance of giving the patient time to prepare for the final treatment.

DECISION-MAKING IN DIAGNOSIS, TREATMENT PLANING AND FOLLOW-UP USING CBCT

Sirandoni, Giglia*, Naranjo, Ramón (2); Onetto, Juan Eduardo (1)
Faculty of Dentistry, Universidad De Valparaíso, Chile
(1) Pediatric Dentistry; (2) Oral Radiology
Valparaíso, Valparaiso, Chile

Keywords: CBCT, Diagnosis, Treatment Planing

Purpose: To analyze complex trauma patients with mixed and permanent dentition related decision-making in diagnosis, treatment-planing and follow-up using CBCT.

Methods & Materials: A case series study. In a complex trauma patients group between 9 and 22 years old CBCT was taken in different moment depending on dental trauma situation request. Three groups were identify: Diagnosis; CBCT previous first patient care (2) Treatment-planing; after the emergency treatment (8) Follow-up; for treatment assessment. (18)

Results: In total 28 cases were analyze. In diagnosis; 2 cases with complex luxations. In treatment-planing; 4 crown-root fracture with pulp exposure, 4 mixed trauma. In follow-up; 6 avulsion; 1 luxation, 1 intrusion, 1 root fracture, 2 crown-root fracture with pulp exposure and 7 development disturbances.

Conclusion: CBCT demonstrate to be a useful tool in diagnosis, treatment-planing and follow-up in complex trauma in mixed and permanent dentition.

MANAGEMENT OF ACUTE DENTO-ALVEOLAR INJURIES

Terro, Wahid*, Khoury Albert
Private Practice
Beirut, Beirut, Lebanon

Keywords: Dento-alveolar, repositioning, trauma

Purpose: Traumatic injury to the periodontal tissues namely, avulsion, extrusive, intrusive and lateral luxation is a serious problem in both primary and permanent dentition that could result in disfiguration and occlusal problems; and in some complex cases might cause disturbance of facial and jaw growth. Past and recent concerns have been focusing on the effectiveness of atraumatic repositioning of the extrusive or intrusive tooth and re-plantation of avulsed tooth when possible. In this presentation, a series of clinical cases of traumatic injuries to the periodontal tissues and the possible treatment plans including repositioning of the extruded/ intruded tooth and re-plantation of the avulsed tooth will be discussed.

Methods & Materials: Four patients, three children and one adult (2 females and 2 males) presented to the emergency room with traumatic injuries to the periodontal tissues. The treatment philosophy was based on atraumatic repositioning of the extrusive / intrusive tooth and re-plantation of avulsed tooth when possible. The follow-up time was 6 months to 10 years.

Results: In one patient, re-plantation and repositioning were not feasible in both the mandible and the maxilla. In the second patient, re-plantation was also not viable but the intrusive tooth was successfully repositioned in the maxilla. In the third and fourth patients repositioning of the extrusive and intrusive teeth was a successful treatment with a long follow-up period.

Conclusion: A minimal invasive surgical technique including repositioning of extrusive and intrusive teeth in acute traumatic injuries of the periodontal tissues could be an acceptable treatment method.

Thursday, June 19th

Session 6

Room: Malazgirt A (15:00-16:00)

ANTIMICROBIAL EFFECT OF TAUROLIDINE AND N-ACETYLCYSTEINE ON ENTEROCOCCUS FAECALIS PHENOTYPES

Ulusoy, Ayca Tuba*, Kalyoncuoglu Elif, Reis Ahu, Erturk Murat
Ondokuz Mayıs University Faculty of Dentistry, Karadeniz Technical University Faculty of Medicine,
Antigen-Cell Biotechnology Company
Department of Endodontics, Department of Microbiology
Samsun, Turkey

Purpose: To investigate and compare the antimicrobial activity of Taurolidine and N-Acetylcysteine (NAC) on biofilm and planktonic enterococcus faecalis phenotypes.

Methods & Materials: The minimum inhibitory concentration (MIC) and minimum bactericidal concentration (MBC) of Taurolidine and NAC were determined using broth microdilution. Calcium hydroxide (CH) paste, sodium hypochlorite (NaOCl) and chlorhexidine (CHX) were used for comparisons. Thereafter, the ability of dentin powder to neutralize the antibacterial activity of Taurolidine and NAC was examined. The efficacy of Taurolidine and NAC on *E. faecalis* biofilms was examined quantitatively by exposure of 21-day old *E. faecalis* biofilms on dentin disks. The cytotoxicity of human dental pulp fibroblast cells in contact with the extracts was evaluated by MTT assay.

Results: The MIC and MBC of Taurolidine, NAC and CH were not affected by preincubation in dentin powder. As verified by qualitative assay of the *E. faecalis* biofilms, CH was the strongest bactericidal agent at all test dilutions, regardless of the presence of dentin powder. The antibacterial effect of Taurolidine and NAC was significantly lower than that of CH at all test dilutions. At 48 h of incubation, all test agents showed similar, but high levels of cytotoxicity.

Conclusion: Within the experimental conditions of the present study, Taurolin and NAC exhibited significantly inferior antibacterial action on biofilm and planktonic enterococcus faecalis phenotypes, and thus do not appear to offer any advantage over CH.

REGENERATIVE ENDODONTIC (REVASCULARIZATION): REVIEW OF LITERATURE

Mousavi, Seyed Amir*
Isfahan Dental School, Isfahan University of Medical Sciences, Isfahan, Iran
Assistant Professor of Endodontics Department,
Isfahan, Iran

Purpose: An immature tooth with pulpal necrosis presents a challenge to the endodontist. Endodontic treatment options consist of apexification, apical barrier or more recently revascularization. Revascularization is a regenerative treatment and a biologically based alternative approach to treat necrotic immature teeth which allows continuation of root development. Endodontic regenerative treatments are based on Stem Cells from Apical Papilla. This article discusses the differences between these methods, and the influences of the selected method on the quality of root development. On the other hand new technical modifications in bleeding induction step and new materials for sealing the blood clot will be discussed by presenting the related cases.

Methods & Materials: A review of literature was performed by using electronic searches of MEDLINE and Pub Med databases from 1990 to 2012 with mesh keywords.

Results: Triple antibiotic paste is composed of metronidazole, ciprofloxacin, and minocycline. The paste was first tested for its effectiveness against *E. coli* infected dentin. This method is a kind of regenerative process in necrotic immature canals which, instead of apexification with MTA, calcium hydroxide and/or other materials, irritation of the periapical region is done so that the mesenchymal cells of the Hertwig sheath may induce tooth root formation and cause the tooth root wall to become thicker.

Conclusion: This treatment approach offers the clinician great potential to avoid the need for traditional apexification with calcium hydroxide or an artificial apical barrier with MTA. Also this procedure can treat necrotic immature teeth by physiologically continued root development and strengthening the root wall, so revascularization technique can be effective for managing necrotic immature teeth with appropriate case selection.

THERAPEUTIC SUGGESTIONS FOR COMPLICATED HORIZONTAL ROOT FRACTURES

Sheikh Nezami, Mahshid*, Mokhber, Nima Shamsian, Khosro Saket, Salman
Academic Center for Education, Culture, and Research/Mashhad/Iran
Dental Trauma Clinic
Mashhad, Khorasan-Razavi, Iran

Purpose: The coincidence of various complications with horizontal root fractures can adversely influence their otherwise favorable prognosis. These complicating factors include dislocation and/or severe mobility of the coronal fragment, concomitant alveolar/crown/crown-root fractures, pulpal exposure, delayed / inappropriate treatment plan at first visit, and deep periodontal pocket. This study evaluated radiographic and clinical outcomes of treatment on horizontally root-fractured permanent teeth, focusing on the management of some complicated cases, for which there are few guidelines.

Methods & Materials: A number of root-fractured teeth (n: 98) were followed up between 6 and 60 months after repositioning and splinting. Vital pulp therapy as a conservative endodontic intervention was carried out prophylactically for six cases with additional complicated crown/crown-root fractures in order to prevent non-healing process at fracture lines. Therapeutic/delayed endodontic treatment (Calcium hydroxide dressing and MTA plugs) was performed only for coronal fragments in cases with non-healed fractures. Prolonged and even permanent splinting was considered for 20 teeth with severe mobility.

Results: Healing was achieved in 51 teeth following 1-4 months of splinting (either type I, II or III). Non-healing pattern, caused by necrotic coronal pulps, was seen in the remaining 47, among which 28(60%) teeth were complicated by at least one of the above mentioned complications. Endodontic intervention for these non-healed cases yielded healing in 33 cases, however, five teeth were lost and nine failed to attend further recall (success rate of 94%).

Conclusion: Suggested therapeutic strategies in order to achieve favorable outcome in complicated horizontal root fractures are: Vital pulp therapy for exposed/inflamed coronal pulps at emergency visit, Placing MTA plugs at non-healed fracture lines, Prolonged/permanent splinting in case of severe mobility.

TRAUMATIC DENTAL INJURIES AMONG CHILDREN IN GULHANE MEDICAL ACADEMY, TURKEY

Akgun, Ozlem Marti*, Yildirim, Ceren; Acar, Ozge; Guven Polat, Gunseli; Altun, Ceyhan; Basak, Feridun
Gülhane Medical Academy
Department of Pediatric Dentistry
Ankara, Turkey

Keywords: Dental trauma, etiology, treatment

Purpose: The purpose of this study was to evaluate etiology, sex distribution, types of traumatic dental injuries and treatment modalities in patients who referred to Gulhane Medical Academy, Pediatric Dentistry Department, Ankara, Turkey.

Methods & Materials: The study was based on the clinical data of 822 (age: 0-14) children applying to the Department of Pediatric Dentistry. Fifty-nine children (7.2%) were found to have suffered dental injuries during a period of 6 months. Injuries were classified according to drawings and texts based on classification system of Andreasen and Andreasen. The causes and localization of trauma, traumatized teeth classification and treatment were evaluated both primary and permanent teeth.

Results: The most common type of injury was crown fractures (76.2%), subsequent to crown fractures avulsion (6.6%), subluxation (5.2%), conclusion (5.2%), intrusive luxation (3.4%), root fractures (1.7%) and extrusive luxation (1.7%) respectively. The most frequently injured teeth were permanent teeth (76,3%), and the most common cause of dental trauma was falling (77.9%). Sixteen point nine percent of traumatized permanent teeth had incomplete root formation. Injuries were found to occur more frequently at school (37.2%). A significant gender influence on the occurrence of dental trauma was observed, with more boys (59.3%) experiencing dental trauma than girls (40.7%). Restorative treatment had been applied in 24 (44.1%) patients, endodontic treatment and extraction had been performed in 15 (25.4%) patients.

Conclusion: Traumatic dental injuries are highly prevalent among school children. According to the results of this study fall is the major cause for dental traumas. Most of the dental traumas involve only tooth enamel. The correct diagnosis of dental injuries is important for eliminating the occurrence of complications.

AVULSION INJURIES PRESENTING AT KINGS COLLEGE HOSPITAL DENTAL INSTITUTE

Djemal, Serpil*, Mubeen, Suhaym ; Patel, Maalini; Gohil, Tanika; Hughes, Sophie
Kings College Hospital Dental Institute
Restorative Dentistry & Traumatology
London, United Kingdom

Keywords: avulsion, dental trauma, epidemiology

Purpose: Avulsion injuries are unfortunate, painful and distressing events which, if managed inappropriately, may have life-long oral health, psychosocial and economic consequences. In addition to the long established paediatric trauma service at King's College Hospital, Kings is the first dedicated centre for treating acute dental trauma in adults in the UK. The aim of this report is to describe the incidence, aetiology, clinical presentation and management of avulsion injuries experienced at Kings College Hospital over an 18-month period.

Methods & Materials: Retrospective data was collected from the clinical records of patients presenting between February 2012 and October 2013.

Results: In the paediatric group the main aetiological factor was a fall whilst in the adult group, it was due to an assault. The age range of patients presenting with avulsed teeth was 7 – 75. The paediatric group consisted of 7 males and 7 females; the adult group consisted of 22 males and 13 females.

In the paediatric group of 14 patients avulsed 17 teeth; 12 avulsed one tooth and 2 patient avulsed 2 teeth.

In the adult group of 35 patients, 26 avulsed 1 tooth, 8 avulsed 2 teeth and 1 patient avulsed 3 teeth, giving a total of 43 teeth.

In both groups the most commonly avulsed tooth was the upper right central incisor, 10 in children & 13 in adults.

In 17 adult patients 23 teeth were replanted. In 9 children 10 teeth were replanted.

The main reason for not replanting an avulsed tooth was that the tooth was not found.

All replanted teeth were splinted with orthodontic wire and composite and prophylactic antibiotics were given.

Root canal treatment was instituted from 2 weeks to 7 weeks after replantation.

Thirteen of the 17 teeth in children have been retained to date, 4 have been replaced with a partial denture. Two teeth have remained vital.

Fourteen of the 23 adult teeth have been retained to date, 6 have been replaced (partial denture or implant) and 4 have been lost to follow up.

Conclusion: The most common aetiology for avulsion of teeth in children is a fall and assault in adults. From early results in both groups it is apparent that extended extra oral times and dry times of over 1 hour resulted in decreased prognosis for avulsed teeth.

PREVALENCE OF TRAUMATIC DENTAL INJURIES AMONG PRESCHOOL CHILDREN IN JORDAN

Elkarmi, Rawan*, Hamdan, Mahmoud. Rajab, Lamis. Abu-Ghazaleh, Suha. Sonbol, Hawazen
Trinity College Dublin
Paediatric Dentistry
Dublin, Ireland

Purpose: To evaluate the prevalence of traumatic dental injuries to primary teeth among preschool children in Amman (Jordan). In addition, the relationship between dental trauma and gender, preschool type, parental education level, overjet, overbite, and lip coverage was investigated.

Methods & Materials: A cross sectional population based study was performed by paediatric dentists on a total of 1198 children attending 39 preschools randomly selected from different areas of Amman. Chi square test and stepwise regression modeling were used for a statistical analysis.

Results: The prevalence of dental injuries was (26.4%). The upper incisors were more likely to sustain dental trauma (91.7%). No statistically significant association was established between dental trauma and any of the socio-demographic variables. The most common type of dental trauma was enamel fracture (43.1%) followed by pulp injury (39.1%). The odds ratio suggested that the risk of dental trauma was 1.89 times greater if the overjet was > 3mm, 1.39 times greater if the child had an anterior open bite and 2.56 times greater if the child had inadequate lip coverage. Many parents were unaware of the original dental injury and only 25.3% of children diagnosed with dental trauma had attended a dentist.

Conclusion: The prevalence of dental trauma is similar to that reported in other countries. The importance of preventing dental trauma and treating it promptly needs to be conveyed to parents and to medical/dental care providers.

Thursday, June 19th

Session 7

Room: Malazgirt A (16:30-17:30)

IS PANORAMIC RADIOGRAPHY SUFFICIENT FOR DIAGNOSIS OF MANDIBULAR CORPUS FRACTURES?

Ersan, Nilüfer*, Ilgüy, Mehmet
Yeditepe University Faculty of Dentistry
Department of Dentomaxillofacial Radiology
Istanbul, Turkey

Keywords: Mandibular corpus, maxillofacial fractures, cone beam computed tomography

Purpose: Diagnosing mandibular fractures on panoramic radiographs (OPG) may be difficult because of its location and anatomic characteristics, that some fractures are not readily apparent when the X-ray beam is not passing through the plane of the fracture. The purpose of this case study is to illustrate and discuss the diagnostic efficacies of OPG and cone-beam computed tomography (CBCT) scans for accurate diagnosis of mandibular corpus fractures.

Methods & Materials: We describe three cases of mandibular corpus fracture that presented our Dentomaxillofacial Radiology clinic after traumatic injury. Case 1: 33-year-old woman had a trauma to her mandible due to a fall two days before admission. Clinical examination revealed that she did not have pain but had a limited mouth opening. Case 2: 25-year-old man had a car accident the day before his admission. Clinical examination revealed that he had spontaneous pain, limited mouth opening and open-bite in the right posterior region. Case 3: 58-year-old edentulous woman who had a trauma to her mandible due to a fall five days before admission. She had swelling and pain in right posterior mandible region. All the patients were referred for radiological imaging at first with OPG, which revealed any fracture in the mandibular corpus, and then with CBCT.

Results: CBCT images were gathered with Iluma CBCT Scanner (Imtec Corporation, Oberursel, Germany). Case 1: CBCT images revealed an incomplete fracture in the left mandibular corpus, extending lingually from the distolingual side of the third molar to the right parasymphiseal region. The fracture was fragmented in the distal side of third molar, whereas not fragmented in the parasympheseal region. Case 2: CBCT images revealed a complete fracture in left parasymphiseal region extending beyond an impacted canine tooth. Case 3: CBCT images revealed an incomplete fracture in right mandibular corpus without a dislocation. All the patients were referred to oral surgery clinic for the treatment.

Conclusion: This report accentuates that panoramic radiographs may be misleading for accurate diagnosis of mandibular fractures. With regard to the mandibular corpus fractures we suggest that CBCT is superior to panoramic radiography and is crucial and should be mandatory for all suspected mandibular fractures instead of routine radiography in maxillofacial trauma patients.

ADHERENCE TO THE IADT TRAUMA MANAGEMENT GUIDELINES BY PEDODONTISTS

Geraldino, Rogério*, Barbosa, Camila; Garcia, Fernanda; Almeida, Júlio César
Universidade De Brasília
Dentistry
Brasília, Distrito Federal, Brazil

Keywords: primary dentition, dental trauma, professional knowledge

Purpose: The aim of the study was to evaluate the level of knowledge and attitudes of professionals who work with pediatric dentistry in dental trauma affecting the primary dentition.

Methods & Materials: Dentists participating on the Brazilian Congress on Pedodontics, which took place in Brasília/Brasil, were asked to answer a questionnaire regarding their knowledge and attitudes on dental traumatology. Factors considered included time since graduation, formal expertise, professional acting field and management of dental trauma.

Results: 117 questionnaires were returned. The professional profile results showed a majority of specialist pediatric dentist (56,41%), followed by MDS (12,81%) and post-graduation students (11,97%). The participants were mostly graduated from 6 to 10 years long (22,22%), followed by those who were graduated from 16 to 20 years long (20,51%) and from 11 to 15 years long (17,95%). Their main professional work were pedodontics (65,81%), general dentistry (9,40%) and collective health (3,42%). Questions concerning knowledge and management of uncomplicated crown fracture showed a preference for bonding the fragment (79%), followed by a 12% preference for restore the tooth with composite resin and 9% preference for sealing the exposure with glass-ionomer. Asked about their management on lateral luxation, intrusion and extrusion in deciduous teeth with incomplete root formation, 79,59% answered that would wait for its spontaneous reposition, 17,35% would reposition it in minor lateral luxations and extrusions, 2,4% would always reposition it and 1,02% would always extract it. In case of avulsed teeth with complete root formation and appropriate storage media, 42,20% chose to replant it immediately and later root canal treatment and 41,28% chose not to replant it. 79,46% of the professionals would use splint to stabilize alveolar fracture, 66,67% would use it to stabilize avulsed teeth and 56,36% would use splint to stabilize root fracture. 47,83% of professionals would use systemic antibiotics if the patient has some systemic involvement, 33,04% would use it in luxated and avulsed teeth, 9,57% would never use antibiotics and 4,35% would use antibiotics in any dental trauma.

Conclusion: The results show a limitation of knowledge about the treatment protocol in cases of dental trauma in primary teeth prepared by the International Association of Dental Traumatology – IADT.

PREVALENCE OF DENTAL TRAUMA AMONG PRIMARY SCHOOL CHILDREN IN IRAN

Ghoddusi, Jamileh*, Rouhani, Armita; Akbari, Majid; Movahed, Taraneh; Mohiti, Younes
Mashhad University of Medical Sciences
Endodontics
Mashhad, Iran

Keywords: Dental trauma, Permanent dentition, Primary school

Purpose: the aim of this study was to determine prevalence, etiology, type of trauma, teeth involved, place of injury and treatment received after traumatic dental injuries (TDI) in school children in north-east of Iran at year 2012, and evaluate the relationship between TDI and anatomic predisposing factors such as over jet and lip coverage.

Methods & Materials: A total of 778 school children were clinically examined for signs of trauma to their permanent teeth and the amount of over jet and lip coverage were also recorded. A questionnaire containing demographic data of participant and history of the dental trauma was given to the parents.

Results: 178 of the 778 children showed signs of previous trauma to permanent teeth making a prevalence of 22.9%; of which 26.1% were boys and 18.9% girls. There was a significant difference between two sexes ($p=0.017$). Type of injury in 46.1% of children was luxation injuries, 37% crown fractures, and 16.9% avulsion. Maxillary central incisor was the most commonly affected tooth (84%) followed by mandibular central incisor. There was a significant relationship between TDI and over jet ($P=0.02$) in permanent teeth. On the other hand, there was no statistically significant relationship between TDI and lip coverage. The most common cause of TDI was fall (42.9%) followed by fight (34%). Majority of the traumas happened at home (46.8%) and school (29.9%). 62 (39.7%) of children with TDI, did not receive any type of dental or medical care.

Conclusion: Due to the high prevalence of dental trauma in school children in Iran, it is highly recommended to plan a trauma prevention community targeting parents, children and school staff and also provide treatment to TDIs to prevent their biologic and psychologic consequences.

IN VIVO” COMPARISON AMONG PERIAPICAL, PANORAMIC X-RAYS AND CONE-BEAM

Herbel, Albina*

University of Salvador AOA

Traumatismos

Buenos Aires, Capital Federal, Argentina

Keywords: Traumatic dental injuries (TDIs), imaging, cone-beam computed tomography (CBCT)

Purpose: The purpose of this study was to analyze the diagnostic accuracy of intraoral periapical, panoramic X-rays, and cone-beam computed tomography (CBCT) “in vivo” in the detection of traumatic dental injuries (TDIs) and their consequences. 228 images were evaluated, 76 TDIs and/ or their sequelae being observed. The result showed a significant difference in diagnostic sensitivity in detecting TDIs, it being 0.58 in panoramic X-rays, 0.76 in periapical X-rays and 1 in CBCTs.

Methods & Materials: Materials and Methods The TDIs and/ or their sequelae were assessed in 228 imaging tests done on 76 patients. 76 tests consisted of periapical X-rays, 76 were panoramic X-rays, and 76 were CBCTs. To be able to make the comparison among such tests, all periapical X-rays were taken by the same professional, and panoramic X-rays and CBCTs were performed in the same institution. The study was conducted at University of Salvador / Argentine Dental Association (AOA). Four observers experienced in TDIs evaluated the three methods. To assess inter-rater agreement and certify that the data were not obtained at random, Cohen's kappa coefficient was used.

Results: The patients average age was 21, the age range being 5-64, 37 patients being male and 39 female. In panoramic X-rays, the average of positive diagnosis by images was 59%, and the average of negative diagnosis by images was 41%. In periapical X-rays, the average of positive images was 76%, and 24% negative. In CBCT the positive diagnosis by images was 100%.

Conclusion: 1) TDI detection differs significantly depending on the imaging method used (from 62% to 100%) . 2) Panoramic radiography is not a good method for diagnosis as it does not provide diagnostic accuracy. 3) Periapical radiography, due to its results, accessibility, lower cost and radiation exposure is the method par excellence for an initial diagnosis. 4) CBCT enabled us to reach an accurate diagnosis in all injuries. 5) Its implementation is recommended as a method of study in specialists' training schools.

INJURY CERTIFICATION AND DENTOALVEOLAR TRAUMA: A CHALLENGE

Hermosilla, Blanca*, Contreras, Claudia

Servicio Médico Legal

Clínica De Lesiones Odontológicas Y Máxilo Faciales

Santiago, Chile

Purpose: The aim of this study was to determinate the percentage of patients referred from courts during 2007, to identify the percentage of dental and maxillofacial injury and Dentoalveolar Trauma (DAT). Also, to study some epidemiological characteristics of patients, the legal medical prognosis of their injuries and the percentage that had Oral and Maxillofacial injuries (OMF) and was not recorded in the first attention on corresponding health centers.

Methods & Materials: Medical records of 6,903 patients, referred from courts in 2007, were reviewed. The presence of OMF injuries was established as inclusion criteria, so the sample for this study finally consisted in 680 cases. The data were analyzed through a program of basic descriptive statistical and the percentage of total OMF injuries, age distribution, sex, cause of injury, legal medical prognosis were determined. DAT rate was studied from total specialty.

Results: 63% of the patients studied, were male and 67% were between 15-45 years old. 10% (680) had OMF injuries. 43% of these had serious injuries and 24% less severe, while 18% had no accredited injuries. The main cause of injury was assault (57%), followed by traffic accidents (28%). 38% of the OMF injuries evaluated had TAD, with 22% of non-accredited injuries.

Conclusion: From 680 patients who had some type of injury in the OMF territory, there were 124 patients (18%) whose lesions were not recorded in the first attention. This shortcoming in the documentation of injury is attributable to the lack of dental specialists in a significant number of primary care centers and emergency services in our country. Without the initial medical record of the injury, which links it with the timeline of the penal investigation, it is not possible to accredit the lesion and therefore perform the corresponding legal medical prognosis, which impedes the administration of justice in all its merit. On the other hand, the lack of opportune documentation of DAT lesions produces a referral and late care of this condition, with the consequent deterioration of the clinical prognosis, complication of treatment, of rehabilitation and in the control of aftermath.

DENTAL INJURIES IN PRIMARY TEETH - EPIDEMIOLOGICAL STUDY

Luca, Rodica*, Munteanu, Aneta, Farcasiu, Catalina, Farcasiu, Alexandru-Titus
Carol Davila University
Pediatric Dentistry
Bucharest, Romania

Purpose: The aim of the study was to analyze type and sex and age distribution of traumatic dental injuries in primary teeth in children referred to Pediatric Dentistry Department, Carol Davila University, Bucharest (Romania) during 2010-2013.

Methods & Materials: A cross-sectional study on a sample of 95 children (55 boys) aged between 1 and 6 years (mean age=2.80±1.33 years) with a total of 137 injured teeth was performed. Age, gender, affected teeth, type of injury, etiologic factors, place where the injury occurred, treatment and time interval between injury and treatment were registered for each patient. Traumatic dental injuries were diagnosed according to Andreasen's classification (1994). Data were analyzed using ANOVA and independent variables T-test ($p < 0.05$).

Results: Traumatic injuries were higher in children aged between 1 and 3 years (80%), children aged 1 years being most affected. All types of dental traumatic injuries, except concussion, were found. The most prevalent types of injuries were: subluxation (18.24%), intrusive luxation (16.78%) and lateral luxation (15.32%). There was correlation between types of injuries and age ($p = 0.018$) and no significant relationship with gender ($p = 0.365$). Dental fractures were more frequent in children aged 1 year, while luxations injuries in older children. Trauma affected only front teeth, except one case – one lower primary first molar. Most of the traumatic injuries affected only one tooth (65.3%), 2 teeth were injured in 28.4% of cases and seldom 3 or 4 teeth (6.4%). Upper central incisors were the most affected teeth (81.75%). Children aged 4 and 6 years presented significantly more affected teeth than children aged 1 and 2 years ($p < 0.05$). There were statistically non-significant differences between sexes regarding the mean number of traumatized teeth ($p = 0.141$). Falling was the predominant etiologic factor (81.1%) and 56.8% of traumatic incidents occurred inside the house or kindergarten. Treatment usually occurred within first 7 days after the injury (78%). The most common treatment was monitor-only. Complications (necrosis) were observed in 15.32% of injured teeth.

Conclusion: 1) Gender had no influence on type of trauma and number of affected teeth; 2) A correlation was found between type of injury and age, dental trauma being more frequent in children aged 1-3 years; 3) It is necessary to inform parents and educators regarding the high frequency of dental trauma in small children and about the necessity of early treatment and repeated follow-up visits to avoid and minimize complications. Key-words: trauma, primary teeth, epidemiology

Thursday, June 19th

Session 8

Room: Malazgirt A (17:30-19:00)

INTERNATIONAL DENTAL TRAUMATOLOGY GUIDELINES: THE KNOWLEDGE AND APPLICATION

Rhouma, Ousama*, Al-Terhouni, Aya; El- Jedaeme, Samira; Al- Wejaih, Magda; Albishty, Emal;
Al- Khouja, Essam
The University of Zawia
Dental School, Paediatric Dentistry Department
Zawia, Libya

Purpose: The purpose of this study was to assess the application of, and the knowledge about International Association of Dental Traumatology (IADT) guidelines for the management of traumatic dental injuries held by a group of dentists working at Libyan setting

Methods & Materials: A questionnaire comprised of 15 objective questions regarding application and the knowledge about the guideline was distributed (n=120) (at five private dental clinics, one public clinic and one dental hospital)

Results: Only 90 questionnaires were properly filled and collected. The results were expressed as frequency and percentage of respondents for each question. Results: Among the 90 participants, 56 have 5-10 years of experience. 82% of them are providing oral health care at the frontline (at university hospital and private clinic), 40 % of them were not aware with the importance of the treatment guidelines and based their treatment plane on their own personal experience while only 14% are using the guideline. 20% of those who are not using the treatment guideline have no idea about it and 13% of them complaining the availability

Conclusion: The results showed lacking in knowledge regarding IADT treatment guideline and its importance. The continuing education courses and workshops are necessary to increase the level of knowledge about dental traumatology guidelines

PULP NECROSIS IN PERMANENT TEETH WITH ENAMEL- DENTIN CROWN FRACTURE

Rodríguez Salinas, Carolina Elizabeth*, Hernandez, Mónica; Ortiz, María Eugenia;
Mac-Lean, Barbara
Universidad Austral De Chile
Instituto De Odontoestomatología
Valdivia, Región De Los Ríos , Chile

Purpose: Pulp necrosis is a frequent complication in teeth with enamel-dentin-pulp crown fracture. However it is rather low in teeth with enamel-dentin crown fracture (EDCF), especially if they present immature root development. The present study aims to determine frequency of pulp-necrosis (PN) due to EDCF presenting as only dental injury. Time elapsed between date of trauma and development of PN was established.

Methods & Materials: Descriptive study. Dental trauma records (1218) from patients that attended the Dental Service of the General Public Hospital, Valdivia, Chile between 2007/01-2013/05 were reviewed. In this study, 330 patients with EDCF in permanent incisors (509) were analyzed. Inclusion Criteria: Patients were included in the study if they presented only one type of injury (EDCF), had an initial x-ray examination and had attended at least one follow-up control. A total of 255 patient records (178 male, 77 female), with 323 permanent incisor teeth fulfilled the inclusion criteria. Injured teeth were classified into two categories according to their stage of root development: mature root development (MRD) and immature root development (IRD). Descriptive statistical analysis: SPSS 19 was used.

Results: Out of the 323 teeth with EDCF, 213 teeth (66%) had MRD, and 110 teeth (34%) had IRD. Our study found that 42 (13%) of all teeth with EDCF developed PN. Pulp necrosis was found in 10 (24%) of teeth with IRD, and in 32 (76%) of the teeth with MRD. Time elapsed between date of trauma and PN for teeth with IRD was median 10 month, for MRD teeth was median 3 months.

Conclusion: The frequency of PN in teeth with EDCF was 13%. Pulp necrosis is more frequent and develops faster in permanent teeth with MRD than in permanent teeth with IRD. We strongly suggest that dental trauma patients should be informed of the importance of follow-up controls to detect possible late complications as pulp necrosis.

CHILDHOOD AGGRESSION AS A RISK FACTOR FOR INJURY REPETITION

Skrinjaric, Tomislav*, Gorseta, Kristina; **Skrinjaric, Ilija**; **Verzak, Zeljko**; **Galvina, Domagoj**
School of Dental Medicine, University of Zagreb
Department of Paediatric Dentistry
Zagreb, N/A, Croatia (Hrvatska)

Purpose: Child or host factors play an important role in occurrence of traumatic dental injuries (TDI) and can be associated with increased risk for injury repetition. Previous studies have revealed that increased risk for injuries might be associated with child's hyperactivity and aggressive behaviour but very few studies have analysed association of injury repetition and child's aggressive behaviour. The aim of this study was to examine the association of some host characteristics and repetition of injuries among a cohort of children with TDI. We hypothesized that children with repeated injuries would be more aggressive than those with single injury.

Methods & Materials: The host characteristics were analysed in the sample of 157 patients (103 males and 54 females) with TDI. Patients ranged in age from 3-17 years and were divided in three groups: 3-8 years, 9-11 years, and 12-17 years. The sample comprised children with single injury (SI) and with repeated injuries (RI). Child characteristics that have been analysed include behaviour, gender, and age. The Overt Aggression Scale (OAS) was used to assess and quantify the severity of aggression in children. The OAS defines four categories of aggressive behaviours: 1) verbal aggression, 2) physical aggression against objects, 3) physical aggression against self (self-injurious behaviour, and 4) physical aggression against others.

Results: Males in all age groups displayed higher level of physical aggression and have 2.7 times higher risk for injury repetition than females (OR = 2.721; 95% CI = 1.350 – 5.484). Aggressive behaviour in males with RI and aggression against others were significantly higher in age groups 9 – 11, and 12 - 17 years. Males with RI displayed significantly higher aggressive behaviour than males with SI ($x_2 = 6.36$; $P = 0.012$). Females with RI in all age groups showed similar level of physical aggression. Males aged 12-17 years with high aggression score (AS) have 7 times higher risk for injury repetition than males with lower AS (OR = 7.00; 95% CI = 1.185 - 41.360).

Conclusion: The host characteristics as high level of physical aggression, age, and gender have significant influence on injury repetition. Our results provide evidence that higher level of total physical aggression and aggression against others play significant role in etiology of dental injuries and injury repetition in children. The use of OAS in children with TDI could be of help to identify individuals at risk for injury repetition and to select children for preventive counselling.

LATE INTERVENTION CAUSES MORE ATTENTION

Sönmez, Cihan Alp*, **Osman, Fatma Bahar Borbay Akgül**, **Sevil Kahraman**, **Kamil Gezgin**, **Onur Bag**,
Irem Can, **Seda Öner**, **Ela Akman**, **Hayri Botsali**, **Murat Selim & Tosun**, **Gül & Yildirim Sibel**
Selçuk University Faculty of Dentistry
Pediatric Dentistry
Konya, Turkey

Purpose: Dental trauma refers to trauma to the face, mouth, and especially the teeth, lips and periodontium. The sequelae of dental trauma can be serious and can involve pulp necrosis, requiring root canal treatment or tooth extraction depending on time between trauma and dental/medical treatment. The aim of the study was to examine the records of traumatic injuries of permanent teeth, which were treated in our clinic (Dept. Pediatric Dentistry, Fac Dent, Selçuk Univ, Konya, Turkey) during the period from 2007 to 2013.

Methods & Materials: The examinations aimed to determine time elapsing after trauma and treatment choices. There were 102 patients aged between 6 to 12, including 41 girls (40.1%) and 54 boys (52.9%). The records showed that dental traumas in Konya area in the indicated time period were seen mostly in between 10-11 years-old children. While the most common observation was uncomplicated crown fractures (28,3%) and complicated crown fractures (19,1%), subluxation (11,3%), extrusion (9,2%), lateral luxation (9,2%), avulsion (6,3%), laceration (4,2%), intrusion (3,5%), complicated crown-root fracture (2,8%), uncomplicated crown-root fracture (2,1%), root fracture (2,1%), alveolar fracture (1,4%) were followed uncomplicated crown fractures with lesser degree of occurrences. The most common choice of the treatment of uncomplicated crown fractures was root canal treatment. Most of the patients (54.9%) were referred or applied to the clinic 25 hrs or more after the trauma. There were only 4 (3.9 %) patients were applied or referred to the clinic within 1 hr following trauma.

Results: Since the treatment of dental trauma is a state of art treatment covering the emergency and rehabilitation factors, the time between the incident occurrence and dental management is the most critical factor influencing the prognosis of the dental intervention. Accordingly, our data showed that the most common choice for the treatment of the uncomplicated crown fracture, which is the least complicated form of dental trauma, was mostly root canal treatment, since the parents were applied or referred to our clinic after a day or longer than the trauma.

Conclusion: The findings reveal that it is important to inform the parents about dental trauma and about its emergence affect the treatment outcome severely.

FACTORS ASSOCIATED TO SURVIVAL RATES IN REPLANTED PERMANENT INCISORS

Zaror, Carlos*, Diaz, Jaime; Nuñez, Javiera; Jans, Alejandra
Universidad De La Frontera
Paediatric Dentistry and Orthodontics
Temuco, La Araucania, Chile

Purpose: To assess the clinical outcome, factors associated and survival rates of replanted permanent teeth in children and adolescents

Methods & Materials: An retrospective study was conducted on 36 subjects aged 5 to 16 years of age with 43 avulsed and replanted permanent teeth attended at emergency dental service of Hernán Henríquez A. Hospital and dental clinics of Universidad de La Frontera, Temuco, southern Chile, between January 2004 and April 2012. The clinical and radiographic data such as, gender, age, cause of the tooth avulsion, number of compromised teeth, transport and storage medium, extra-oral time of avulsed teeth, apical maturity of the roots and type of pulp and periodontal healing were obtained from the clinical dental records. All replanted teeth included in the study were treated according to clinical guides of IADT. To determine the association between independent and dependent variables, analysis with Fisher Exact Test with significance level of 5% was performed. To estimate the survival rate in this sample a Kaplan-Meier analysis was carried out.

Results: The mean age of the patients at the time of replantation was 10.2 years \pm 2.3 S.D. Thirty-five percent was transported in dry and non physiological medium, 20.9% were stored into a glass of milk and the same percent were stored in saliva. The majority of replanted teeth remained an extra oral time > 30 minutes (76.7%). Functional periodontal healing was observed only in 11 out of 43 replanted teeth (25.6%). The replacement resorption was the most common complication and was observed in 53.5% (23/43), mainly in replantation after 90 minutes and/or in those transported by improper medium ($p < 0.001$). Fifteen teeth were lost (34.8%), 10 of them for replacement resorption (66.6%) and 5 inflammatory root resorption (33.4%). Only 2 replanted teeth with open apex developed pulp canal obliteration. 53.3% of missing teeth were treated with autologous transplants and 46.7% with cervical decoronation procedure. The survival rate of the replanted teeth was 65.1% (28/43), with a median follow-up period of 33.2 months (range 6 to 72 months).

Conclusion: The survival of replanted teeth is affected by the development of replacement resorption, especially in cases with extra-long time and non-hydrated storage media. The post reimplantation complications are commonly diagnosed within the first 12 months. It is necessary to educate the population about the emergency management of avulsion to perform the procedures appropriate to handling and immediate reimplantation.

COMPARISON OF VARIOUS STORAGE MEDIA FOR AVULSED TEETH; SYSTEMATIC REVIEW

Adnan, Samira*, Raza Farhan, Lone, Maham, Hussain, Mahvash
The Aga Khan University
Dental Section
Karachi, Pakistan

Keywords: Avulsed teeth, storage media, PDL cell viability

Purpose: There is a wide variety of substances in literature that have been researched for use as storage medium for avulsed teeth. The objective of this review is to assess literature regarding various storage media available for transport and storage of avulsed teeth. Viability of PDL cells in the storage medium is essential for successful re-implantation.

Methods & Materials: The literature regarding transport media for avulsed teeth was reviewed in PubMed/MEDLINE, CINAHL Plus (Ebscohost) and Cochrane Library, from 1970 till date. Only studies focusing on human permanent teeth and/or PDL cells were included. The protocol was registered with Prospero (Registration Number: CRD42013003558). A customized data extraction form was developed for data collection. Due to the wide variety of media mentioned in the literature, the various media were divided into 6 major groups according to their composition. Due to difference in methodology, the review was divided into two parts, with this section focusing only studies assessing PDL cell survival. SPSS version 19.0 was used to analyze the compiled data.

Results: A total of 55 articles were included. Out of these, 44 studies assessed PDL cells survival and 11 assessed clinical parameters. In the 44 studies selected for this part of the review, the most common method of PDL cell assessment was Trypan blue exclusion/ staining. Most common medium studied before year 2000 was milk and variants, after 2001 there were more studies on natural products other than milk. Natural products other than milk were considered as acceptable media in 78.57% of studies in which they were compared, followed by milk and saline

Conclusion: There is heterogeneity between studies, as most studies have assessed PDL viability as a marker for survival of teeth instead of actual clinical success. According to frequency of reported literature, natural products other than milk (like coconut water and Propolis) are considered the most acceptable storage media when compared with other media. However, due to ease of availability and practicality, use of milk as storage media is also acceptable

UNCOMPLICATED CROWN FRACTURE – RESTORATIONS FINITE ELEMENT ANALYSIS.

Dan-Cristian, Ionel*, Luca, Rodica 1; Boazu, Doina 2
University of Medicine and Pharmacy "Carol Davila" , Bucharest, Romania 1; "Dunarea De Jos"
University, Galati, Romania 2.
Pediatric Dentistry Department 1; Applied Mechanics Department 2
Galati, Romania, Romania

Keywords: Finite element analysis, dental trauma, von Mises stresses

Purpose: Posttraumatic upper incisors require long lasting morpho- functional restauration, done as quickly and as easily as possible. In this research the elastic properties of different restoration types used in case of uncomplicated crown fractures are evaluated.

Methods & Materials: Using mathematical modeling with 3D finite element(FE) analysis the elastic behavior of the mixed composite-fiberglass ribbon restorations are put to the test in the worst clinical situation: horizontal uncomplicated crown fracture located in the vicinity of the pulp of an upper central incisor(case 1). For the evaluation composite restorations without reinforcement(case 2) or reinforced with metal pins(case 3) or non –metallic carbon nanotubes(case 4) or quartz (case 5) posts were used. Specimens are similar to real tooth structure, and contacts between materials are considered perfect. The presence of periodontal ligament was taken into account at the base of the model. The evaluation criteria were: von Mises stresses and strains in dentin and displacement of the reconstructed area . 3D FE modeling was performed using the COSMOS/M software. For the modeling two types of FE were created: volume elements TETRA4R and SHELL3L . For the test there were used : - Clinical situation A: horizontal load(F = 550N) applied tangentially to the posterior edge of the restoration. - Clinical situation B: oblique load(F = 390N) at an angle of 45 degrees to the upper posterior surface of the restoration.

Results: In situation A the maximum displacement ranged from: 0.179mm(case 1) to 0.370mm(case 3,4), 0.371mm(case 5) and 0.373mm(case 2). Von Mises stresses and strains in dentin were: 1.9967×10^8 (case 2), 2.0296×10^8 (case 4) and 1.1045×10^8 (case 1). In situation B the maximum displacement ranged from: 0.101mm(case 1) to 0.210mm(case 3,4,5) and 0.213mm(case 2). Von Mises stresses and strains in dentin were: 1.265×10^8 (case 2), 1.2938×10^8 (case 4) and 7.182×10^7 (case 1).

Conclusion: The tests results revealed a concentration of stresses around the post areas both in the restoration and the dentin with the risk of fracture. The behavior of systems reinforced with fiberglass ribbon applied circumferentially to the elliptical contour of the tooth-restoration interface has a better prognosis than other types of restorations evaluated in this research .

MICROHARDNESS OF RESIN-COATED ENCAPSULATED HIGHLY VISCOUS GLASS IONOMER CEMENTS

Kanik, Özgür*, Türkün, L. Sebnem
Afyon Kocatepe University, Ege University
Departments of Restorative Dentistry
Afyonkarahisar and Izmir, Turkey

Keywords: Microhardness, encapsulated glass ionomer cements, resin coating

Purpose: To evaluate the effect of resin coating on the microhardness of encapsulated highly viscous glass ionomer cements (HVGICs).

Methods & Materials: A resin coating (EQUIA Coat, GC Europe, Belgium) and a varnish (GC Varnish, GC Europe) were used for coating sample surfaces. Three control groups [composite-resin (CR)(Gradia Direct Posterior, GC Europe), non-coated EQUIA Fil (EF)(EQUIA Fil, GC Europe), non-coated Riva Self Cure (NR)(Riva Self Cure, SDI, Bayswater, VIC, Australia)], two resin-coated groups [resin-coated EQUIA Fil (RE), resin-coated Riva Self Cure (RR)] and two varnished groups [varnished EQUIA Fil (VE), varnished Riva Self Cure (VR)] were used. A total of seven groups (n=10) were evaluated in three different time cycles (24 hours, 7 days and 30 days). Samples of 6mm diameter and 2mm height were prepared at 23°C in circle typed sliced glass moulds according to manufacturer's instructions and stored in artificial saliva (SAGF Medium) at 37°C. A colorant pigment (0.01% Rhodamine B isothiocyanate, Merck, Darmstadt, Germany) was added into the resin coating and the varnish for easy observation. A halogen light (Elipar Trilight, 3M ESPE, Seefeld, Germany) was used for polymerization of resin coating for 20 seconds. All samples were sandpapered with different sizes of grained papers (180, 600, 1000, 1200, 1500, 2000, 3000) by an electronical device (Mecapol P230, Presi, Grenoble, France) at the end of the storage periods. Coating materials were removed from sample surfaces definitely and the microhardness measurements were made directly on the glass ionomer's surfaces. Ultrasonic cleaning (Elmasonic S, Elma Ultrasonic, Singen, Germany) was performed on all samples for 10 minutes before the tests. A universal test device (Shimadzu Microhardness Testers HMV-2, Shimadzu Corporation, Kyoto, Japan) was used for Vickers microhardness tests at 50 gram force for 15 seconds applied to get a sharp image. The geometric projection of the pyramidal peak magnified for 40 times by a camera system with fluorescent light at 50 Hz frequency was used to obtain the microhardness values. Two measurements for each sample and 10 values per groups were used for statistical evaluations with One-way Anova, Tukey HDS test and T-test at significant degree of .05.

Results: Microhardness values of CR groups were not significantly different regarding periods. All HVGIC groups showed significantly higher microhardness values than CR groups at all measurement periods ($p < 0.05$). Higher microhardness values were evaluated for all encapsulated HVGIC groups with increasing storage periods. The comparison of non-coated control groups and resin-coated test groups at different time periods exhibited no significant difference ($p > 0.05$).

Conclusion: It was concluded that a resin coating application has no significant effect on the microhardness of the tested encapsulated HVGICs.

Thursday, June 19th

Session 9

Room: Malazgirt B (14:00-15:00)

CLINICAL EVALUATION OF COMPOSITE RESTORATIONS OF FRACTURED ANTERIOR TEETH

Koç Vural, Uzay*, Kiremitci, Arlin; Gökalp, Saadet
Hacettepe University
Restorative Dentistry
Ankara, Turkey

Keywords: clinical evaluation, crown fracture, composite restoration

Purpose: The aim of this study was to evaluate performance of composite resins on fractured crown in permanent anterior teeth restored with direct composite resin technique and to compare differences between baseline, six and twelve months.

Methods & Materials: Thirty-four patients attended Restorative Dentistry Clinic with fractured tooth that was enrolled to restore with a direct composite resin restoration. The patient informed consent was obtained. Fifty-one broken permanent incisors were restored with a submicron-hybride composite and respective adhesive system (Spectrum TPH, Prime&Bond NT Adhesive, Dentsply). Forty-seven teeth were restored without root canal treatment. Remained four root canal treated teeth were build up with fiber post. Prevalence of types of dental trauma was recorded. Two experienced clinicians other than the operator evaluated each restoration according to slightly modified USPHS criteria (van Dijken, 1986) for the following characteristics: anatomical form, marginal adaptation, color match, marginal discoloration, surface roughness and caries as well as the magnitude of fragment tooth part (Ellis Classification). By using SPSS 21.0 statistical package, Wilcoxon Signed Rank, Kruskal Wallis, Mann-Whitney-U and Siegel and Castellan tests were performed.

Results: Patients applied the clinic in the first month after the trauma occurred (23.5%), 2-12 months (26.5%) and more than 12 months (50%). Most frequent cause of trauma was due to different types of falls (62.7%) and most frequently affected teeth were maxillary incisors (98.0%). Fracture type was mostly Ellis II crown fracture (62.7%). In six months follow up, one patient lost one restoration and, at the end of 12 months one patient lost one and the other patient lost two. There were no statistically significant differences in terms of anatomic form, marginal adaptation, color match, marginal discoloration, surface roughness and caries, between six and twelve months. Teeth belongs to Ellis III class were tended to retention lost and distortion of anatomic form than Ellis I ($p=0.001$) according to the Siegel and Castellan test.

Conclusion: Most of the restorations were successful after 1-year follow-up according to the modified USPHS criteria. In this short term clinical evaluation, remaining tooth structure was conserved and good patient compliance was achieved. Factors such as esthetic and/or cost would be considerations to indicate direct composite restorations.

COMPARISON OF TOOTH SHADE MATCHING: VISUAL VS. DIGITAL CAMERA METHOD

Siddiqui, Saqib*, Khan, Farhan Raza
The Aga Khan University Hospital
Dentistry/Surgery
Karachi, 74800, Pakistan

Keywords: Tooth Shade, Digital Camera, Visual shade selection

Purpose: To compare the tooth shade matching ability of dental professionals using simple visual method versus digital camera assisted method

Methods & Materials: Sixteen tooth shade tabs from Vita Classic shade guide were taken. An Ultra compact digital camera was used to acquire the images at uniform settings. Three images of each tab were taken at a pre-set object-camera distance. This step generated 144 reference images. For establishing test tabs, we used six masked tabs (assessor blinded) and used the above mentioned procedure to acquire a set of 18 test images. The two set of images (reference & test) were imported in the Photoshop software. An area of body of each tab image was selected, averaged and color parameters (hue, chroma & value) were determined. Using CIE L c*h* formula, the color difference of each test tab with each reference image at given distance were determined. Participants were asked to match the tooth shade. The outcome was correct match versus incorrect match using the two methods. SPSS 19.0 was used for the data analysis

Results: Digital method yielded overall correct colour match in 66% and correct lightness match in 83% samples compared to visual method that yielded 40% and 58% correct match respectively. Dentists identified correct colour and lightness in 22% and 44% samples while dental assistants correctly identified 60% and 77% samples respectively

Conclusion: Digital colour matching was found to be superior to the visual method. Dental assistants exhibited better colour matching skills than the dentists

COMPARISON OF RESTORED PREMOLARS WITH UNCOMPLICATED AND COMPLICATED CUSP FRACTURES

Yanar, Esra*, Celik, Pelin; Carikcioglu, Burak; Simsek, Sera; Yilmaz, Yucel
Ataturk University
Pediatric Dentistry
Erzurum, Turkey

Purpose: The aim of this study was to compare the fracture resistance force, failures occurred under fracture resistance force test and microleakage of premolar teeth which have uncomplicated and complicated cusp fractures restored with reattachment, high viscosity flowable resin composite (HVC; GrandioSO Heavy Flow®, Voco), self treating pin (STP) and prefabricated fiber post (PFP; Rebilda®, Voco).

Methods & Materials: Extracted 80 human non-carious maxillary premolar teeth were used in this study. Uncomplicated cusp fractures (UCCF) and complicated cusp fractures (CCF) were occurred on the premolar teeth (n=70) and the first fracture values recorded. Fractured teeth were divided into seven groups (n=10). Group-1: control group; Group-2:UCCF+ reattachment; Group-3: UCCF+HVC; Group-4: UCCF+ STP+HVC; Group-5: CCF+ reattachment; Group-6: CCF+PPF+HVC; Group-7: CCF+HVC; Group-8: CCF+STP+HVC. The restored teeth were subjected to thermocycling procedures 500 times and soaked in the 0.5% basic-fuchsin dye for 24 hours. The restored teeth were re-fractured and fracture values were recorded. In addition, failures occurred under fracture resistance force (repairable/non-repairable) and the occurrences of microleakage (dye penetration presence/absence) were evaluated. The obtained data were statistically analyzed.

Results: The fracture resistance force of the virgin teeth was significantly bigger than of the restored premolar teeth with UCCF and CCF ($P < 0.05$). Results of Duncan post-hoc test showed that Group-6 had significantly lower mean value than the other groups ($P < 0.05$). In addition, the other groups were not significantly different from each other ($P > 0.05$). No significant difference was found both failures that occurred under fracture resistance force testing and microleakage scores ($P > 0.05$).

Conclusion: Within the limitations of this in vitro study, fragment reattachment can be used to treat cusp fractured premolar teeth. In addition, horizontal self- treating pin viscosity flowable resin composite may have an effect on increasing the fracture resistance force.

EFFECT OF NOVEL RESTORATIVES WITH RETENTIVE-SLOTS ON FRACTURE-RESISTANCE OF ENDODONTICALLY-TREATED-TEETH

Yasa, Bilal*, Arslan, Hakan, Yasa, Elif, Akcay, Merve, Hatirli, Huseyin
Izmir Katip Celebi University, Faculty of Dentistry
Department of Restorative Dentistry
Izmir, Turkey

Keywords: Fracture resistance, Retentive slot, Short fiber-reinforced composite

Purpose: Non-restorable cusp fracture was found to be a significant reason for extraction of endodontically treated teeth with a incidence of 17.8%. Therefore, the preservation of tooth structure and reinforcement are important to conserve the endodontically treated teeth against fracture. The aim of the present study was to evaluate the fracture resistance of endodontically treated teeth restored with composite resin, bulk fill flowable and short fiber-reinforced composites in the absence/presence of retention slots.

Methods & Materials: One-hundred-ten extracted non-carious human mandibular molars received endodontic treatment followed by mesio-occluso-distal (MOD) cavities with 3 ± 0.2 mm thicknesses of buccal and lingual walls. The gingival cavosurface margin was 1 mm coronal to the cement-enamel junction. After then, teeth were divided into two main groups according to the absence or presence of the retention slot ($n=55$). The dove-tail retention slots were prepared on the middle of the buccal and lingual cavity walls to create mechanical interlocking. Each group was further divided into four subgroups according to the type of the restorative materials (control (no restoration), composite resin (Filtek Z550), bulk fill flowable (Filtek Bulk Fill) and short fiber-reinforced composite (Ever-X Posterior)). Restored teeth were subjected to compressive load at a strain rate of 1 mm/min with a universal testing machine until a fracture occurred. The data were statistically analyzed using two-way analysis of variance and Tukey's test for multiple comparisons.

Results: The results showed that the fracture resistance was significantly affected by the presence of the retentive slots and the type of the composite restorative material ($P < 0.05$). Retentive slots did not significantly decrease the fracture resistance of the control group. On the contrary, restored teeth with retentive slots significantly increased the fracture resistance compared with restored teeth without retentive slots ($P < 0.05$). Short fiber-reinforced composite with retentive slot cavities had significantly higher fracture resistance values compared with the other test groups ($P < 0.05$).

Conclusion: The fracture values of teeth restored with various restorative materials in the absence/presence of retention slots were significantly different. Restored teeth with retention slots increased the fracture resistance. Short fiber-reinforced composite with retentive slot cavities exhibited the highest fracture resistance within the limitations of this in vitro study.

EFFECT OF BLOOD-CONTAMINATION ON BOND-STRENGTH OF ROOT-END-PLACED MTA/BIODENTINE AFTER ROOT-END-RESECTION

Akcay, Huseyin*, Arslan, Hakan; Akcay, Merve; Mese, Merve; Sahin N. Nur
Izmir Katip Celebi University
Oral and Maxillofacial Surgery
Izmir, Turkey

Keywords: blood, endodontic microsurgery, root end filling

Purpose: Surgical endodontics is usually indicated for the treatment of teeth with periapical lesions when orthograde root canal treatment fails. Mineral trioxide aggregate (MTA) has been recognized as a suitable root-end filling material in endodontic microsurgery. Recently, a new tricalcium silicate-based cement, Biodentine (Septodont, Saint Maur des Fossés, France), has been manufactured. The aim of the present study was to evaluate the bond strength of root-end placed MTA and newly introduced cement Biodentine in the absence/presence of blood contamination.

Methods & Materials: Forty-eight extracted single-rooted maxillary central incisors were used. Following root-end resection and apical preparation using ultrasonic retro-tips, the specimens were randomly divided into two groups according to the following root-end filling materials: MTA (Cerkamed Medical Company, Stalowa, Poland) or Biodentine. The specimens were then divided into two subgroups according to the storage condition (Absence/Presence of Blood) (n = 12). In blood contaminated group, the specimens were immediately stored in eppendorf tubes containing blood, and in non-blood contaminated group, were stored in eppendorf tubes containing sterile physiological saline. The specimens were stored at 37 °C and 100% humidity for 1 week. After obtaining 2±0.1 mm of thickness slices, a push-out test was performed at a crosshead speed of 0.5 mm/min. Each slice was visually examined under a stereomicroscope at 32× magnification to evaluate failure mode. Data obtained bond strength were analyzed using two-way analysis of variance considering two factors (presence of blood contamination and root-end filling material type) and Tukey post hoc tests for multiple comparisons. The failure mode data were analyzed using the chi-square test (P = .05).

Results: Two-way ANOVA revealed that the bond strength was significantly affected by the presence of blood contamination and root-end filling material type (P < 0.001). Biodentine had higher bond strength than MTA (P < .001). According to the chi-square test, there were no statistically significant differences between the groups (P = .394).

Conclusion: Biodentine had higher bond strength values compared to MTA, and the bond strength of MTA and Biodentine as root-end filling materials was negatively affected by the presence of blood.

THE EFFECTS OF MYRRH ON SUTURE MATERIAL STRENGTH

Alshehri, Mohammed*
College of Medicine and University Hospitals, King Saud University
Dental
Riyadh, Saudi Arabia

Purpose: Several suture materials are used oral surgical interventions Myrrh has been reported to be effective for treating various oral diseases. In this study, we tested the durability of selected suture materials when exposed to various concentrations of myrrh in media that simulated the fluids found in the oral cavity.

Methods & Materials: Vicryl (polyglactin 910), Mersilk™ and polytetrafluoroethylene suture materials were immersed for five days in four different experimental media: artificial saliva (the control), sterile water with 2% Commiphora myrrha, full concentration Commiphora myrrha oil, and Parodontax® mouthwash. The tensile strengths were measured at the end of each day using an Instron universal tensile testing machine. The Kruskal-Wallis nonparametric analysis of variance test was used to compare the mean retained tensile strengths of the suture materials. A P-value of <0.05 was regarded as statistically significant.

Results: A significant reduction in the tensile strength of the 2% myrrh-exposed Mersilk™ was observed on Day 5 of the experiment (p<0.05). All three suture materials experienced a significant reduction in strength after three days of exposure to 100% myrrh. Of the three suture materials, PTFE showed the least disintegration from exposure to the experimental media.

Conclusion: Mersilk™ was the weakest suture material after the myrrh exposure. There may be differences between the experimental conditions and actual clinical settings; therefore, caution should be exercised when interpreting the study results.

Thursday, June 19th

Session 10

Room: Malazgirt B (15:00-16:00)

EVALUATION OF THE ACCURACY OF TEMPLATE GUIDED IMPLANT PLACEMENT

Vasak, Christoph*, **Giannis, Kathrina**; **Strbac, Georg**; **Lettner, Stefan**; **Gahleitner, Andre**; **Zechner, Werner**
University Clinic of Dentistry Oral Surgery, Medical University of Vienna, Vienna, Austria
Department of Oral Surgery
Vienna, Vienna, Austria

Purpose: The study aims to evaluate the accuracy of the NobelGuide (Medicim/Nobel Biocare, Göteborg, Sweden) concept maximally reducing the influence of clinical and surgical parameters. Moreover, the study was to compare and validate two validation procedures versus a reference method.

Methods & Materials: Overall, 60 implants were placed in 10 artificial edentulous mandibles according to the NobelGuide protocol. For merging the pre- and postoperative DICOM data sets, three different fusion methods (Triple Scan Technique, NobelGuide Validation software, and AMIRA® software [VSG–Visualization Sciences Group, Burlington, MA, USA] as reference) were applied. Discrepancies between the virtual and the actual implant positions were measured.

Results: The mean deviations measured with AMIRA® were 0.49 mm (implant shoulder), 0.69 mm (implant apex), and 1.98° (implant axis). The Triple Scan Technique as well as the NobelGuide™ Validation software revealed similar deviations compared with the reference method. A significant correlation between angular and apical deviations was seen ($r = 0.53$; $p < .001$). A greater implant diameter was associated with greater deviations ($p = .03$).

Conclusion: The Triple Scan Technique as a system-independent validation procedure as well as the NobelGuide Validation software are in accordance with the AMIRA® software. The NobelGuide system showed similar or less spatial and angular deviations compared with others.

YORKSHIRE DENTISTS' EXPERIENCE OF AVULSED TEETH

Counihan, Kate*, **Day, Peter**
Leeds Dental Institute University of Leeds
Department of Paediatric Dentistry
Leeds, West Yorkshire, United Kingdom

Purpose: An avulsed permanent tooth is one of the few true emergency situations in dentistry. What happens immediately after the injury has a direct effect on the prognosis. This type of injury occurs infrequently, so it could be expected that few dentists will see or treat a child with an avulsed permanent tooth in their career. However, research regarding the provision of treatment for tooth avulsion injuries by general dental practitioners (GDPs) is limited. The aim of the study was thus to explore the experience of GDPs in Yorkshire in relation to the management of avulsed permanent incisors in children.

The objectives were to ascertain how many dentists in Yorkshire have replanted an avulsed tooth, and how many teeth they have replanted; if they provide follow-up care for these children; if they use clinical guidelines when treating children with avulsed permanent teeth; and if they have had any postgraduate training in dental trauma.

Methods & Materials: The study was designed as a self completion postal questionnaire of a random sample of one thousand dentists working in the Yorkshire region. The questionnaire was posted with a letter inviting participation and a stamped addressed envelope for returns. A second mailshot was posted to non-responders. Responses were entered onto an Excel spreadsheet and simple descriptive analysis was undertaken.

Results: Five hundred and ninety seven questionnaires were returned and suitable for analysis (response rate 59.7%). Thirty nine per cent of respondents had replanted an avulsed permanent tooth in a child. Of those that had replanted avulsed teeth, the majority had replanted one or two teeth. Almost 40% of all dentists surveyed currently have a child who has suffered an avulsion injury under their care. Seventy-one per cent of dentists have used clinical guidelines in their management of children with avulsed teeth, including the IADT guidelines. Almost 40% of primary care dentists in Yorkshire have engaged in postgraduate training in dental trauma.

Conclusion: Sixty one per cent of GDPs in the Yorkshire region have no or very limited experience of treating children with avulsed permanent teeth. A significant percentage of GDPs currently have children with avulsion injuries under their care. Many of the GDPs have used clinical guidelines when providing treatment for these children. Almost 40% of GDPs in Yorkshire have undertaken postgraduate training in dental trauma.

A RETROSPECTIVE STUDY OF TRAUMATIC DENTAL INJURIES IN MALATYA, TURKEY

Demir, Pinar*, Guler, Cigdem; Kizilci, Esra; Gorgen, Veli Alper; Gunes, Dilek; Keskin, Gul
Inonu University
Pediatric Dentistry
Malatya, Turkey

Keywords: Dental trauma, primary teeth, permanent teeth

Purpose: Traumatic dental injuries are among the problems commonly observed in the primary and permanent teeth. The aim of this study was to examine epidemiological and dental data from traumatic dental injuries to children during 4 year period (from January 2010 to January 2014) in Malatya, Turkey.

Methods & Materials: A total of 22.648 patients have been recorded in Inonu University Faculty of Dentistry Department of Pediatric Dentistry. Of these, 237 patient's records were for dental trauma. A total of 406 teeth of 237 dental traumatized children (84 girls and 153 boys) were examined. The data obtained from the records were including the patient's gender, age, the period elapsed between trauma, time of seeking dental care, source of trauma, injured primary and permanent teeth, types of trauma, soft tissue injuries and the treatment procedures.

Results: The total frequency of trauma in this study was calculated as 1.04% during a 4-year period. The males were found to have more traumatic injury than females ($p < 0.05$). Also, the permanent teeth were more vulnerable to dental trauma than the primary teeth ($p < 0.05$). The teeth mostly affected by the traumas were the maxillary central incisors in both primary (59%) and permanent (80%) teeth. The most frequent source of trauma in both genders and in both primary and permanent teeth were falls. The most common type of trauma in the primary teeth was intrusive luxation, while it was enamel-dentin crown fracture in the permanent ones. The most common method of treatment was extraction and follow up for the primary teeth, and only direct restoration for the permanent teeth without any endodontic treatment. Only 13 patients (5%) were referred to the clinic in same day injury event. 45% of the patients came to our department in 1-3 days after injury.

Conclusion: The patients, parents and teachers living in Malatya, Turkey should be informed about the dental trauma and necessity of early treatment of dental traumas.

THE APPLICATION PERIOD ACCORDING TO TYPE OF PRIMARY DENTITION TRAUMA

Gök, Begüm*, Ulu Guzel, K. Görkem ; Kirzioglu, Zuhul
Faculty of Dentistry, University of Adnan Menderes, Faculty of Dentistry,
University of Süleyman Demirel
Department of Pediatric Dentistry
Isparta, Turkey

Keywords: dental trauma, primary dentition, immediate treatment

Purpose: Trauma to the primary dentition is a common dental health problem in childhood, producing a substantial impact on children's quality of life. The prognosis of dental trauma cases varies depending on the time elapsed after the trauma before treatment started. The aim of this study was to investigate the epidemiological and dental data from traumatic injuries to primary teeth.

Methods & Materials: The records of 281 children were examined registered for traumatic primary teeth injuries at a pediatric dental clinic. The information about age, sex distributions, time, causes of the injury, the time elapsed between injury and treatment recorded on standardized questionnaire forms.

Results: The dental trauma records of patients with an average age of 3,3 years and the 1 and 3 year old age groups were the most affected to the dental injury. 177 boys (62.9%) and 104 girls (37.1%), were evaluated on standardized questionnaire forms. The period elapsed between trauma and time of seeking dental care ranged from the same day to over a year. The most patients [146 patients (51.9%)] were referred to the clinic within same day following the injury and the most referred reason in the patients was subluxation 39 (26.7%). In primary dentition, subluxation (26.7%) was observed in the highest percentage of injured teeth for all patients. The main cause of injury was falls (33.09%).

Conclusion: The immediate treatment after dental trauma is an important factor that affects the prognosis of traumatized teeth. It is important to inform the parents about dental trauma and the importance of bringing their children fast to a dentist in trauma cases.

TRAUMATIC DENTAL INJURIES TO THE TEETH IN CHILDREN WITH EPILEPSY

Gurbuz, Taskin*, Demirci, Tevfik and Coruh, Munevver
Ataturk University
Pediatric Dentistry
Erzurum, Turkey

Purpose: Dental intrusion and avulsion, crown fracture, luxation and mandibular fractures are important dentofacial complications in children with epilepsy-related traumas. The purpose of the present study was to describe the occurrence of dental injuries in children with epilepsy.

Methods & Materials: The study group consisted of 241 individuals (130 boys and 111 girls). Their age ranged between 5 and 16 years with a mean age of 10.6 years. The parents were asked to complete a questionnaire regarding their child's age, gender, medical history, and history of dental traumas. Clinical features (type of seizure and seizure frequency) of the patients were obtained from hospital records. The teeth were evaluated clinically for evidences of past injuries to the teeth, enamel defects in the permanent incisors. Statistical analyses were performed using Chi-square and Fisher exact tests.

Results: Generalized tonic-clonic seizures often cause minor oral injuries and traumatized anterior teeth. Traumatic anterior dental injury was found in 28.5% of children with epilepsy. Enamel or enamel/dentin fractures were the most frequent types of traumatic injury. The permanent maxillary central incisors were the most commonly affected teeth (60%). Traumatized anterior teeth were observed at an equal frequency in boys and girls ($P > 0.05$). Localized enamel defects were detected on the labial surface of 32 teeth in 18 children, probably due to luxation injuries to the primary incisors.

Conclusion: Mental retardation and epileptic status are important factors in an increase in the risk of dental injuries. Severe dental injuries rarely occur in children with seizures other than generalized tonic-clonic seizures. However, the risk of seizure-related injuries is substantial.

CONTRIBUTION OF RADIOGRAPHS TO PREVALENCE OF TRAUMA TO PRIMARY INCISORS

Holan, Gideon*
The Hebrew University – Hadassah School of Dental Medicine
Pediatric Dentistry
Jerusalem, Israel

Purpose: While the effect of bitewing radiographs on caries prevalence in clinical studies has been investigated and published, the similar effect of periapical radiographs of the maxillary primary incisors on the prevalence of traumatic dental injuries (TDI) has not received much attention in the dental literature. The purpose of this study is: To evaluate the influence of radiographic findings on the prevalence of TDI in maxillary primary incisors.

Methods & Materials: TDI prevalence was assessed from the records of 727 preschool children at their first visit at a private dental practice. Evidence of TDI was based on: Clinical signs: enamel fracture, crown fracture with dentin exposure (with or without pulp exposure), internal coronal discoloration and fistula, and Radiographic signs: root fracture, pulp canal obliteration, internal resorption, arrest of dentine apposition, external pathologic root resorption (=surface resorption, inflammatory resorption and atypical root resorption) and a periapical radiolucent lesion. The prevalence rate of TDI based on clinical-signs-only was compared to the rate based on radiographic signs only and on the combination of clinical and radiographic signs.

Results: Four-hundred thirty-six children (60%) presented clinical evidence of TDI. The prevalence of TDI was increased by 7% (51/727) due to 51 children who presented radiographic signs of TDI without clinical evidence of trauma. Two-hundred forty-three children (33%) presented clinical signs of TDI without radiographic evidence of trauma. However, 210 of them (86%) presented enamel fracture only. When these children were transferred from the list of traumatized to non-traumatized children, the percentage of children with radiographic-signs-only was 18%.

Conclusion: The prevalence of TDI based on both clinical and radiographic evidence is 7 to 18% higher than that based on clinical examination only.

Thursday, June 19th

Session 11

Room: Malazgirt B (16:30-17:30)

PREVALENCE OF PATHOLOGIC ROOT RESORPTION IN THE MAXILLARY PRIMARY INCISORS

Lee, Yeon Joo*, Park, Jae-Hong, Choi, Sung Chul
Khyung-Hee University Dental Hospital
Department of Pediatric Dentistry
Seoul, Hoegi-Dong, Dongdaemun-Gu, Korea (South)

Purpose: Pathologic root resorption in the primary incisors can be shown in the radiographic examination. This resorption could be caused by trauma, caries, supernumerary teeth and unknown reason. Root resorption is the loss of dental hard tissues as a result of clastic activities. It might occur as a physiologic or pathologic phenomenon. Root resorption in the primary dentition is a normal physiologic process except when the resorption occurs prematurely. The purpose of this study was to analyze the prevalence of pathologic root resorption in the primary incisors.

Methods & Materials: In this study, data from 1353 preschoolers aged 4 year to 5 years were used, out of a total of 7353 patients who attended the Department of Pediatric Dentistry, Kyung Hee Dental Hospital and carried out radiographic examination between September 2010 and August 2012. Pathologic root resorption was classified as: (1) trauma induced; (2) caries induced; (3) supernumerary teeth(SNT) induced; and (4) idiopathic reason.

Results: A total of 108(7.98%) patients with 172 resorpted maxillary primary incisors were showed pathologic root resorption in primary incisors. Trauma was the most common cause of root resorption (45.9%), followed by idiopathic reason (40.1%), caries (8.7%), SNT (5.2%) and so on. Concerning of root resorption pattern, most of teeth showed external root resorption and only 7 teeth showed internal root resorption.

Conclusion: In the limit of this study, traumatic dental injuries are the main cause of pathologic root resorption. Also most of the idiopathic root resorption was found while examining trauma and can infer that the resorption was induced by previous unknown trauma. As apparent from this study, there is a need for an educational program specifically directed at parents and guardian to inform them about the benefit of home care, outdoor activities and immediate dental treatment.

ONE YEAR FOLLOW UP TIME IS ENOUGH FOR CROWN FRACTURES

Saritekin, Aysegul*, Kirzioglu, Zuhul Gucyetmez, Burcu
Suleyman Demirel University, Faculty of Dentistry
Pediatric Dentistry
Isparta, Turkey

Purpose: International Association of Dental Traumatology (IADT) suggest follow-up period for crown fracture as one year. In this study, patients who were followed up over one year evaluated and aimed to examine for all cases whether time is sufficient or not.

Methods & Materials: In our study, we examined records of 126 patients was admitted our clinic with complaints of maxillary incisors trauma caused crown fracture. These teeth treated with proper restorations and followed at least one year. Patients invited to our clinic for clinical and radiological assessments again. Percussion, palpation, presence of abcess-fistula, color changes and occlusion were evaluated. With traumatised teeth vitality controls of other adjacent incisors teeth were also made. Baseline periapical radiographs and routine checks ones were compared.

Results: • Examined all patients of 17.5 % do not have subjective symptoms applied to our clinic again. These patients followed at intervals of 2-5 years and the age range is 11-17. • Considering follow-up period, 27,3% of followed 2-3 years, 27.3% of between 3-4 years and 45.4% of 4-5 years. Mean follow-up of time was 43.78 months \pm 11.5 months. • Patients trauma age range was 7-14. Patients whose mean of trauma age was 10.55 \pm 1.70, determined complications. The mean age of the patients not seen complication was 10.09 \pm 2.47. • 81.8% of the patients have crown fracture without pulpal involvement. • Compared with clinical examination and follow-up data, 50% of patients (vitality change, vitality loss and percussion palpation tests) showed positive response were determined. An average of 45.09 \pm 12.46 months periods vitality loss and changes were observed in a number of teeth. • Repeated radiological controls shows that, 90,9 % of patients had problems about resin restorations without pulpal involvement. • Without pulpal involvement and problems were seen about resin restorations of 54.5 %, fracture line were close to the pulp. • 45.5 % of complicated teeth had open apex. • Patients has no problems in repeated examination 9,1% of resin restorations were close to the pulp. 45.5% of had open apex.

Conclusion: Treated teeth with crown fractured, it is observed, vitality problems were observed average 4 year follow-up period. Therefore, it is think that, some cases of crown fractures to be followed for more than 1 year is beneficial. However, detected problem time after treatment, come up to late time of mixed dentition. Considering this age period, occlusion changes may be a factor affecting the prognosis or could be a coincidence.

RESTROSPECTIVE COMPARASION OF DENTO ALVEOLAR TRAUMAS IN A PEDODONTIC CLINIC

Sengul, Fatih*, Yilmaz, Yucel
Ataturk University
Pediatric Dentistry
Erzurum, Turkey

Purpose: The aim of this study was to compare the changes in the 'frequency of patients age, gender, teeth group (incisor, canine, molar), distribution by months, source of trauma, the time elapsed between injury and treatment, types of trauma, soft tissue injuries and treatment procedures' criteria in children with dento-alveolar traumas who applied to a pedodontics clinic in two time periods.

Methods & Materials: The data was obtained from 1 - 15 year old patients with dental trauma. The first data obtained between 2000-2006 with a total number of 1021 teeth of 653 patients trauma records (90 primary and 264 permanent in females; 188 primary and 479 permanent in males). The second data was obtained between 2010-2014 with a total number of 970 teeth of 576 patients' trauma records (81 primary and 264 permanent in females; 132 primary and 493 permanent in males). The criteria used for categorizing the data obtained from dental trauma records for the two time periods and analyzed using chi-squared test ($p < 0.05$).

Results: While the difference between primary and permanent teeth was significant, gender was insignificant in the evaluation of two time periods. There was statistically significant difference between both time periods for each criterion. Based on the age criterion the difference rises from the pre-school trauma distribution. In case of 'tooth group' criterion the traumas in incisors were statistically significant, while it was insignificant for canines and molars in each primary and permanent dentition for both time periods. In each primary and permanent dentition, there was statistically significant difference under both 'treatment procedures' and 'distribution by months' criteria. For 'source of trauma' criterion, there was statistically significant difference between male and female patients with permanent dentition, and females with primary dentition, but not in males with primary dentition. In 'the time elapsed between injury and treatment' criterion for the second time period within the first month following trauma, the time elapsed between trauma and treatment was significantly shortened.

Conclusion: Within the limits of the present study, in dental traumatized children the time for seeking dental care was shortened, they understood the necessity of early treatment, nevertheless, there was no difference between sexes, and in both dentitions, incisors were highly exposed to trauma. In spite of being well informed about seeking for treatment of traumas by the time, there was not sufficient improvement in prevention of dento-alveolar traumas.

SOFT TISSUE TRAUMAS ACCOMPANIED WITH DENTO-ALVEOLAR TRAUMA

Simsek, Huseyin*, Sengul, Fatih, Dursun, Pelin, Yilmaz, Yucel
Ataturk University
Pediatric Dentistry
Erzurum, Turkey

Purpose: The aim of this study was to present the distribution of 'age, gender, classification of traumatic dental injuries, types of soft tissue trauma, teeth and jaws affected by trauma, the time elapsed between injury and treatment' criteria in dental traumatized children with soft tissue traumas who applied to a pedodontic clinic.

Methods & Materials: The data were obtained from the 1 - 15 year old patients (286 children) who were admitted to a pedodontic clinic within the first week due to trauma during 2010-2014. The criteria used for categorizing the data obtained from dental trauma records were 'age, gender, classification of traumatic dental injuries according to Andreasen & Andreasen, types of soft tissue trauma (abrasion, contusion, laceration), teeth (primary, permanent) and jaws (maxillary, mandibular) affected by trauma, the time elapsed between injury and treatment (1 day, 1-3 days, 4-7 days)'. The obtained data were analyzed using chi-squared test ($p < 0.05$).

Results: Soft tissue trauma were noted in 90 of 268 patients (87 had both dental hard and soft tissue traumas, only 3 had soft tissue trauma). There was no statistically significant difference between patients with and without soft tissue traumas for criteria of 'age, gender, teeth and jaws affected by trauma, and the time elapsed between injury and treatment.' In 'classification of traumatic dental injuries' criterion, difference arose from injuries to the periodontal tissues subgroup. 'Types of soft tissue trauma' criterion ratios were 12.2% abrasion, 18.9% contusion, and 68.9% laceration.

Conclusion: Within the limits of this study, extensively soft tissue traumas were noted with hard tissue trauma. However, patients' application for only soft tissue trauma was in a low rate. Therefore, it was concluded that the patients, parents and teachers should be informed about this issue.

PREVALENCE OF MAXILLARY INCISORS ROOT RESORPTION CAUSED BY IMPACTED CANINES

Strbac, Georg*, Giannis Katharina, Gahleitner Andre, Bantleon Hans-Peter, Bernhart Thomas
Bernhard Gottlieb University Clinic of Dentistry, Medical University of Vienna, Austria
Department of Oral Surgery
Vienna, Vienna, Austria

Purpose: The aim of this study was to evaluate the prevalence of root resorption of maxillary incisors caused by impacted maxillary canines using low-dose dental computed tomography and to gain additional knowledge of the underlying aetiology and the progression of root resorption.

Methods & Materials: A total of 440 patients (mean age, 24.7 years) with 557 impacted maxillary canines were examined regarding their location and the occurrence of root resorption of maxillary incisors.

Results: The frequency of root resorption was 2 % of central and 7.7 % of lateral maxillary incisors. The location of the 557 impacted canines within the dental arch was palatal in 67.5 %, buccal in 15.4 % and central in 17.1 %. No significant differences could be shown with respect to the width and the shape of the dental follicle of the impacted maxillary canines and the presence of root resorption of incisors. The presence of root resorption of central ($p < 0.0001$) and lateral ($p < 0.023$) maxillary incisors was significantly correlated with an existing contact relationship of the impacted maxillary canines.

Conclusion: Our investigation confirms the theory of prior reports comprising a much larger patient population, hypothesising that the dental follicle of impacted maxillary canines does not cause resorption of adjacent maxillary incisors per se. Root resorption of maxillary incisors is correlated with effects of contact of the impacted maxillary canines, and these findings should be considered in treatment planning. Our findings are consistent with other reports and may develop new treatment approaches for the treatment of this sequela.

DETERMINING IOTN IN PATIENTS REPORTING TO AFID, RWP, PAKISTAN

Tabassum, Sadia*, Khalid, Zahra , Wahid Asma, Mushtaq Razia
Aga Khan Unviersity Hospital
Operative Dentistry
Karachi, Pakistan

Keywords: IOTN, DHC, malocclusion

Purpose: To determine the IOTN of patients reporting to Orthodontics dept. AFID during the last 6 months (Oct 2011-Mar 2012), estimate the treatment need and compare the findings with those of other populations.

Methods & Materials: IOTN of 159 patients was recorded using only the Dental Health component (DHC) of IOTN on the initial study casts of the patients. The Esthetic Component of IOTN which describes the patient's perceived need of treatment was not calculated. Data was analyzed through SPSS 17, age dependency and gender distribution of different malocclusion grades were also calculated. It was a simple descriptive study and sample taken were consecutive reporting cases.

Results: Our results showed that out of $n=159$ patients, 20.1% had extreme need for treatment. The percentage of patients requiring severe need for treatment was 51.6%. 22% patients showed moderate/borderline treatment need. Only 5.04% fell in mild or little need and about 1.26% needed no treatment at all. The frequency of female patients was more than males and the mean age of the patients was 13.5 years. Our result was comparable to specialist practice in Eastern Nepal where also most patients reported with severe need of orthodontic treatment.

Conclusion: AFID is a tertiary care center providing specialist orthodontic care to the patients. Most reporting patients fell into the category of severe treatment need i.e. the grade 4. Young patients especially females are more conscious of their malocclusion.

Thursday, June 19th

Session 12

Room: Malazgirt B (17:30-19:00)

REINFORCEMENT OF IMMATURE-TEETH WITH A NOVEL SILICATE-BASED-SEALER AND POST SYSTEM

Unverdi Eldeniz, Ayce*, Akbulut, Makbule Bilge

University of Selcuk

Endodontics

Konya, Turkey

Purpose: The purpose of this in vitro study was to compare the fracture resistance of immature teeth filled either with IBC BioAggregate (Vancouver, Canada) or Biodentine (Septodont, France) apical plugs and restored with either iRoot SP (Vancouver, Canada) or a novel BioRoot RCS (Septodont, France) sealer with laterally condensed gutta percha, or i-TFC post system (Sun Medical, Japan).

Methods & Materials: Sixty single rooted maxillary anterior teeth were divided into 6 groups. The crowns were removed and root canals were enlarged with #6 Peeso reamers until it protruded 1 mm beyond the apex to simulate immature teeth. Teeth were then divided into two main groups (n=30) and apical 4 mm of each tooth was filled either using IBC BioAggregate or Biodentine. The remaining portions of canals were obturated as follows: Group 1: No backfilling after IBC BioAggregate apical plug (n=6, control), Group 2: Backfilled with iRootSP and gutta percha, Group 3: Filled with i-TFC post system, Group 4: No backfilling after Biodentine apical plug (n=6, control), Group 5: Backfilled with BioRoot RCS and gutta percha, Group 6: Filled with i-TFC post system. All experimental groups contained 12 teeth except controls. The specimens were embedded into self-curing acrylic poured into cylindrical molds and were mounted on a jig providing a 45° angle. A compressive load increasing at 1 mm min⁻¹ was applied and the maximum load at which fracture occurred was recorded in Newtons. Statistical analysis was performed using Kruskal-Wallis and Mann-Whitney U test.

Results: The mean fracture resistance values and standard deviations obtained for each group were as follows; Group 1:1370±377N, Group 2: 1332±151N, Group 3: 997±218N and Group 4: 1274±209 N, Group 5:1332±119N, Group 6:1188±354N with no significant difference between them (p>0.05). Although it is not statistically significant, IBC BioAggregate apical plug group that was restored with i-TFC post yielded the lowest values (p>0.05).

Conclusion: Biodentine apical plug backfilled with BioRoot RCS/gutta percha fillings were equally effective in reinforcing immature teeth as IBC BioAggregate apical plug backfilled with iRootSP/gutta percha fillings. New i-TFC post system could not improve fracture resistance of immature teeth when cemented with its resin cement.

IMPORTANCE OF THE TYPE AND TIME OF PRIMARY TEETH LUXATIONS

Yetis, Ceylan Çagil*, Kirzioglu, Zuhul. Önoel, Seda.
University of Suleyman Demirel Faculty of Dentistry
Paediatric Dentistry
Isparta, Turkey

Keywords: Primary tooth, tooth injury, sequelae

Purpose: The aim of our study is to evaluate the effects of the luxation injuries of the primary teeth on their permanent succedaneous and their relationship with the time of trauma, the type of luxation and gender.

Methods & Materials: In our study, records of the all patients who were admitted to our clinic because of primary teeth trauma were reviewed. Among these patients, 37 children who exposed to trauma 4-10 years ago so that we could see potential trauma sequelae on their permanent teeth and who were regularly monitored, contact details found and invited to our clinic constituted our study group. Patients in the study group were examined clinically and radiographically to see if any sequelae had occurred in their permanent teeth. The obtained data were evaluated in terms of the age of trauma exposure, the root resorption level of deciduous teeth, the type of luxation injuries, the sequel formation and gender.

Results: As a result of the examinations, evaluated patients were divided into two group including 0-3 and 3-6 age groups in terms of the age of trauma. Considering the types of trauma that occurred, especially in the 0-3 age group, the most common type of traumatic injury were found to be intrusion (59%). While sequel formation was observed in 88% of the patients in 0-3 age group, only 20% of patients with sequelae of trauma was seen in the 3-6 age group. In addition, as a result of the intrusion injuries which were found the most common type of luxation, in 0-3 years olds we had seen trauma sequel in 90% of the patients, whereas the same rate was found to be 20% in the age group 3-6. In 78% of patients with sequelae of trauma it was observed that primary teeth root resorption didn't started, yet. In older age, with the increasing level of the root resorption of the primary teeth, less sequel was observed to occur as a result of intrusion injuries.

Conclusion: As a consequence, the most common type of trauma sequel was found enamel staining-hypoplasia and crown-root dilaceration was following it. Sequel formation was observed in 51% of the patients in our study group and this ratio reveals the importance of primary teeth trauma.

WEARABILITY-VARIABLE PHYSIOLOGICAL EFFECTS OF MOUTHGUARDS ON THE PERFORMANCE OF BASKETBALL-PLAYERS

Dogan, Özgür*, Sönmez Hayriye
Ankara University
Pediatric Dentistry
Ankara, Turkey

Keywords: mouthguard, custom-made, boil-bite

Purpose: The purpose of this study was evaluate the satisfaction of professional basketball players with custom made and boil-bite mouthguards in a period of 3 months.

Methods & Materials: A total of 48 male players aged between 15 and 17 years were randomly distributed into 3 groups. In Group 1 (n:16) boil-bite mouthguard, In group 2 (n:13) 3mm custom made mouthguard, In group 3 (n:19) 5mm custom made mouthguard was used. Using Visual Analog Scale (VAS) questionnaire, comfort, fitting, stability, tiredness, oral dryness, nausea, speaking, breathing, drinking, ease to wear-remove and inclination to chew were evaluated. The evaluations were repeated three times as at the end of 1 week, 1 month and 3 month period. Each player expressed his satisfaction with the mouthguard by drawing a line on a 10 cm long scale for each parameter. Kruskal Wallis H test was used for statistical analyses using SPSS 20.0 WINDOWS program to determine statistical significance. The value of $p < 0.05$ was regarded as significance.

Results: The mean VAS value about "stability" obtained from boil-bite group (5.38) was statistically lower than custom made groups (8.06-8.01; respectively for Group 2 and Group 3) ($p < 0.05$). The mean VAS value about "speaking" obtained from boil-bite group (2.81) was statistically lower than other groups (4.77-5.37; respectively for Group 2 and Group 3) ($p < 0.05$). The mean VAS value about "drinking" obtained from boil-bite group (4.67) was statistically lower than other groups (7.34-6.92; respectively for Group 2 and Group 3) ($p < 0.05$). There were no significant differences between groups 2 and 3 ($p > 0.05$).

Conclusion: This study showed that the custom made mouthguards were much more accepted than boil-bite mouthguard by professional basketball players.

PREVALENCE AND PREVENTION OF DENTAL INJURIES IN YOUNG TAEKWONDO ATHLETES

Gorseta, Kristina*, Vidovic, Dina; Skrinjaric, Tomislav; Glavina, Domagoj; Skrinjaric, Ilija
University of Zagreb, School of Dental Medicine
Department of Paediatric and Preventive Dentistry
Zagreb, Croatia, Croatia (Hrvatska)

Purpose: Taekwondo players are at a high risk of sustaining dental injury and the awareness and use of mouthguards are important for trauma prevention. The aim of this study was to assess the prevalence of dental and facial injuries among young athletes, the habit of wearing mouthguards, and the level of awareness regarding injury prevention and first aid after tooth avulsion.

Methods & Materials: This study comprised 484 taekwondo players taking part in the survey [271 male (56%) and 213 female (44%)] aged between 8 and 28 years. The mean age of athletes was 15(\pm 3.7) years. The questionnaire submitted to the players contained 15 items about dental trauma and use of mouthguard for dental trauma prevention. The level of awareness about tooth avulsion and replantation was also assessed. Collected data were evaluated according to gender, age groups (younger cadets 8-11 years; cadets 12-14 years; juniors 15-17 years; seniors 18-28 years), and how many years are they actively engage in taekwondo (<3 years; >3 years). Descriptive statistics and Chi-square tests were used for the comparisons between the groups.

Results: Of 484 athletes, 300 subjects (62%) had sustained at least one serious injury and 103 subjects (21%) had sustained an orofacial injury, while 193 athletes (40%) had observed another player sustaining a dental injury. One or more dental injuries experienced 98 (20%) athletes. Dental injury with jaw fracture was recorded in 5 (1%) subjects. Higher number of orofacial injuries was observed in males (24%) than in females (18%). The athletes in senior group (age over 18 years) showed a higher number of tooth injuries (42%) than in other younger groups. The number of injuries increased with age and with years of engagement in sport ($p < 0.05$). Mouthguard wearing was recorded in 465 athletes (96%), but only 5.3% were custom-made mouthguards. Most of them (96%) consider that mouthguards are useful for injury prevention in taekwondo. Awareness of possibility of replanting avulsed tooth was recorded in 211 (44%) of athletes, and only 80 of them (16%) were informed about tooth rescue boxes.

Conclusion: The obtained results show that general injuries frequently occur in taekwondo in all age groups but most frequently in senior group. Dental injuries in senior group were significantly higher than in younger age groups of athletes. This survey highlights that dentist could play important role in the education of athletes advocating wearing of custom-made mouthguards.

THE INCIDENCE OF DENTAL TRAUMA IN TURKISH MUAY THAI PLAYERS

Karayilmaz, Hüseyin*, Erken Güngör, Özge
Akdeniz University, Faculty of Dentistry
Department of Pediatric Dentistry
Antalya, Turkey

Keywords: Dental Trauma, Muay Thai, mouthguard

Purpose: Muay Thai, is one of the combat sport which occurs in Thailand approximately three hundred years ago. Due to the increasing popularity it has one million participants worldwide. This sport has been started at the beginning of millennium in our country. The rules of this sport allows use of kicks, punches, elbows and knees like the other combat sports. These sports that require close contact such as Muay Thai, can be caused serious injuries. Especially hematomas, soft tissue trauma and laceration have been shown and the head and face injuries have been seen %50 percent of all of them. The aim of this pilot study is to describe the frequency of oral and dental injury of players and their awareness about the need for intervention of traumatic dental injuries sustained in sports and the habit of wearing a mouthguard.

Methods & Materials: A population of Akdeniz University Muay Thai group, composed 26 males and 2 female, total 28 players were included in this research. Oral examination of participants was made in the training area with portable light source. A questionnaire was filled survey for each players. This questionnaire contained 15 questions about history of general and dental trauma, using of mouthguards. Injured soft tissue and teeth were determined.

Results: A total of 28 Muay Thai players were examined. The age of these players ranged from 11 to 35 years, with an average age of 19,5 \pm 5.3 years. General trauma like lacerations, contusions and hematoma formation was occurred 20 players of 28 (71.42 %). Dental injuries were seen 18 of players (64.28 %). It was determined that the most common type of dental trauma were enamel cracked and fractures. More serious tooth injuries such as complicated crown fractures and avulsions were not seen. The fabricated mouthguard were used by all of the players except for two players.

Conclusion: Serious dental injuries were not seen because a large part of players (93%) used mouthguards. Other close combat sports such as kick box, judo, taekwondo etc. players and coaches should be instructed about importance of oral and dental injury and their awareness about requirement of immediate dental treatment for injured teeth and usage of mouthguards should be increased.

TEMPOROMANDIBULAR DISORDERS IN BOXING ATHLETES

Montero Parrilla, José Miguel*, Pichardo Pérez, Jorge Ernesto. Grau León, Ileana. Valdés Reyes, José Manuel.

Faculty of Dentistry

Prosthodontics

Havana, Cuba

Purpose: Boxing is a combat sport and amateur boxers have the potential to suffer significant traumatic injuries in the Temporomandibular Joint. Sports Dentistry is one of the most recent and upcoming field in dentistry, and has the responsibility of offering all boxers a comprehensive care. The purpose of this study was to identify the presence of Temporomandibular Disorders in boxing athletes.

Methods & Materials: An observational-descriptive, cross-sectional study was accomplished in 30 athletes of the Boxing Cuban High Performance School "Manuel Permuiz", in the period understood from March to July of 2013. To identify de clinic signs and symptoms of Temporomandibular Disorders the Krogh-Paulsen Test was employed.

Results: Joint sounds (30%) and sideslip during occlusion (26.6%) were the most common signs and symptoms identified. Boxers that had been practicing the sport during 6 to 10 years had bigger affectations. All of them used mouthguard during both competitions and practices, but only two had a custom-made mouthguard. 56.6% of the boxers were diagnosed with dysfunction according to the Krogh-Paulsen Test. Both morphologic and functional occlusal alterations predominated in boxers with dysfunction.

Conclusion: Temporomandibular Disorders were very frequent in boxers. Morphologic and functional alterations of the occlusion were common in this group of athletes. The provision of custom-made mouthguard should be actively encouraged by dental care workers.

TOOTH MOUSSE AND OTHER(CPP-ACP)COMPLEX EFFECTS ON CHILDREN'S CARIOGENIC MICROFLORA

Moussa, Shady*, El-Bauomy, Samy*

Zagazig University

Zagazig City, Sharkia, Egypt

Purpose: Study was designed in dental department of Zagazig University hospital to detect the effect of Casein-Phosphopeptide with Amorphous Calcium Phosphate complex (CPP-ACP) containing paste(Tooth Mousse)and Casein-Phosphopeptide with Amorphous Calcium Phosphate complex with fluoride(MI paste)on cariogenic microflora system in children.

Methods & Materials: 120 children less than 15 years old who had the same oral hygiene habits, evaluated by oral hygiene index, participated in this study. They were divided into Control group(I) which included 20 children who did not use CCP-ACP complexes and Study group(II) which included 100 children that were divided into Subgroup(A): 50 children who used Tooth Mousse and Subgroup(B): 50 children who used MI paste. They used CCP-ACP complexes as a topical application on teeth once daily for 60 seconds. All children did not use any antibiotic therapy in the last week before the sample collection. Salivation of each child was stimulated by chewing a paraffin pellet for 5 minutes to collect 3ml of saliva that was divided into three equal parts. pH of saliva was measured by pH meter using first part of collected saliva. Other parts of collected saliva were used for measuring the Streptococcus mutans and lactobacilli count in saliva by means of selective culture media(mitis-salivarirs agar and tomato agar). Colony counting was done with a magnifying glass (cfu/ml) of saliva. All tests would be repeated and examined after 7,14,30 and 45 days of material using. All collected data were statistical analysis by ANOVA test, $p < 0.05$ using the SPSS 22 programme.

Results: The salivary pH of the study subgroups using CPP-ACP complexes were significantly higher than the control group $P < 0.05$. Streptococcus-mutans and Lactobacillus-acidophilus counts in both study subgroups that used CPP-ACP complexes were significantly lower than the control group, also while comparing subgroup A with subgroup B there was a significant decrease of bacterial counts in subgroup B that used (MI paste) more than subgroup A that used (tooth mousse) $P < 0.05$.

Conclusion: Using CPP-ACP complexes increased salivary pH, which inhibited and decreased the growth of Streptococcus-mutans and Lactobacillus-acidophilus. CPP-ACP containing fluoride is more beneficial than using CPP-ACP alone which attributed to inhibiting bacterial metabolism by fluoride effect.

KNOWLEDGE OF COACHES ABOUT ORO-FACIAL INJURIES AND MOUTHGUARD USAGE

Ozel, Emre*, Tuna-Ince, Elif Bahar; Ozgur, Turgay; Ozgur, Bahar
University of Kocaeli, Faculty of Dentistry
Department of Restorative Dentistry
Kocaeli, Turkey

Purpose: The purpose of this study was to assess the opinion and experience of contact sports' coaches about dental and oro-facial trauma and mouthguard usage in elite athletes.

Methods & Materials: An epidemiological survey was carried out through interviews with 60 trainers in 31 clubs competing in Turkey National League. Information was obtained between August-October 2013 from personal interviews and questionnaires answered by coaches. Eight questions were asked to coaches. The questionnaire included questions about dental injuries, particularly personal experience, and awareness of first aid, knowledge and use of mouthguards. The statistical evaluation was performed using Chi-square test at a significance level of 0.05.

Results: 69.5% of the coaches had experience of oro-facial injuries during contact sports activities and 84.7% of the coaches mentioned that the athletes in the team used mouthguards during contact sport activities. With a high percentage of 98.3%, coaches pointed out that they believed that mouthguards protect oro-facial tissues from different kind of traumas during practice. Most of the coaches (83.1%) stated that they would like to have more information about the mouthguard types and usage. There was a correlation between the number of coaches mentioning the necessity of mouthguard use, and the number of the athletes in their teams wearing a mouthguard during practices ($p < 0.05$).

Conclusion: The results of the study showed that coaches agreed on the protective effectiveness of mouthguard against contact sport-related oro-facial injuries, but they are yet to be adequately informed about mouthguards. It is necessary to inform coaches about dental injuries and to promote the mouthguard usage by educational programs, especially in contact sports activities.

EVALUATION OF DENTAL TRAUMA AND MOUTHGUARD USAGE IN CONTACT SPORTS

Tuna-Ince, Elif Bahar*, Ozel, Emre; Ozgur, Turgay; Ozgur, Bahar
Istanbul University Faculty of Dentistry
Department of Pediatric Dentistry
Istanbul, Turkey

Purpose: The purpose of this study was to evaluate the awareness of sports as a risk factor of dental injuries, the emergency management when a tooth avulsion occurs and the compliance about mouthguards in contact sport participants.

Methods & Materials: An epidemiological survey was carried out through interviews with 138 (105 male and 33 female) elite athletes at the age of 14 to 30-years participating in 11 different contact sports and competing in Turkish National League. Information was obtained between August-October 2013 from personal interviews and questionnaires answered by elite athletes. The questionnaire was structured into three parts: 1) questions about age, sex, type of sport participating and training age; 2) questions about dental injuries, particularly personal experience, awareness of first aid and procedure about tooth avulsion; 3) questions about knowledge and use of mouthguards. The statistical evaluation was performed using Chi-square test at a significance level of 0.05.

Results: 42.0% of the athletes were aware of the possibility of oral injuries during contact sports and 22.5% referred an experience of dental trauma. 70.3% of the athletes mentioned that they use mouthguard during contact sports, and 32.3% had oro-facial trauma when wearing mouthguard and 61.3% referred to dentist as first choice following medical doctor (12.9%) and emergency service (25.8%). There is a higher incidence of dental and oro-facial trauma in male than female ($p < 0.05$). Finally, 11.6% know that the avulsed tooth may be reimplanted: 51.4% would reimplant the tooth within an hour and only 35.5% would keep it in a wet storage medium.

Conclusion: The results of the study showed limited knowledge about dental injury, its prevention and limited use of mouthguards. It is necessary to inform coaches, gym teachers, athletes and parents about dental injuries and to promote the usage of the mouthguards by educational programs, especially in contact sports.



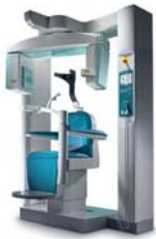



Thinking ahead. Focused on life.



Smallest structures deserve our best resolution



High precision X-ray technology for excellent diagnostics

As the favored CBCT system for dentists and maxillofacial surgeons, the 3D Accuitomo 170 offers you maximum imaging quality and highest possible flexibility in 9 different fields of view (FOV). The resolution of more than 2 lp/mm and voxel size of 80 μm provides you with a detailed insight into all clinical indications within the area of the head. You profit from high-precision images – for a reliable diagnosis and optimum treatment. Request further information about our 3D Accuitomo 170 from info@morita.de

Clinical Cases
for Implant Dentistry by
Prof. Dr. Buser and
Prof. Dr. Bornstein.
Complete Clinical Cases
brochure available
at Morita booth.

